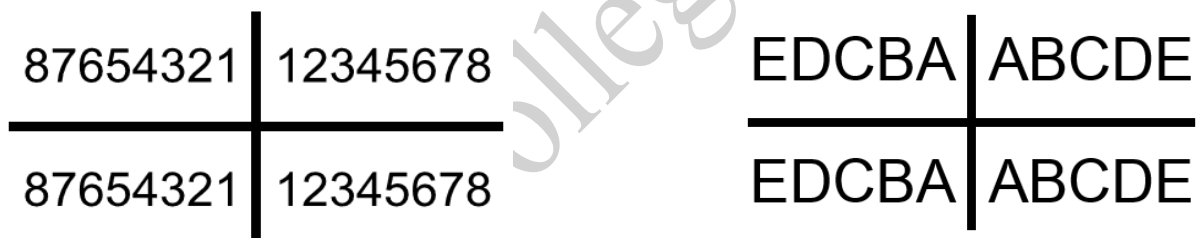


## Tooth numbering system

### 1. Zsigmondy- palmer system

The Hungarian dentist Adolf Zsigmondy discovered this system in 1861, using a Zsigmondy cross to record quadrants of tooth positions. Adult teeth were numbered 1 to 8, and the child primary dentition (also called deciduous, milk or baby teeth) were depicted with a quadrant grid using Roman numerals I, II, III, IV, V to number the teeth from the midline. Palmer changed this to A, B, C, D, E. This makes it less confusing and less prone to errors in interpretation.

The Palmer notation consists of a symbol ( $\begin{matrix} \lrcorner & \llcorner \\ \ulcorner & \lrcorner \end{matrix}$ ) designating in which quadrant the tooth is found and a number indicating the position from the midline. Adult teeth are numbered 1 to 8, with deciduous (baby) teeth indicated by a letter A to E. Hence the left and right maxillary central incisor would have the same number, "1", but the right one would have the symbol, " $\lrcorner$ ", underneath it, while the left one would have, " $\llcorner$ ".



#### Advantages:

- 1) Easy to implement.
- 2) Easy of writing and communication.
- 3) Less mistakes in identifying the designated tooth.

#### Disadvantages:

- 1) Cannot be written by the computer.
- 2) Non-numeric symbolization.

### 2. Universal numbering system

This tooth numbering system was proposed by German dentist Julius Parredidt in 1882. Although it is named the "universal numbering system", it is also called the "American system" as it is commonly used in the United States.

The uppercase letters A through T are used for primary teeth and the numbers 1

- 32 are used for permanent teeth. The tooth designated "1" is the maxillary right third molar ("wisdom tooth") and the count continues along the upper teeth to the left side. Then the count begins at the mandibular left third molar, designated number 17, and continues along the bottom teeth to the right side. Each tooth has a unique number or letter, allowing for easier use on keyboards. As specific numbers are employed for each tooth, it reduces the risk of mistake. Data can also be easily entered in the computer.

#### Advantages –

1. Individual number for each tooth.
2. Simple

#### Disadvantages:

1. Difficult in remembering the tooth no.
2. Matching the specific teeth and quadrants can be confusing.
3. There is no anatomic reference in this system and so it is difficult to follow for the beginners, and needs extra training to practice.

Permanent Teeth															
Upper Right								Upper Left							
1	2	3	4	5	6	7	8	9	10	11	12	13	14	15	16
32	31	30	29	28	27	26	25	24	23	22	21	20	19	18	17
Lower Right								Lower Left							

Primary teeth									
Upper Right					Upper Left				
A	B	C	D	E	F	G	H	I	J
T	S	R	Q	P	O	N	M	L	K
Lower Right					Lower Left				

### 3. International numbering system

The Federation Dentaire Internationale (FDI) system is a two-digit system, the first digit indicates the quadrant (1 through 4 for permanent and 5 through 8 for deciduous teeth) and the second digit indicates the tooth type (1 through 8 or 1 through 5). It is very simple, accurate, it is easy to memorise in the visual and cognitive sense, it is user friendly, and prevents errors in differentiating left and right, upper and lower arches, and tooth type. However, in the case of deciduous teeth, there can be confusion and it is difficult to memorize. For specialists other than

**Lec.2**

**Pedodontics**

**Forth stage**

paedodontists, it can be difficult to understand or to define teeth, as in the case for example of 64, 85.

Upper Right					Upper Left				
55	54	53	52	51	61	62	63	64	65
85	84	83	82	81	71	72	73	74	75
Lower Right					Lower Left				

Upper Right											Upper Left						
18	17	16	15	14	13	12	11	21	22	23	24	25	26	27	28		
48	47	46	45	44	43	42	41	31	32	33	34	35	36	37	38		
Lower Right											Lower Left						

**For primary teeth**

**For permanent teeth**

\*\*This system makes the visual, cognitive and computer sense.

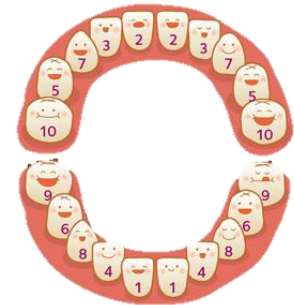**Advantages:**

- Easy to remember and understand
- Unique number for each tooth
- Verbal communication possible
- Compatible with computer keyboard
- Hence most accepted.

**Sequence of eruption**

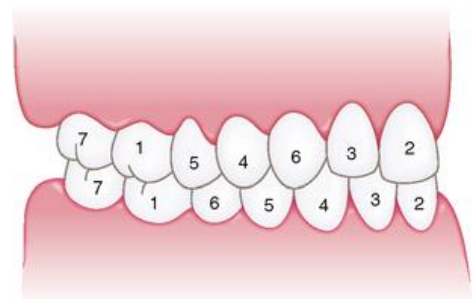
**For primary teeth:**

ABDCE
ABDCE



**For permanent teeth:**

61245378
61234578



## VARIATIONS IN SEQUENCE OF ERUPTION

The mandibular first permanent molars are often the first permanent teeth to erupt. The mandibular central incisors quickly follow them. Then lateral incisor, canine, first premolar, second premolar, and second molar (the most common sequence of eruption of mandibular permanent teeth ), while the most common sequence for the eruption of the maxillary permanent teeth is first molar, central incisor, lateral incisor, first premolar, second premolar, canine, and second molar.

It is desirable that the mandibular canine erupt before the first and second premolars. This sequence aids in: 1. Maintaining adequate arch length and 2. Preventing lingual tipping of the incisors, which not only causes a loss of arch length but also allows an increased overbite to develop. An abnormal lip musculature or an oral habit that causes a greater force on the mandibular incisors than can be compensated for by the tongue allows the anterior segment to collapse. For this reason, use of a passive lingual arch appliance is often indicated when the primary canines have been lost prematurely or when the sequence of eruption is undesirable.

A deficiency in arch length can occur if the mandibular second permanent molar develops and erupts before the second premolar. Eruption of the second permanent molar first encourages mesial migration or tipping of the first permanent molar and encroachment on the space needed for the second premolar.

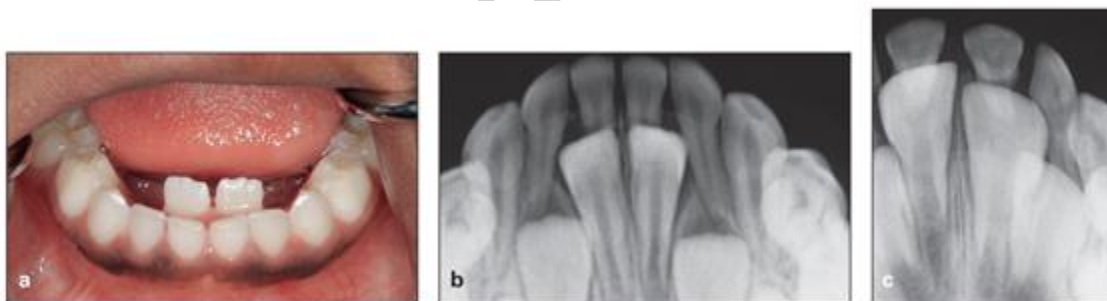
In the maxillary arch, the first premolar ideally should erupt before the second premolar, and the canine should follow them. The untimely loss of primary molars in the maxillary arch, which allows the first permanent molar to drift and tip mesially, results in the permanent canine is being blocked out of the arch, usually to the labial side. The position of the developing second permanent molar in the maxillary arch and its relationship to the first permanent molar should be given special attention. Its eruption before the premolars and canine can cause a loss of arch length, just as in the mandibular arch. The eruption of the maxillary canine is often delayed because of an abnormal position or deviations in the eruption path.

## LINGUAL ERUPTION of MANDIBULAR PERMANENT INCISORS

The primary teeth may have undergone extensive root resorption and may be held only by soft tissues. In other instances, the roots may not have undergone normal resorption and the teeth remain solidly in place. It is common for mandibular permanent incisors to erupt lingually, and this pattern should be considered essentially normal.

The tongue and continued alveolar growth seem to play important roles in influencing the permanent incisors into a more normal position with time. Although there may be insufficient room in the arch for the newly erupted permanent tooth, its position will improve over several months. In some cases there is justification for removal of the corresponding primary tooth. Extraction of other primary teeth in the area is not recommended, however, because it will only temporarily relieve the crowding and may even contribute to the development of a more severe arch length inadequacy.

Even when mandibular permanent incisors erupt uneventfully, they often appear rotated and staggered in position. The molding action of the tongue and the lips improves their relationship within a few months.



## TEETHING AND DIFFICULT ERUPTION

- 1) Increase in salivation, the child will want to put the hand and fingers into the mouth—these observations may be the only indication that the teeth will soon erupt.
- 2) The young child may become restless and fretful during the time of eruption of the primary teeth. He may lose his appetite.
- 3) In the past, many conditions, including croup, diarrhea, fever, convulsions, primary herpetic gingivostomatitis, and even death have been incorrectly

attributed to eruption. Because the eruption of teeth is a normal physiologic process, the association with fever and systemic disturbances is not justified. A fever or respiratory tract infection during this time should be considered coincidental to the eruption process rather than related to it.

- 4) Inflammation of the gingival tissues before complete emergence of the crown may cause a temporary painful condition that subsides within a few days. The surgical removal of the tissue covering the tooth to facilitate eruption is not indicated. If the child is having extreme difficulty and to relief pain use:
  - a) A nonirritating topical anesthetic may bring temporary relief. The parent can apply the anesthetic to the affected tissue over the erupting tooth three or four times a day.
  - b) Several low-dose products specifically formulated for infants are available without prescription. Caution must be exercised, however, when one is prescribing topical anesthetics, especially for infants, because systemic absorption of the anesthetic agent is rapid, and toxic doses can occur if the product is misused. The parent must clearly understand the importance of using the drug only as directed.
  - c) The eruption process may be hastened if the child is allowed to chew on a piece of toast or a clean teething object.

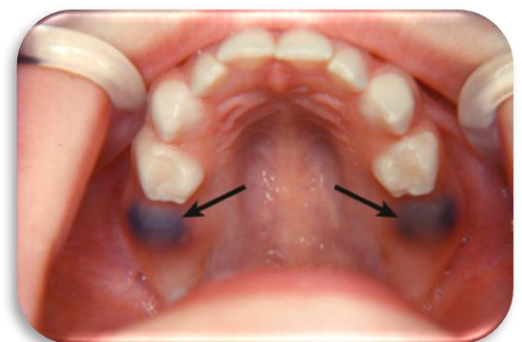
## Interval of rest

It is the largest time between eruptions of two successive permanent teeth

$\frac{2}{2}$  and  $\frac{4}{4}$  1.5 years.

## ERUPTION HEMATOMA (ERUPTION CYST)

An eruption hematoma is a bluish-purple elevated area of tissue occasionally develops a few weeks before the eruption of a primary or permanent tooth. It may result from trauma to the area during function and then hemorrhage in the follicle of an erupted tooth and it will subside after eruption after breakage of the soft tissue by the tooth. The blood-filled cyst is most frequently seen in the primary second molar or the first permanent molar

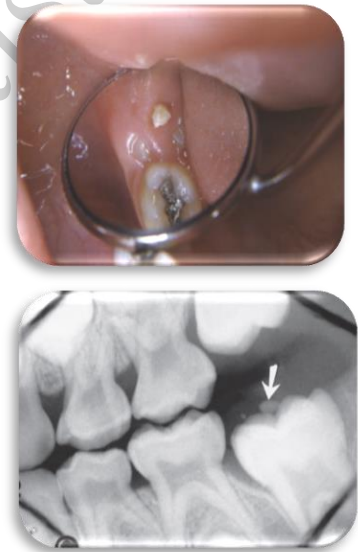


region (6 and E). Because the condition is almost always self-limiting, treatment of an eruption hematoma is rarely necessary. However, surgical uncovering of the crown may occasionally be justified. When the parents discover an eruption hematoma, they may fear that the child has a serious disease such as a malignant tumor. The dentist must be understanding and sensitive to their anxiety while reassuring them that the lesion is not serious.

## ERUPTION SEQUESTRUM

The eruption sequestrum is occasionally seen in children at the time of the eruption of the first permanent molar (6). Clinically it appears as a tiny spicule of nonviable bone overlying the crown of an erupting permanent molar just before or immediately after the emergence of the tips of the cusps through the oral mucosa. It is composed of dentin and cementum as well as a cementum-like material formed within the follicle.

Eruption sequestra are usually of little or no clinical significance. It is probable that some of these sequestra spontaneously resolve without noticeable symptoms. However, after an eruption sequestrum has surfaced through the mucosa, it may easily be removed if it is causing local irritation. The base of the sequestrum is often still well embedded in gingival tissue when it is discovered, and application of a topical anesthetic or infiltration of a few drops of a local anesthetic may be necessary to avoid discomfort during removal.



## ECTOPIC ERUPTION

A variety of local factors may influence a tooth to erupt or try to erupt in an abnormal position such as arch length inadequacy and tooth mass redundancy. Occasionally this condition may be so severe that actual transposition of teeth takes place. First permanent molars may be positioned too far mesially in their eruption path, with resultant ectopic resorption of the distal root of the second primary molar.

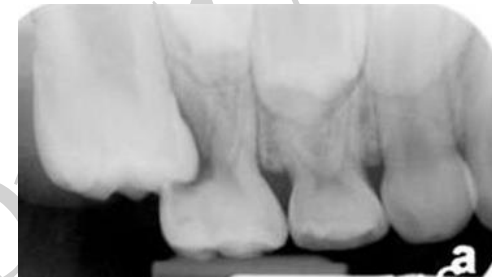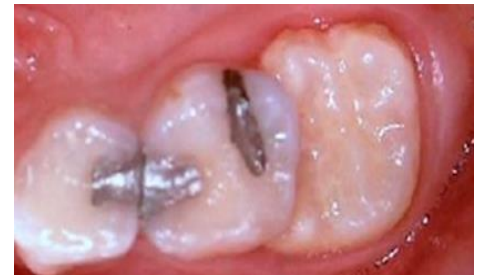There are two types of ectopic eruption—reversible and irreversible. In the reversible type, the molar frees itself from the ectopic position and erupts into normal alignment, with the second primary molar remaining in position while in the irreversible type, the maxillary first molar remains unerupted and in contact with the

cervical root area of the second primary molar. By the ages of 7 and 8 years, any ectopic eruption of a permanent first molar should be considered irreversibly locked.

The ectopic molar often occurred in more than one quadrant and was most often observed in the maxilla.

Irreversible ectopic molars that remain locked, if untreated, can lead to premature loss of the primary second molar with a resultant decrease in quadrant arch length, asymmetric shifting of the upper first molar toward Class II positioning, and supraeruption of the opposing molar with distortion of the lower curve of Spee and potential occlusal interference. Early assessment with intraoral or panoramic films approximating the timing of first permanent molar eruption is thus critical to identification of the problem and provides an opportunity

to intercept potential sequelae. If the problem is detected at 5 to 6 years of age, an observation approach of “watchful waiting” with appropriate monitoring may be indicated, given the two-thirds potential for self-correction. With self-correction being unlikely as the child approaches 7 years of age, continued “locking” of the first molar with advanced resorption of the primary second molar usually warrants intervention. Another timing clue is that when the opposing molar reaches the level of the lower occlusal plane, intervention is indicated to establish proper vertical control and prevent supraeruption.



## Early Eruption

### (NATAL AND NEONATAL TEETH)

Natal teeth are (teeth present at birth) and neonatal teeth (teeth that erupt during the first 30 days) prevalence is low. About 85% of natal or neonatal teeth are mandibular primary incisors, and only small percentages are supernumerary teeth. It is common for natal and neonatal teeth to occur in pairs. Natal and neonatal molars are rare. Most studies suggest that the etiology for the premature eruption or the appearance of natal and neonatal teeth is multifactorial. A possible factor involving the early eruption of primary teeth seems to be familial, due to inheritance as an autosomal-dominant trait.



A radiograph should be made to determine the amount of root development and the relationship of a prematurely erupted tooth to its adjacent teeth. One of the parents can hold the x-ray film in the infant's mouth during the exposure.

Most prematurely erupted teeth (immature type) are hypermobile because of limited root development. 1. If the tooth is extremely mobile to the extent that there is danger of displacement of the tooth and possible aspiration, so the treatment indicated in such a case is the removal of the tooth. 2. If the tooth has sharp incisal edge that may cause laceration of the lingual surface of the tongue, so treatment is the removal of the tooth.

The preferable approach, however, is to leave the tooth in place and to explain to the parents the desirability of maintaining this tooth in the mouth because of its importance in the growth and uncomplicated eruption of the adjacent teeth. Within a relatively short time, the prematurely erupted tooth will become stabilized, and the other teeth in the arch will erupt.

Eruption of teeth during the neonatal period presents less of a problem. These teeth can usually be maintained even though root development is limited.

A retained natal or neonatal tooth may cause difficulty for a mother who wishes to breast-feed her infant. If breast-feeding is too painful for the mother initially, the use of a breast pump and bottling of the milk are recommended. However, the infant may be conditioned not to "bite" during suckling in a relatively short time if the mother persists with breast-feeding. It seems that the infant senses the mother's discomfort and learns to avoid causing it.

