

Conservative dentistry

Lec: 4

ام.د. لنز علي

Classification of Cavity

1. According to tooth surface involvement:

Simple cavity: cavity involve only one surface of the tooth Ex: occlusal cavity (O) CL I.

Compound cavity: cavity that involved two surfaces Ex: mesio-occlusal (MO) CLII.

Complex cavity: cavity involves three or more surfaces.

2. According to site involved:

Site 1: pits, fissure and enamel defects on occlusal surfaces of posterior or other smooth surfaces.

Site 2: proximal enamel in relation to areas in contact with adjacent teeth.

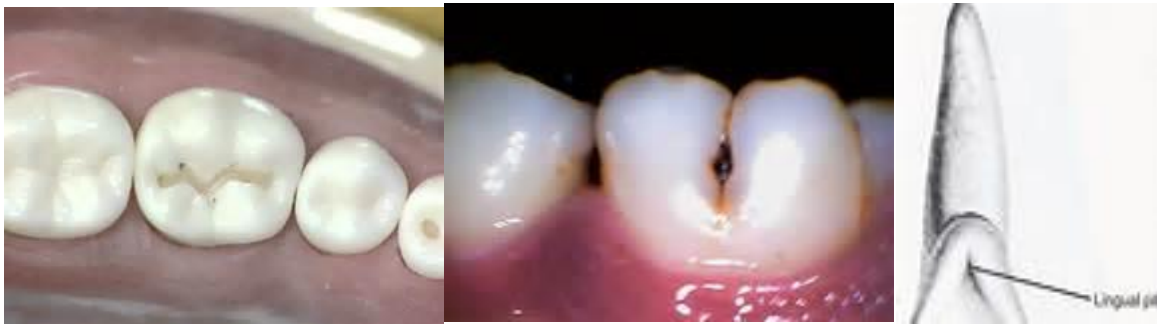Site 3: the cervical one third of the crown or following gingival recession and the exposed root surface.

3. According to G.V. Black:

CLI restorations: these restorations are used in CL I lesions the following surfaces are involved:

- Occlusal pits and fissures of premolars and molars fig 1a.
- Facial & lingual pits and fissures of mandibular molars fig 1b.
- Palatal pits of maxillary incisors, most frequently in the pit near the cingulum.

Conservative dentistry



A

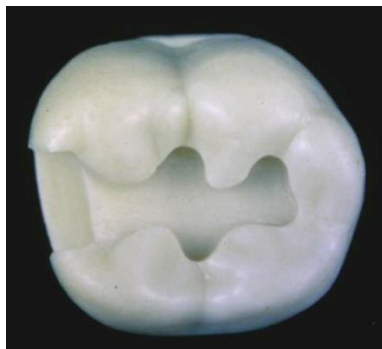
b

c

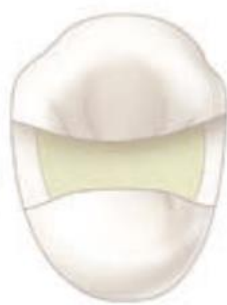Fig 1: CI I

CL II restorations: is the extension of CLI restoration into the proximal surfaces of premolars and molars, the following surfaces are involved:

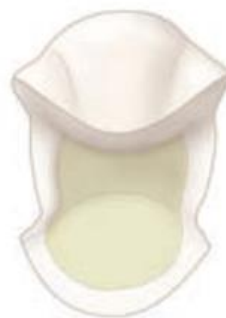- Two surface restoration of posterior teeth fig 2a.
- Three surface restoration of posterior teeth fig 2b.
- Four surface (or more) restoration of posterior teeth fig 2c.



a



b



c

Fig 2. CI II

Conservative dentistry

CLIII: affects the interproximal surface of incisors and canines fig 3.

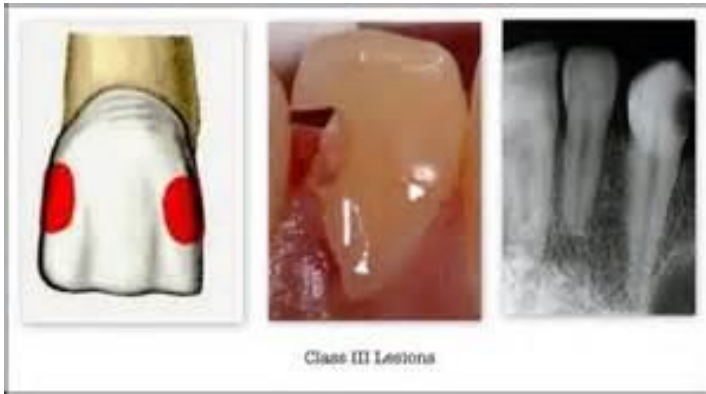

Fig 3: CL III

CLIV: involves a larger surface area, including the incisal edges and interproximal surface of incisors and canine fig 4.

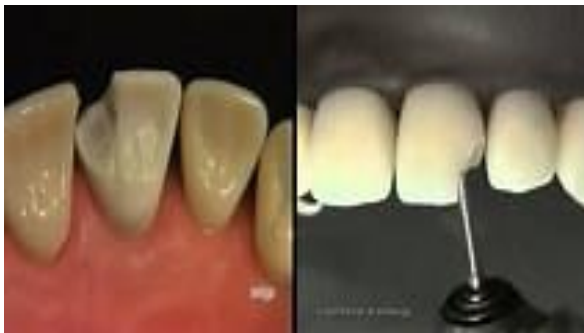

Fig 4: CL IV

CL V: - gingival third of the facial or lingual surfaces of any tooth.

Root of a tooth near the cemento-enamel junction fig 5.

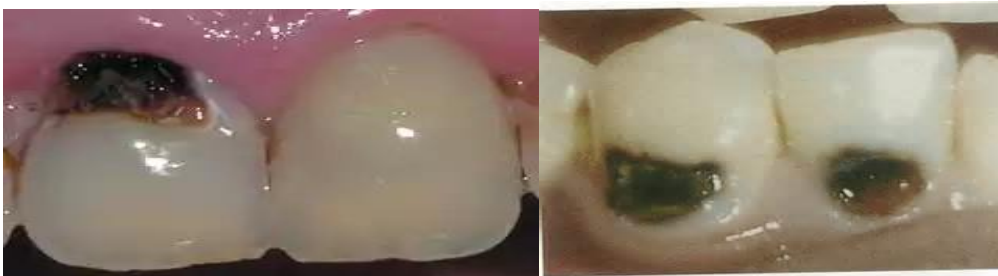

Fig 5: CL V

Conservative dentistry

CI IV: incisal edge of anterior teeth or on cusp tip of posterior teeth

Objectives of cavity preparation

- 1- To remove diseased tissue as necessary and at the same time provides the protection to the pulp.
- 2- To locate the margins of the restoration as conservative as possible.
- 3- To ensure the cavity form, it should not be under the force of mastication of the tooth.
- 4- To allow the functional placement of the restorative material.

Steps in the cavity preparation (Given by G. V. Black)

Obtain outline form.

Obtain resistance form

Obtain retention form.

Obtain convenience form.

Removal of remaining carious dentin.

Finishing of enamel walls & margins

Performing the toilet of the cavity

Class I cavity

1. **Establishing the outline form** means placing the preparation margins in the positions they will occupy in the final preparation, the typical features of establishing proper outline form and initial depth are:

Conservative dentistry

- Width of the facio-lingual walls of the cavity should be $\frac{1}{4}$ I.C.D (inter-cuspal distance).
- Preserving marginal ridge strength (2mm thickness marginal ridge).
- The depth of the preparation into dentin should be 1.5-2mm.
- The extent of the caries lesion affects the outline form of the proposed tooth preparation because the **objective is to extend to sound tooth structure also** Ideal outline includes all pits & fissures even if its sound to prevent them from caries in the future (**extension for prevention**).

2. Resistance form

Is the shape of the cavity that enables both the tooth and restoration to withstand occlusal forces without fracture.

And this includes:

- Factors prevent fracture of the tooth
- The facio-lingual width of the preparation should not exceed $\frac{1}{4}$ I.C.D fig 6.

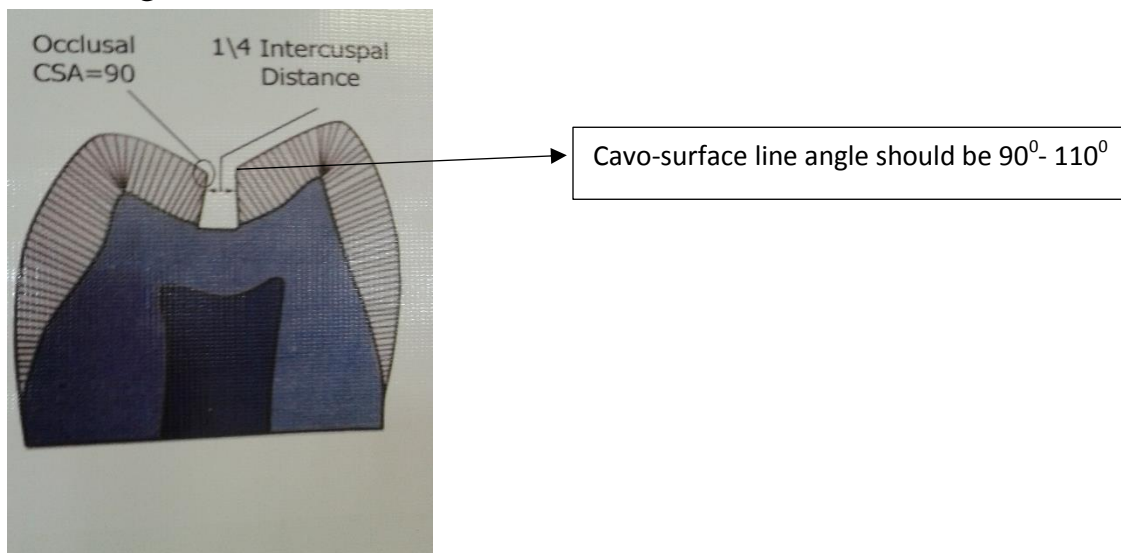


Fig 6: resistance means of CL I.

Conservative dentistry

- Mesial & distal walls of the cavity should be parallel and slightly *diverge occlusally* to be within the enamel rod direction and prevent any unsupported enamel at the marginal ridge.
- All internal line angle should be rounded to prevent stress concentration area.

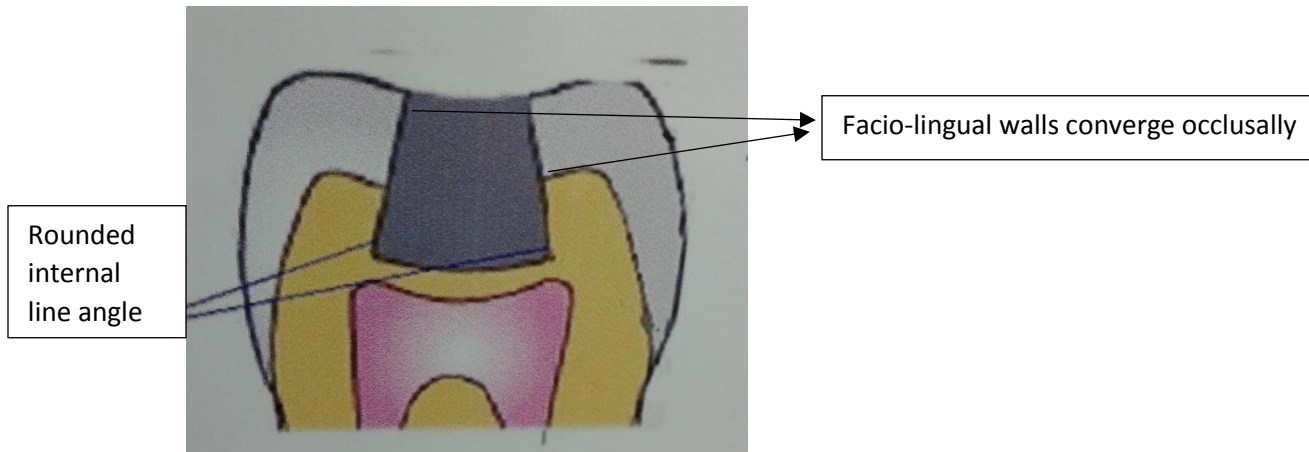


Fig 7

- Factors prevent fracture of restoration
- Facio-lingual width should be $\frac{1}{4}$ I.C.D because large surface area exposed to more force and fracture occurs.
- Occlusal amalgam should have thickness of (1.5-2.0 mm) to resist fracture during function.
- Factors prevent fracture for both tooth and restoration:
- Removal of unsupported enamel by making the margin (90° - 110°) because less than 90° the tooth is more subjected to fracture if more than 110° lead to fracture of restoration .
- Smooth pulpal floor to prevent stress concentration area.

Conservative dentistry

3. **Retention form:** is the shape of the cavity that permits the restoration to resist displacement through the tipping or lifting force.

To provide retention the cavity has the following:

- Opposing wall of should be parallel to each other or *converge occlusally* (5°) this convergence done on buccal and lingual wall fig 7.
- The floor of the cavity should be *flat* to prevent restoration movement.
- Outline form should be small as possible to prevent displacing force on it.
- Dove-tail preparation to increase retention.

4. Convenience form:

Is the shape of the cavity that allows an adequate observation, accessibility this achieved by giving good depth (1.5-2mm) and width ($\frac{1}{4}$) I.C.D

5. Removal of remaining caries

Deep dentinal caries can be removed by using spoon excavator or large round bur with slow speed hand piece.

6. Finish enamel walls

Involve making the wall smooth and removing of unsupported enamel.

7. Clean the preparation:

Removal of all debris by washing the cavity and drying it.

Conservative dentistry

Clinically:

Occlusal outline form:

Enter the pit with a punch cut using no.245 bur fig 8 A, the long axis of the bur & the long axis of tooth crown should remain parallel during cutting procedures, the bur should be rotating when applied to the tooth and should not stop rotating until removed.

Proper depth of the initial entry cut is 1.5-2 mm.

While maintaining the same depth & bur orientation move the bur to extend the outline to include the central groove & the opposite pit fig 8 B which provided by dovetail retention form the isthmus width should be as narrow as possible & no wider than $\frac{1}{4}$ I.C.D, it may be necessary to tilt the bur to create facial, lingual slight occlusal convergence & mesial and distal walls to diverge occlusally.

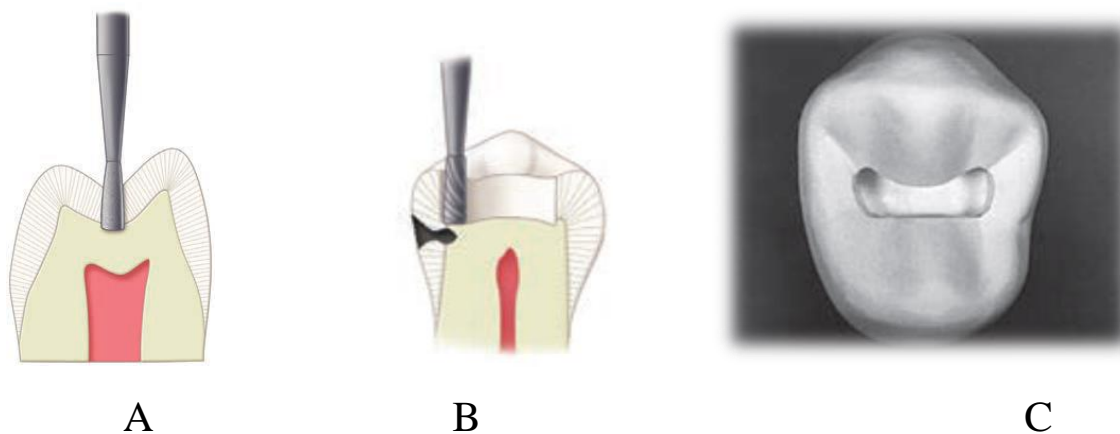


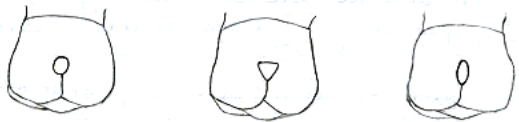Fig8: A. initial depth, B. bur position to begin the proximal ditch cut. C, C I I cavity preparation

Conservative dentistry

Buccal Pit Cavities:

The outline of these cavities usually describes a triangle with its base forming the gingival wall and its sides forming the mesial and distal walls, the gingival wall is placed at or slightly occlusal to the height of contour of the tooth.

- All walls are extended just enough to eliminate defective enamel and dentin.
- The enamel walls are planned in the direction of enamel rods and perpendicular to the axial wall.
- Hoe excavators are used to smooth the axial wall and make it parallel with the external surface of the tooth.
- It should be re-emphasizing that the shape of the cavity will be governed by the extension of caries, accordingly the outline of these cavities may be a rounded or oval in shape.



OUTLINE FORM FOR PIT RESTORATIONS

Occlusal pits of mandibular first premolars

Mandibular 1st. premolars have 2 exceptions:

1- We can make 2 separated cavities one on mesial occlusal pit & one on distal without including central fissure if this fissure is not involved by caries because of the presence of well-developed transverse ridge & in order not to weaken the tooth unless the fissure is involved by caries so we have to include all pits & fissure in one class I preparation.

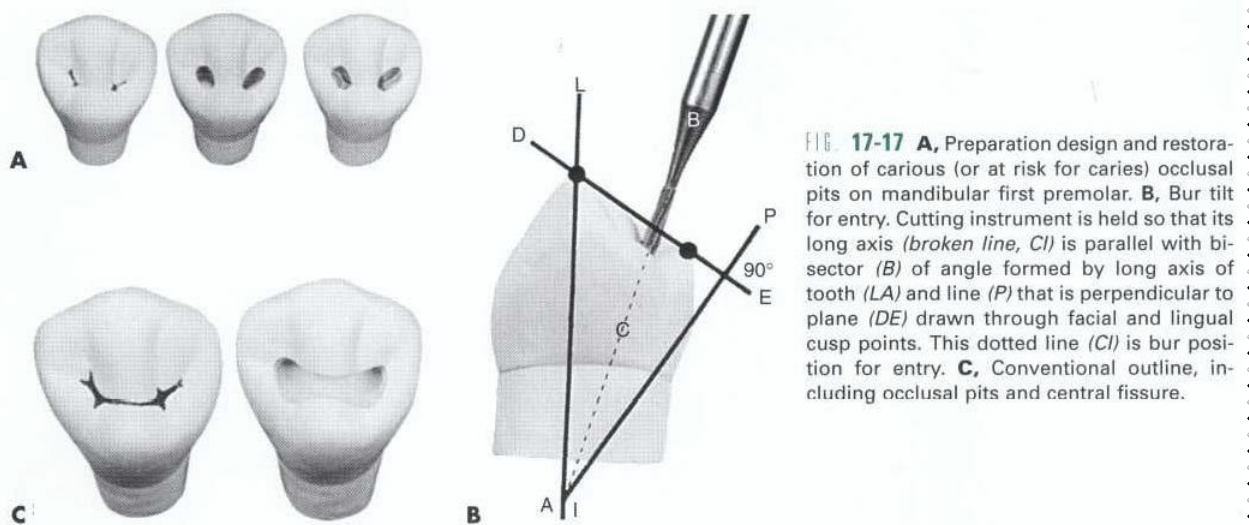
2- The buccal horn of pulp is higher than the lingual one. So according to this

Conservative dentistry

when we prepare the cavity floor it should be inclined lingual (not flatted) in order not to harm the pulp.

To achieve this cutting instrument is held so that its long axis is parallel with bisector of angle formed by long axis of tooth and the line perpendicular to plane drawn through facial & lingual cusp point (see lower Fig)

All the principles of cavity preparation for class I as discussed previously were applied here except *flattening of pulpal floor*.



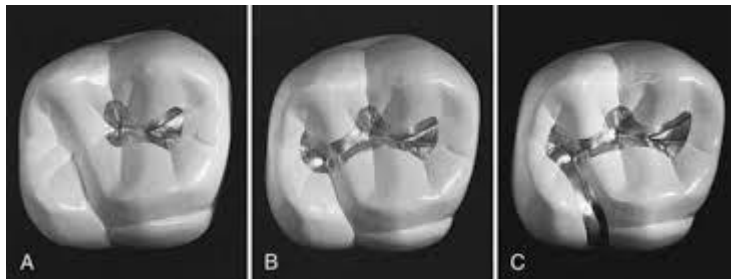
Cavity preparations for maxillary first molars

Upper 6 also had exceptions because of the anatomy of the tooth. The presence of oblique ridge in between distobuccal & mesiopalatal cusps gives the possibility to do 2 separated cavities one mesial & one distal without the need to include oblique ridge within the preparation unless it is involved by caries or weakened duo to cavity preparation in this case one outline cavity design extended from mesial pit through oblique ridge to distal pit were performed.

Conservative dentistry

Buccal and Lingual Extensions:

- In case of occluso-buccal and occluso-lingual cavities extensions are made through the fissures and towards the respective surfaces.
- The cutting is done in dentin at the amelo-dntinal junction using a #56 fissure bur until the occlusal ridge is undermined and removed.
- If the caries is still gingival to the level of the pulpal seat, a step is indicated: a #330 or 56 bur is used to cut the dentin at the amelo-dentinal junction, applying pressure in a gingival direction and at the same time moving the bur mesio-distally.
- The enamel thus undermined, is broken down with chisels.
- Retention grooves are then cut in dentin along the axio-mesial and axiodistal line angles. The cavity walls and margins are finished as previously described.



Class I with Palatal extension of upper 1st molar

The same principles and procedures for Class I cavity preparation were applied occlusally. For the extension: The tooth preparation for the extension should be no wider than necessary; ideally the mesiodistal width of the palatal extension should not exceed 1 mm, except for extension necessary to remove carious or undermined enamel or to

Conservative dentistry

include unusual fissuring. The tooth preparation should be cut more at the expense of the oblique ridge rather than centering over the fissure (weakening the small disto-lingual cusp). Especially on smaller teeth, the margins on the occlusal portion should extend as little as possible on to the oblique ridge and disto-lingual cusp.