

IMMEDIATE DENTURES 2nd part

ام د. رغداء كريم جاسم

Explanation to the Patient Concerning Immediate Dentures:

1. They do not fit as well as complete dentures. They may need temporary linings with tissue conditioners and may require the use of denture adhesives.
2. They will cause discomfort. The pain of the extractions, in addition to the sore spots caused by the immediate denture, will make the first week or two after insertion difficult.
3. The esthetics may be unpredictable. Without an anterior try-in, the appearance of the immediate denture may be different from what you expected.
4. Many other denture factors are unpredictable such as the gagging tendency, increased salivation, different chewing sounds, and facial contour.
5. immediate dentures must be worn for the first 24 hours without being removed by the patient. If they are removed, they may not be able to be reinserted for 3 to 4 days. The dentist will remove them at the 24-hour visit.
6. Because supporting tissue changes are unpredictable, immediate dentures may loosen up during the first 1 to 2 years , or 4- 6 months depending on the no. of teeth and their location

Immediate complete denture construction

1-One step immediate complete denture:

In some cases it is necessary to fit immediate dentures without the prior extraction of the posterior teeth e.g. when the anterior teeth are causing pain or are excessively loose, or if the patient wishes to shorten the number of visits for extractions.

This method is not suitable for general practice and should only be employed if the patient can be treated in a hospital or nursing home.

Procedure for construction:

- 1- Impressions of both jaws are taken in hydrocolloid, care being taken to secure a good reproduction of the sulci.
- 2- The resulting casts are mounted on an articulator by means of a wax inter occlusal record.
- 3- Duplicates of these casts are made for reference when setting the teeth.
- 4- The teeth are removed from the cast and the ridge is trimmed, duplicates of these casts are made and on them clear acrylic templates are prepared.
- 5- The artificial teeth are set up and the denture cured and completed with normal flanges.

6-The patient is admitted to hospital, the teeth removed and the ridges trimmed with the aid of the templates, and the dentures inserted.

7-This technique gives remarkably successful results, its main drawback being that the rapid resorption renders the dentures and become ill fitted after a few weeks, and two times relining are usually necessary within the first three months.

2- Two steps immediate complete denture

The immediate complete denture is constructed two months after extraction of the posterior teeth and inserted at the time of extraction of the anterior teeth.

Complete immediate denture insertion usually follows a two stage surgical approach:

1-Posterior teeth are first extracted leaving only two opposing posterior teeth bilaterally as centric stops to maintain vertical dimension of occlusion.

2-Two months waiting period is allowed for healing of the extraction sites and to allow time for bone remodeling.

3-The plaster teeth are broken from the cast and a complete immediate denture is prepared.

4-Anterior teeth are then extracted and the finished denture is immediately inserted.

5-Immediate denture may either be a single denture or both upper and lower dentures. When both dentures are proposed, it is advisable to construct them simultaneously.

Clinical Steps for immediate denture construction (two steps)

Procedures for construction:

1- **Diagnosis and mouth preparation**-Good oral hygiene is essential before starting any prosthodontic treatment.

❖ Patient's systemic condition.-

it is very important to check the general health of the patient because multiple extraction may not be tolerated by all the patients, that's why patients with uncontrolled systemic diseases should not be included in this, type of treatment. Patients under medical control and do not interfere with the steps of denture construction including several teeth extraction with or without some surgical corrections can be included, medical consultation is advisable.'

❖ Full dental history must be recorded in the case sheet.

❖ Periodontal condition of the remaining teeth must be assess, this must include teeth mobility, measurement of the 'pockets; because this .might affect surgical step of the treatment course. Severe case of periodontal disease may suggest some surgical correction after extraction to have well contoured residual ridge covered with firmly attached mucosal tissue. Periodontal condition may give a primitive assessment about the , bone remodeling sllbsequ~nt to the surgical phase.

- ❖ Full teeth charting, teeth may help in retention as a PD or over denture abutments must be determined, any soft or hard tissue correction as frenal release or bone reduction must be included after good evaluation.
- ❖ Radiographic examination is essential for immediate denture patients.
 - Periapical radiograph may be useful for localized area;
 - OPG view give general view for both jaws in single image.
- ❖ Teeth mold and shade must be recorded, proper communication with the patient about his teeth shade and form is essential, furthermore teeth alignment and any individual variations as diastema, spacing, rotation of the teeth if the patient like to preserve same appearance or improvement could be suggested by you for better appearance. BUT it is very important to remove any premature contacts because these may interfere with correct jaw relation record, essential changes to improve occlusal plane, midline, overjet and overbite and any other corrections that help in esthetic and functional requirements.
- ❖ Occlusal plane adjustment is necessary because the factors that necessitate tooth extraction are often associated with occlusal discrepancies. These also interfere with centric relation record as well as with the proper determination of occlusal vertical relation. Proper location of low and high lip lines must be determined to determine the required changes in teeth position or angulations
- ❖ Presence of any infection or inflammation in the soft and hard tissues. Periapical abscess, granuloma and cysts may make the estimated tissue changes at the time of extraction and healing and remodeling process unpredictable, this may increase of the risk of unfitted immediate denture.
- ❖ Previous prosthesis, -if present- must be checked as an additive reference for the jaw relations or teeth selection. It also may help the dentist to explain some of treatment or correct some errors.
- ❖ In many cases of immediate denture construction, a diagnostic casts are essential. These casts could serve a lot in the treatment plan and communication with the patient. The casts also can be used as a preextraction record .
- ❖ All immediate denture patients must have good oral prophylaxis, proper scaling and good oral hygiene, this will reduce post-operative edema and infection. Other treatments as restoration crown and bridges or even RPD all must be one coincidence with immediate denture planning.

In the diagnosis step; with all the collected information you have to decide type of surgical procedure, immediate denture can be constructed with one of the surgical procedure:-

- 1-Extraction of teeth only.
- 2- Extraction of teeth with alveoloplasty. In some case simple corrections may be needed at the sight of extracted teeth to improve the shape of the alveolar process in

order to facilitate and improve denture objectives. In these cases surgical splint construction is important. This splint usually constructed on the master cast after teeth trimming. Cases with excessive bone correction may be end up with rapid bone resorption and unfitted denture, therefore bone removal must be conservative. Consultation with the surgeon is essential in some cases.

2- Extraction of posterior teeth

In case of complete immediate denture .Extraction of all posterior teeth except unilateral, or preferably, bilateral opposing premolars which provide a definite contact at the patient's occlusal vertical dimension as this vertical dimension appears to be acceptable physiologically as posterior vertical stop

3.Preliminary impressions

.The primary impressions are made in perforated stock trays with the alginate irreversible hydrocolloid impression material to obtain study cast.

Fabrication of custom tray

4. 2ndFinal impression

a. Single Impression Technique

.Autopolymerizing acrylic resin custom trays are made over the diagnostic cast with wax spacer covering anterior teeth and posterior edentulous area. And with proper Stoppers.

.The tray is border molded, .then the rubber base impression material is used to record all areas in one impression.

.The impression is poured in stone:-Single tray with modeling compound and rubber base most commonly used. Then use wax to block out large interdental embrasures.

Perforate the custom tray for the mechanical retention of alginate.

Single tray with alginate is only used when considerable tooth misalignment or great mobility present.

b. Sectional impression Tech. (two steps tech.,

1. .An acrylic resin special tray is constructed, covering the
2. edentulous area Posteriorly and resting on the lingual
3. surface of the remaining anterior teeth
4. .Tray is border molded
5. .Impression is made with zinc-oxide / E paste
6. .Overall alginate impression is taken in stock tray

.Indications of this tech.:

* Very divergent teeth

* Severe ridge Undercuts

C. Campagna Impression Technique:

It uses a special tray with labial flange to take the final impression.

Then over all alginate impression with stock tray

The main advantage of this tech. is the more accurate impression of the labial vestibule.

A custom tray border molded with impression compound, a rubber base impression material impression of the anterior vestibule and edentulous area, reinserted, and then captured in an alginate over-impression.

5.Maxillomandibular Relation Records

.jaw relation records are made by the use of occlusion rims. The occlusion rim covering the edentulous area is made the same, but the record base may extend onto the cingulae of the remaining teeth to provide additional support. This extension of the upper record base must not interfere with normal occlusion of the lower natural teeth.

.The occlusion rims are the only reliable index of inter-arch distance in an immediate denture.

6.Selection of teeth:

The remaining natural teeth guide in the selection of teeth, direct measurements will help in duplicating the natural teeth.

7.Arrangement of anterior teeth can be made in different .. Ways, we have to decide:-

1- If the teeth are need to be changed in location or alignment to improve the aesthetic.

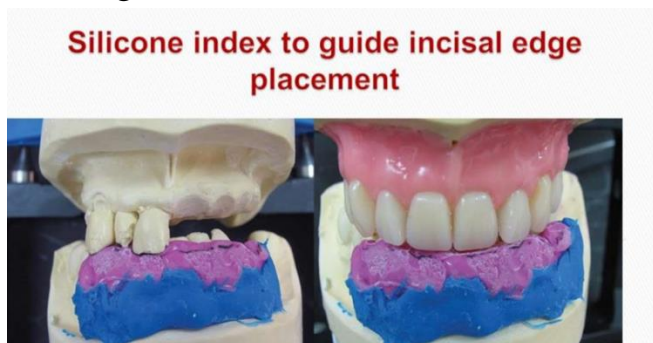OR

2-Tthe teeth are well aligned, aesthetically and functionally acceptable; then we can reproduce same alignment in the denture.

- First way:-

produce a labial index of the natural teeth before they are cut off the cast. The index can be produced quite simply by molding silicone putty against the labial surface of the teeth and ridge on the cast, wait till the material set, trim the cast, then the artificial teeth can be set into the index while its held against the cast preserving same teeth location.

-In this technique same teeth morphology and location is duplicated, thus consultation with the patient about own teeth alignment and morphology must be made at the time or diagnosis .



• Second way:-

Remove one tooth from the cast and immediately wax an artificial tooth into position so that the adjacent teeth serve as a guide to the positioning of the artificial replacement. Repeat this procedure alternatively.

-If you decide to duplicate teeth position so you have to an index; either by using silicon impression material ; heavy body, adapted to the teeth on the cast and then used to match artificial teeth location OR use the alternative or every other method; you can use every tooth as an index to arrange same tooth but in the other side OR trim all the teeth on one side and use the other side as a reference.

8.Evaluation of the trial denture(Try-In)

Confirmation of horizontal and vertical relationships

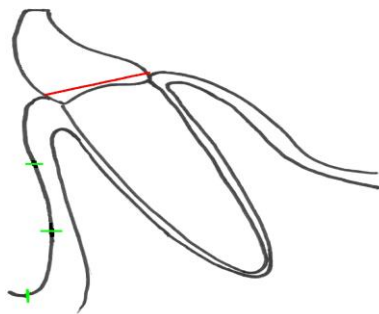
.Tooth shade

Steps of trimming are:- Removal of the teeth and cast preparation: The denture is constructed on a working cast which is trimmed to the anticipated contour of the ridge after surgery.

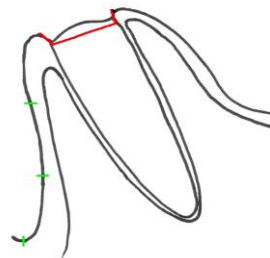
Reference lines are drawn on the cast

Preparation of the cast differs according to the type of immediate denture

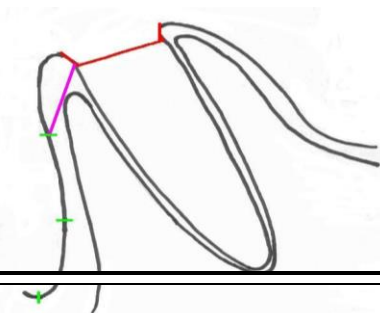
Step 1 Remove tooth at gingival level



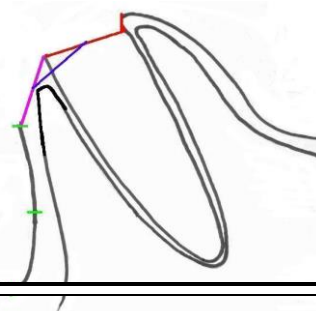
Step 2 Recess Socket 1 mm



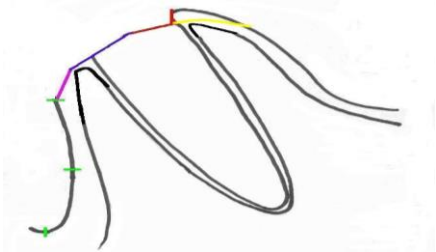
Step 3 Labial edge recess to incisal third mark



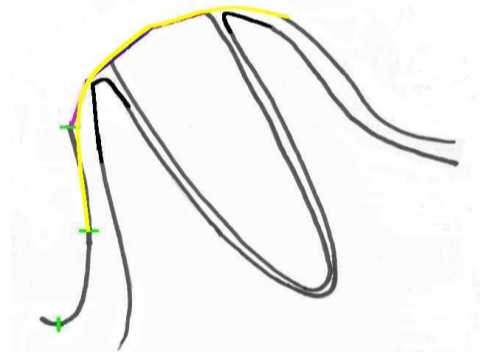
Step 4 Mid-point recess to mid-width labial cut



Step 5 Round over lingual aspect of socket



Step 6 Round off labial to middle third, sand smooth



10 Fabrication of Surgical Template

A clear surgical template duplicating the surface of the immediate denture after modification of the stone cast is used at the time denture placement as a guide for surgically shaping the alveolar process. The clear template allows the dentist to visualize the adaptation of the denture base to the residual ridge.

Blanching of the soft tissue as seen through the template indicates excessive pressure. When the extractions and alveolectomy are being done, the surgical template can be inserted in the patient's mouth from time to time to assess if sufficient bone has been removed.

11.Surgical procedure:

12.Placement of the denture

- After completion of the surgical procedures, the patient is instructed to close against sterile gauze until the cessation of the bleeding. As soon as the patient has recovered from the immediate effects of the operation, the denture is inserted.
- Pressure-disclosing material will aid in locating pressure points,
- check the occlusion, even gross occlusal disharmonies in an immediate denture are corrected in the mouth.

Final occlusal adjustment will be delayed until all swelling and edema have subsided and the patient is comfortable.

13.Patient Instructions

The instructions should be both written and oral, and include specific information about the first 24 hours, care of the oral tissues and dentures, changes in the residual ridge, and denture maintenance.

14.Post-placement Care

- .Pressure-indicating paste is used to locate pressure areas
- .overextensions of the denture borders are reduced.
- .The occlusion is checked for interceptive occlusal contacts.

.patient should be seen every 24hours for the first three days, then every other day for one week.

The first 24 hours

- Patient should Not to remove the dentures from the mouth during the first 24 hours,
- Patient should be reminded that the pain from extraction will not reduce by removal the denture.
- ice packs may be held on the face to combat swelling.
- eat a soft diet
- Analgesic, antibiotic, must be prescribed to patient depending on the case.
- return for a scheduled appointment.
 - 1st Adjustment must be seen after 24 hours:-
 - Remove denture 5 times per day
 - Rinse the mouth with warm saline
 - Avoid mouthwash containing alcohol

The dentures should be worn at night for the first week only, after this period, the dentures should be week only, after this period, the dentures should be removed at night.

Proper nourishment is essential to the overall treatment of the patient and must not be neglected.

• 1 st week after extraction and denture insertion:-

1-Instruct your patient to wear the denture day and night for first 7 days after extraction or until swelling reduction.

2-Remove the denture 4 or 5 times a day after the first day, and rinse the mouth with warm salt water. Do this for the first week.

3- The denture must be cleaned and rinsed after meal as early as possible and when removal and insertion of the denture is with little or tolerable pain .

•Further follow up care:-

1- 2nd week is the next call, this is depend 0 the case. Then the patient should be seen one month later, 4-6 months intervals.

2-A denture adhesive will be necessary to help hold the denture in place.

3- Relining may be necessary to achieve esthetic and occlusion corrections.

4- Frequent or periodic recall mainly for changing temporary liner, this is depend on the rate and amount of bone resorption and ability of patient to keep the liner clean

Maintenance of Immediate Complete Dentures

a.Occlusal equilibration

It is delayed for 5 to 10 days in immediate denture treatment until all swellings has subsided and the patient is comfortable. It is best done on the articulator with clinical

remounting.

b. Denture reline, rebase or remake. Healing affects the denture fit

.Short term tissue conditioners

.Mid-term

–intermediate direct liners

.Long-term

–standard reline protocol

Comparisons of flanged and open faced denture :-

1. appearance of flanged denture does not altered after fitting where the appearance of open – face denture (although good initially) can deteriorate rapidly as resorption create a gap between the necks of the teeth and ridge

2. the flanged denture allows freedom in the positioning of teeth ,where, in open face denture teeth have to be positioned in the sockets of the natural teeth

*so on case of malpositional teeth we can do good alignment in flanged denture while we can not in open face type.

3. In upper denture:

a flange on an upper denture create a more effective borders seal , therefore , better retention than is achieved with an open face denture.

In lower denture:

open face denture is not usually constructed because of poor stability of lower denture during function , so flange denture is commonly used.

*so flange denture is better from the point of stability.

4. The presence of labial flange produces a stronger denture, labial flange will make the denture stiffer so the midline fatigue fracture cause by repeated flexing across the midline is reduced .so from the point of strength the flange denture is better .

5. As the bone resorbed fallowing extraction the denture become loose and a reline is required , so the presence of labial flange make it easier to add either a short – term soft lining materials or a cold curing relining materials as a chair side procedure, as the color of some reline materials is not always ideal they may be visible when used with open face denture.

6. The flange denture cover the clot completely and protect them more effectively, the flange denture exerts pressure on both lingual and labial gingiva reducing post extraction hemorrhage.

7. The consequence wearing of ill fitting denture can lead to:

If it is open face ,will produce a scalloped ridge in the region of the socketed teeth

In flange denture ,distribution the functional loads more favorably to the underlying ridge, thus minimizing bone resorption.

8. When patient have got used to an open face immediate denture there is difficulty to accept a denture with labial flange in future and patient will complain from the fullness of the lip .

If flange denture had worn from the beginning this problem does not occur.

9. When the ridge morphology produce deeply undercut area it may not be possible to fit a full labial flange unless there is surgical reduction, In this case the using of partially flange denture or open face denture is preferable when surgical procedure is contra indication.

immediate denture can be classified according to type of restoration into:-

1- Immediate complete denture.

2- Immediate partial denture.

3- Immediate over denture.