

Dr. Hadeel Mazin

Terms in periodontology

The term *periodontium* arises from the greek word "*Peri*" meaning around and "*odont*" meaning tooth, thus it can be simply defined as "*the tissues investing and supporting the teeth*".

The periodontium is composed of the following tissues namely:

- Alveolar bone.
- Root cementum.
- Periodontal ligament (Supporting tissues).
- Gingiva (investing tissue).

The various diseases of the periodontium are collectively termed as *periodontal diseases*.

Periodontal therapy: is the treatment of periodontal diseases.

Periodontology: the clinical science that deals with the periodontium in health and disease.

Periodontics: is the branch of dentistry concerned with prevention and treatment of periodontal disease.

The Oral Mucosa

The oral mucosa consists of three zones:

1. **Masticatory mucosa:** it includes the gingiva and the covering of the hard palate.

The boundaries are from the free gingival margin to the *mucogingival junction* on the facial and lingual surfaces.

The *mucogingival junction* is a distinct line between the attached gingiva apically and the alveolar mucosa.

No mucogingival junction on the palatal side because both gingiva and alveolar mucosa are of the same type which is masticatory mucosa.

The tissue is firmly attached to the underlying bone and covered with **keratinized** epithelium to withstand the frictional forces of food during mastication.

2. **Specialized mucosa:** it covers the dorsum of the tongue.
3. **Lining mucosa:** is the oral mucous membrane that lines the remainder of the oral cavity. Examples for this type are the tissue covering the lips, cheeks, floor of the mouth, inferior surface of the tongue, soft palate and the alveolar mucosa.

Alveolar mucosa: is located apical to the attached gingiva and extends into the vestibule of the mouth, it is darker red and movable because it has no elastic fibers.

Biology of the periodontal tissues

Introduction

Periodontium is the functional unit of tissues supporting the tooth including gingiva, the periodontal ligament (PDL), the cementum and the alveolar process.

The tooth and the periodontium are together called the *dentoperiodontal unit*.

The main support of the tooth is provided by the periodontal ligament, which connects the cementum of the root to the alveolar bone or tooth socket into which the root fits.

The gingiva

Macroscopic features

It is that part of the oral mucosa (masticatory mucosa) that covers the alveolar process of the jaws and surrounds the neck of the teeth. The main function of the gingiva is to protect the surrounding tissues from the oral environment.

Anatomically the gingiva is divided into:

1. Marginal gingiva (free or un-attached gingiva)
2. Attached gingiva
3. Interdental gingiva

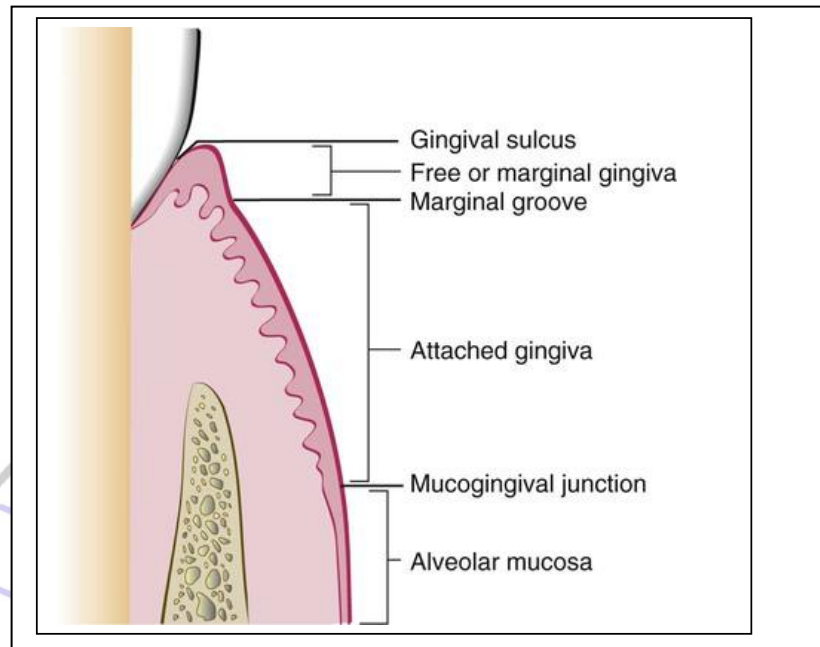


Diagram illustrating anatomic landmarks of the gingiva

Marginal gingiva (free or un-attached gingiva):

It is the terminal edge or border of the gingiva surrounding the tooth in a collar-like fashion. It is well adapted to the tooth surface but it is not attached to it. It is separated from the tooth by a fine space called the gingival sulcus.

The marginal gingiva is separated from the attached gingiva by the **free gingival groove** which is (a shallow linear depression on the faciolingual surface that roughly corresponds to the base of the gingival sulcus). The free gingival groove is about **1mm** wide and it is only present in about 30-40% of adults.

Gingival sulcus: is defined as the space or shallow crevice between the tooth and the free gingiva, which extends apical to the junctional epithelium.

It is V-shaped and barely permits the entrance of periodontal probe. Under **ideal** condition it is about **0mm** which is seen only in germ free animal. The probing depth of **normal** gingival sulcus is 2-3mm. in histological section the depth is about **1.8mm**.

Attached gingiva:

It is that part of the gingiva which is firm, resilient and tightly bound to the cervical portion of the tooth and underlying periosteum of the alveolar bone by the gingival fibers and the junctional epithelium.

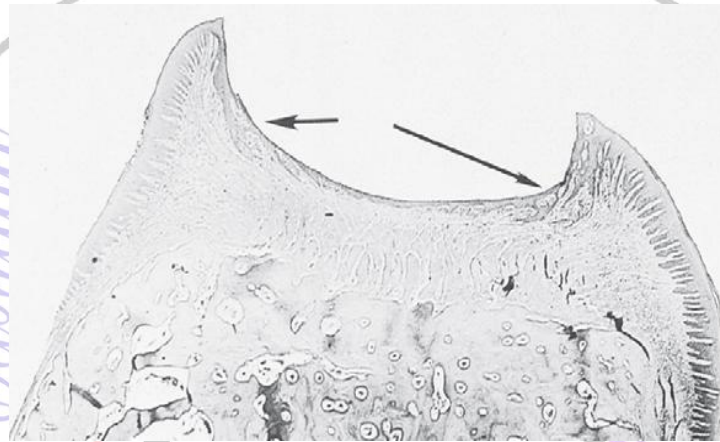
It is demarcated coronally from the free gingiva by the free gingival groove, and extends apically to the mucogingival junction where it becomes continuous with the alveolar mucosa. *(the junction between the attached gingiva and the alveolar mucosa is called the mucogingival line or junction).*

The width of attached gingiva is the distance between the mucogingival junction and the projection of the external surface of the bottom of the gingival sulcus or the periodontal pocket.

The width of attached gingiva is **greater** in maxilla than mandible. **Least** width in the mandibular 1st premolar area and the **greatest** width are in the maxillary incisors region. The width of attached gingiva **increases** with age and supra-erupted teeth.

Interdental gingiva:

It occupies the gingival embrasure. It is of two shapes (Col and Pyramidal). **Col** is a valley-like depression that connects the facial and lingual papilla. It is covered by thin non-keratinized epithelium representing the most frequent site for initiation of disease process.



Col

The **lateral** border and **tip** of the Interdental papilla are formed by continuation of **marginal** gingiva and the **intervening** portion by the **attached** gingiva.

In the presence of diastema the Interdental papilla will be absent.

The shape of Interdental gingiva depends on

- The contact relationship between the teeth.
- The width of the proximal tooth surfaces
- The course of the cemento-enamel junction.

Microscopic features

The gingiva consists of a central core of **connective** tissue covered by stratified squamous **epithelium**.

Three types of **epithelium** exist in the gingiva:

1. The oral or outer epithelium (Keratinized epithelium)
2. The sulcular epithelium
3. The junctional epithelium (Non-keratinized epithelium).

The oral epithelium: it covers the crest and the outer surface of the marginal and attached gingiva. On average, the oral epithelium is **0.2-0.3 mm** in thickness. It is keratinized or parakeratinized or combination of both

Keratinization varies in different areas in the following order

- Palate (Most keratinized)
- Gingiva
- Ventral aspect of the tongue
- Cheek (least keratinized)

The boundary between the oral epithelium and the underlying connective tissue has a wavy course. The projections of epithelial cells into the connective tissue are known as "**Rete Pegs**" while the intervening connective tissue portions which project into the epithelium are called **connective tissue papillae**. This alternating pattern of depression and protuberances of the connective tissue papillae and epithelial rete pegs is thought to give the attached gingiva the **stippled appearance**.

The oral epithelium has the following cell layers:

1. **Basal layer (stratum basale or stratum germinativum):** the basal cells are either cuboidal or cylindrical and possess the ability to divide. It is called stratum germinativum because it is where the epithelium renewed.
The basal cells are separated from the connective tissue by a basement membrane.
2. **Spinous layer (Stratum spinosum):** consists of large cells with short cytoplasmic processes resembling spines.
3. **Granular layer (stratum granulosum):** electron dense keratohyalin bodies begin to occur. These granules are believed to be related to synthesis of keratin.
4. **Keratinized cell layer (stratum Corneum):** This is the most superficial layer and where both para and ortho-keratinization occur.

Types of cells in the oral epithelium:

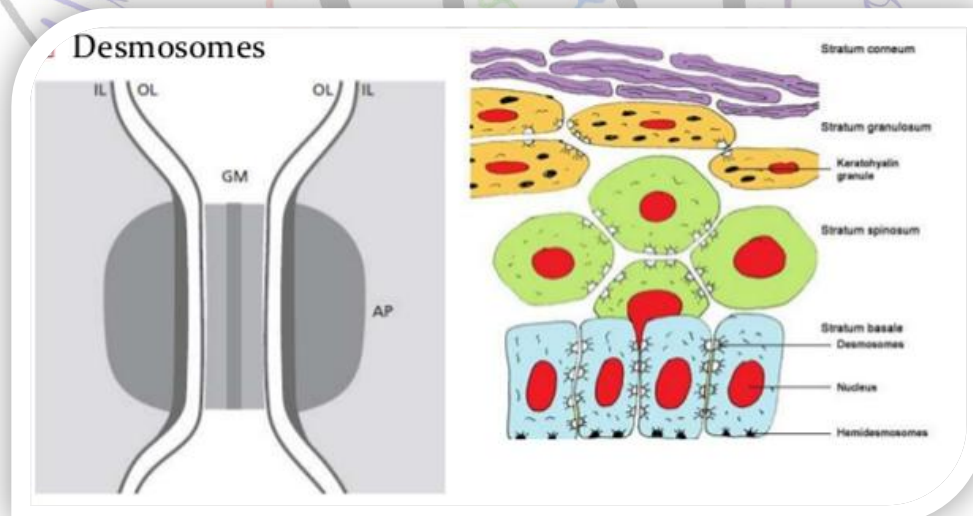
1. **Keratinocytes cell:** it is the principal cell type of oral epithelium comprises about 90% of the total cell population, responsible for the production of keratin which contributes to the protective function of the epithelium. These cells undergo continuous proliferation and differentiation from basal cell to the surface of epithelium. It takes about 3-4 weeks for the keratinocyte to reach the outer surface where it becomes desquamated from stratum corneum.

2. **Melanocyte cells:** responsible for the production of melanin pigment and can be found in the basal cell layer.
3. **Langerhans cell:** they play a role in defense mechanism of the oral epithelium. They have an immunological function by recognizing and processing antigens.
4. **Merkel cells:** they are located in the deeper layers of epithelium, they have nerve ending and have been identified as tactile receptors.

The epithelial cells are joined together by structure known as **desmosome**, which is composed of **two hemidesmosomes** separated from each other by granulated material (GM)

Each **hemidesmosome** is composed from:

- **The outer leaflets (OL):** of cell membrane of two adjoining cells.
- **The inner leaflet (IL):** is the thicker leaflet of cell membrane.
- **The attachment plaque (AP):** which represent granular and fibrillar material in the cytoplasm.



The sulcular epithelium: It lines the gingival sulcus and is thin; **non-keratinized** stratified squamous epithelium **without** rete pegs. It extends from the coronal limit of the junctional epithelium to the crest of the gingival margin. Although it contains Keratinocytes they do not undergo Keratinization. Partial Keratinization may occur in response to physical stimulation.

The sulcular epithelium is extremely important because it may act as a **semi permeable** membrane through which injurious bacterial products pass into the gingival and tissue fluid from the gingiva seeps into the sulcus.

The junctional epithelium (JE): The epithelium that attaches the gingiva to the surface of the tooth. It forms the base of the sulcus.

The junctional epithelium is attached to the tooth surface by internal basal lamina and hemidesmosome and to the gingival connective tissue by external basal lamina and hemidesmosome.

The attachment of the JE to the tooth is reinforced by the gingival fibers; hence, the JE and the gingival fibers are considered a functional unit, referred to as the **dentogingival unit**.

The JE consists of a collar like band of stratified squamous non keratinized epithelium. Thickness varies from 2-3 Layers in early life and increases with age up to 15-20 layers at the base of the gingival sulcus. The length of junctional epithelium ranges from 0.25 to 1.35mm. The cells are arranged in basal and suprabasal layer.

The JE assumes a key role in maintenance of periodontal health, it creates the firm epithelial attachment that connects the soft tissue

to the tooth surface. It is quite permeable and thus serves as a pathway for diffusion of the bacterial plaque products to the connective tissue. There is also a diffusion of host defense substances in the opposite direction moving towards the sulcus.

Differences between the three types of gingival epithelium:

- The **size** of the cells in the junctional epithelium is relatively larger than the oral epithelium.
- The **intercellular spaces** are wider in the junctional epithelium than the oral epithelium.
- The number of **desmosome** is fewer in the junctional epithelium than the oral epithelium, this could explain the JE susceptibility to tear during probing and its greater permeability to migrate cells and fluids.
- **No Keratinization**, a **no** rete pegs in the sulcular and junctional epithelium, so they are thinner than oral epithelium.
- **Turnover rate** is very high in junctional epithelium (4-6 days) compared to oral epithelium (6-12 days or up to 40 days).
- Junctional epithelium forms the **attachment** of the gingiva to the tooth surface while oral and sulcular epithelium have no attachment to tooth surface.

Epithelial connective tissue interface:

Basement membrane forms a continuous sheet that connects the epithelium and connective tissue. Electron microscope reveals a faintly

fibrillar structure, called as the basal lamina which is a part of the basement membrane. This structure has

- Lamina lucida adjacent to the basal epithelial cell.
- Lamina densa which is located beneath the lamina lucida from this structure and there are anchoring fibrils that project into the connective tissue.

The gingival connective tissue (CT)

The connective tissue supporting the oral epithelium is termed as *lamina propria* and can be divided into two layers:

- The superficial papillary layer: This has papillary projections between the epithelial rete pegs.
- The deep reticular layer: that lies between the papillary layer and the underlying structures.

The lamina propria consists of *cells, fibers, blood* vessels embedded in amorphous *ground* substances.

Cells of the connective tissue:

- **Fibroblast**: the most predominant cells of the CT (65%). They synthesize collagen, elastic fibers and the connective tissue matrix, and they regulate collagen degradation.
- **Mast cells**: it is responsible for the production of certain components of the matrix, and they produce vasoactive substances which may control the flow of blood through the tissue.

- **Macrophages:** They have a phagocytic action and involved in the defense mechanism.
- **Inflammatory cells:** they have different immunological functions such as polymorphonuclear leukocytes, lymphocytes and plasma cells.

The connective tissue fibers: which are formed by the fibroblasts cells

- **Collagen** fibers: which is the most predominant type of fibers
- **Reticulin** fibers
- **Oxytalan** fibers
- **Elastin** fibers

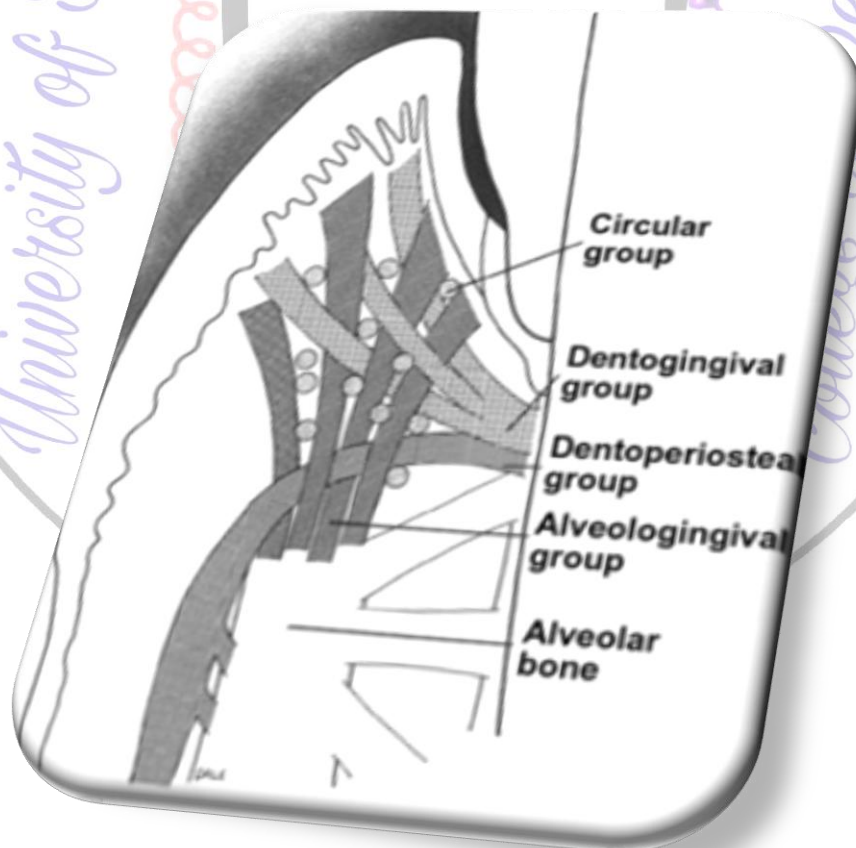
The functions of gingival fibers:

1. It braces the marginal gingiva firmly against the tooth.
2. It helps to withstand the forces exerted by mastication.
3. It unites the free gingiva to the root cementum and the adjacent attached gingiva.

The arrangement of the gingival fibers is described as **principal** group fibers which are:

1. **Dentogingival fibers:** they project from the cementum in a fan-like conformation towards the crest and outer surface of the marginal gingiva. They provide support to the gingiva by attaching it to the tooth.
2. **Alveolar gingival fibers:** they extend from the periosteum of the alveolar crest coronally into the lamina propria. Their function is to attach the gingiva to the alveolar bone.

3. **Dentoperiosteal fibers:** they arise from the cementum near the cemento-enamel junction and insert into the periosteum of the alveolar bone and protect the periodontal ligament.
4. **Circular fibers:** they surround the tooth in a cuff or ring like fashion and course through the connective tissue of the marginal and attached gingiva.
5. **Trans-septal fibers:** they are located interproximally, they extend from cementum of one tooth to the cementum of neighbouring tooth. They protect the interproximal bone and maintain tooth to tooth contact.



Connective tissue ground substances:

It is produced by fibroblast, followed by mast cells and other components derived from the blood. The matrix is the medium in which the connective tissue cells are embedded and is essential for the maintenance of the normal function of the connective tissue. Thus, the transportation of water, electrolytes, nutrients, metabolites etc.. to and from the individual connective tissue cells occurs within the matrix.

The main constituents are proteoglycans and glycoproteins.

Blood supply and nerves:

Gingival tissue has rich vascular supply from internal maxillary artery.

Blood supply is from:

- Supraperiosteal arteriols.
- Vessels of periodontal ligaments.
- Arterioles emerging from the crest of the Interdental septa.

Nerve supply is derived from the terminal branches of the maxillary and mandibular branches of the trigeminal nerve.

Clinical descriptive criteria of clinically healthy gingiva and inflamed one:

1. *Gingival color:*

The normal color of gingiva is *coral pink* with some variations depending on:

- The amount of *melanin* in the tissues.
- The *thickness* of the epithelium.
- The degree of the *Keratinization*.
- The *vascularity* of the connective tissue.

Dark skinned people often exhibit dark blue or brown color. Melanin, a non-hemoglobin-derived brown pigment, is responsible for the normal pigmentation of the skin, gingiva and remainder of the oral mucous membrane. It is present in all normal individuals, often not in sufficient quantities to be detected clinically but in black individuals it is prominent in the oral cavity.

The color of inflamed gingiva may vary from *red* to *bluish red* due to vasodilatation which leads to bleeding tendency.

2. Gingival contour.

The gingiva usually ends coronally in *knife* edged margins and *scalloped* in contour. In inflamed gingiva, the contours are often rounded and enlarged because of vascular stagnation and increases formation of collagen fibers.

3. Gingival consistency.

The gingiva is usually *resilient*, *firm* and *bound* down to the underlying bone because of the dense collagenous nature of the gingival connective tissue.

In inflamed gingiva, the consistency may be *soft* and *spongy* because of the vascular stagnation and decrease in the amount of gingival collagen fibers or *extremely firm* because of excessive formation of collagen (fibrosis), this is in case of chronic inflammation.

4. Gingival surface texture:

Gingiva may have either *stippled* or *smooth* and *shiny* surface, the attached gingiva is stippled, while the free gingiva is smooth. In inflamed gingiva, reduction or lack of stippling is not an indicator of health nor is the absence of stippling an indicator of disease .Hence, stippling frequently begins to disappear in old age.

5. Size:

The size of the gingiva corresponds with the sum total of the bulk of cellular and intercellular elements and their vascular supply.

Alteration in size is a common feature of gingival disease.

