

## *Orthodontics*

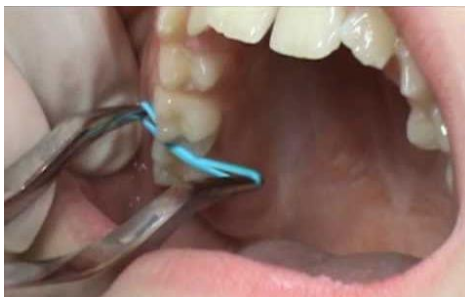### *Iatrogenic effect of tooth movement*

Orthodontic treatment have an adverse effects associated with the treatment like other fields in dentistry. These effects can be related to the patient or practitioner.

- 1) Pain.
- 2) Periodontal disease.
- 3) Pulp effect.
- 4) Root resorption.
- 5) Decalcification and associated caries.
- 6) Temporal mandibular disorders.

#### **1) Pain associated with orthodontic treatment:**

Pain and discomfort is a common adverse effect associated with orthodontic treatment. 70–95% of orthodontic patients experience pain. This pain could be a reason for discontinuing treatment in some cases; the pain and discomfort associated with orthodontic treatment is characterized by pressure, tension, or soreness of the teeth. Pain in the anterior teeth is greater than the posterior teeth. Pain has been reported to begin 4 h after the placement of separators or orthodontic wire, and the worst pain was found to occur on the second day of treatment. Usually, pain lasts for seven days.



Management of pain should include informing the patient of the possibility of experiencing pain to reduce anxiety. Furthermore, the clinician can ask the patient to chew on plastic wafers or chewing gums containing aspirin.

Additionally, clinicians are recommended to prescribe Ibuprofen or acetaminophen analgesics preoperatively and for a short duration after the placement of separators and initial wires.

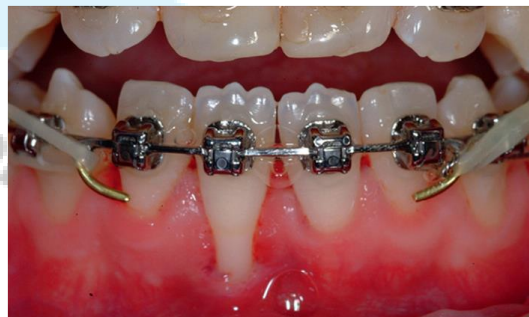## 2) **Periodontal disease and orthodontic treatment:**

Periodontal disease includes gingivitis, alveolar bone loss (periodontitis), and loss of attached gingival support.

The periodontal reaction toward orthodontic appliances depends on multiple factors, such as host resistance, the presence of systemic conditions, the amount and composition of dental plaque, smoking and the negative effects of uncontrolled diabetes.

Bacteria present in dental plaque are the primary causative agent of periodontal disease. Orthodontic treatment with fixed appliances is known to induce an increase in the volume of dental plaque.

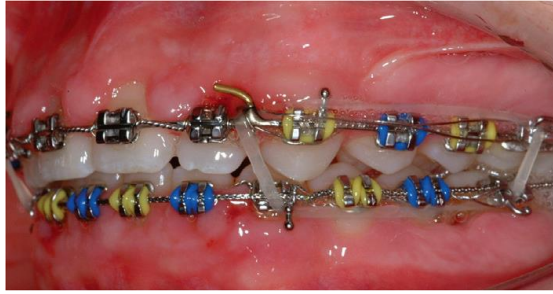
Therefore, fixed orthodontic treatment may result in localized gingivitis, which rarely progresses to periodontitis.



**Recession of a lower incisor following proclination during orthodontic treatment.**

Therefore, oral hygiene instructions should be given before the initiation of orthodontic treatment and reinforced during every visit. Regularly brushing the teeth is the first line of defense in controlling dental plaque in addition to the use of an interproximal brush.

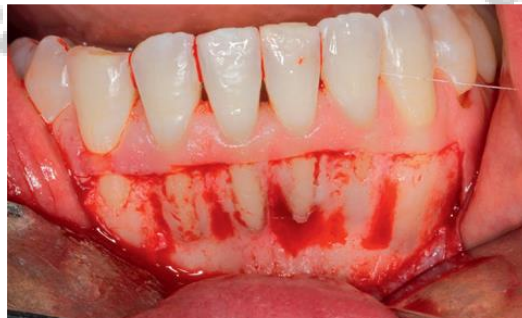Orthodontic treatment of patients with active periodontal disease is contraindicated as the risk for further periodontal breakdown is markedly increased. And the treatment of uncontrolled diabetic individuals is contraindicated also.



**Gingival hyperplasia during orthodontic treatment**

### **3) Pulpal changes during orthodontic treatment:**

Although pulpal reactions to orthodontic treatment are minimal, there is probably transient inflammatory response within the pulp, at least at the beginning of treatment. This may contribute to the discomfort that patients often experience for a few days after appliances are placed. The possibility of pulp vitality loss during orthodontic treatment does exist. The risk factors for loss of pulp vitality include a history of trauma associated with the teeth. Pre-treatment periapical radiographs of previously traumatized teeth are essential for comparative purposes. Additionally, the use of heavy uncontrolled, continuous forces by the orthodontist or round tripping of the teeth may lead to loss of pulp vitality since root apex may be moved outside the alveolar process. Therefore, orthodontist should use optimal light forces during their treatment.



### **4) Root resorption:**

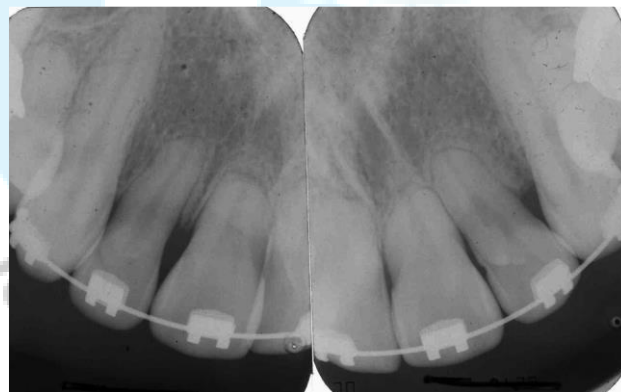Limited root resorption involving a number of teeth can be considered as consequence of orthodontic treatment.

The factors which may be contributing in root disease are hormonal disturbance, dietary deficiency, Periodontal disease and orthodontic treatment variables like duration of treatment. The genetic predisposition

makes root resorption associated with orthodontic treatment more predictable.

The risk for root resorption increases with the length of treatment. Treatment of impacted canines can extend treatment time and increase risk for root resorption. Thin, tapered, and dilacerated root morphology, results in roots that are more prone to resorption (ex. maxillary lateral incisor). Additionally, history of trauma associated with the anterior teeth increases the risk for root resorption.

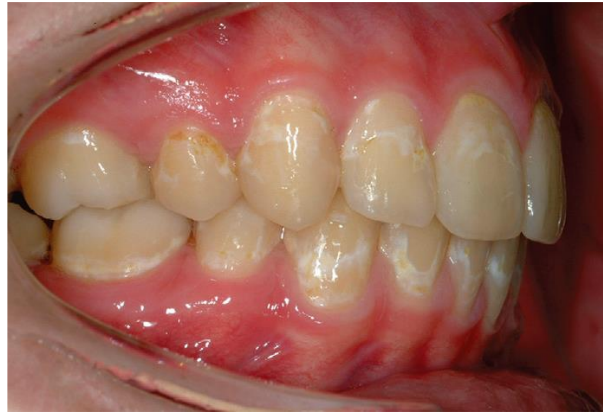Assessment of the condition through a progress radiograph at 6–12 months after the initiation of orthodontic treatment is recommended. These could be either periapical or panoramic radiographs. The patient must be informed that if root resorption is observed, then active treatment must be stopped for at least 3 months. The reparative process of root resorption begins two weeks after active treatment is stopped. At this stage, an alternative treatment plan should be considered and treatment should be discontinued when severe root resorption is observed.



Severe root resorption during orthodontic treatment

##### **5) Decalcification and caries associated with orthodontic treatment:**

Decalcification of enamel (*white spots*) is a common adverse effect of orthodontic treatment. Decalcification is considered to be the first step toward cavitation. Decalcification of enamel occurs in 50% of orthodontic patients and the most affected teeth are the maxillary incisors. Additionally, these lesions can develop within four weeks, which is the typical time span for orthodontic follow-up.

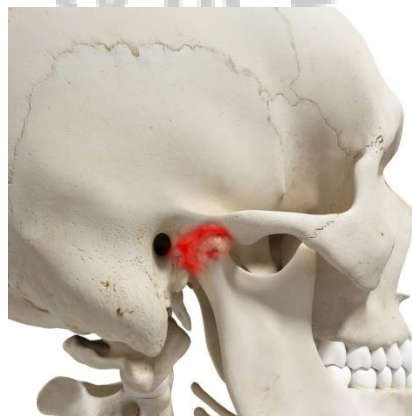

**Generalized demineralization following orthodontic treatment with fixed appliances.**

The prevention protocol for decalcification includes plaque control through brushing of the teeth with fluoridated tooth paste. Daily rinsing with a 0.02% or 0.05% sodium fluoride solution can also minimize decalcification of enamel. Additionally, fluoridated solutions may delay the progression of lesions. Application of fluoride varnish twice a year or a combination of antibacterial and fluoride varnish may reduce the incidence of decalcification.

#### **6) TMD and orthodontic treatment:**

TMD is a condition that can include masticatory muscle pain, internal derangement of the temporomandibular joint (TMJ) disc, and degenerative TMJ disorders as separate problems or can be a combination.



The etiology of TMD is complex and cannot be explained on a cause-and-effect basis. Malocclusion may be considered in some cases as a contributing factor, but it is not the only etiological factor.



Orthodontic treatment during adolescence does not increase the risk for TMD, and it should not be started in patients with acute signs and symptoms of TMD. The orthodontic treatment should be postponed after the attack is controlled.

If the patient develops signs and symptoms during the orthodontic treatment, then all active forces must be discontinued without the need for the removal of the fixed orthodontic appliances. Then, the signs and symptoms of TMD must be controlled using a conservative approach. Once the signs and symptoms are under control, then the practitioner must reevaluate the objectives of treatment. In some cases, the orthodontic treatment must be terminated if the signs and symptoms cannot be controlled.

### **Accelerated tooth movement:**

Methods to accelerate orthodontic tooth movement can be broadly studied under the following categories:

1. Drugs.
2. Surgical Methods.
3. Physical/ Mechanical stimulation methods.

#### **I. Drugs:**

Various drugs have been used since long to accelerate orthodontic tooth movement, and have achieved successful results. These include vitamin D, prostaglandin, interleukins, parathyroid hormone, misoprostol etc. But, all of these drugs have some or the other unwanted adverse effect, and as of today, no drug exists that can safely accelerate orthodontic tooth movement.

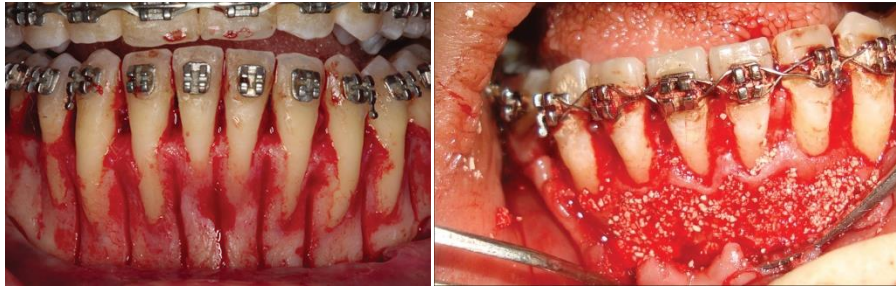#### **II. Surgical Methods:**

The various surgical methods available are:

##### **1. Corticotomy:**

The conventional corticotomy procedure involves elevation of full thickness mucoperiosteal flaps, buccally and/or lingually, followed by placing the corticotomy cuts using either micromotor under irrigation, or

piezosurgical instruments. This can be followed by placement of a graft material, wherever required, to augment thickness of bone.



Advantages:

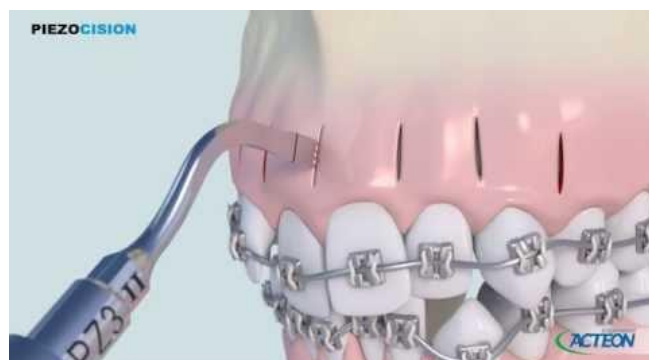
- a. It has been proven successfully by many authors, to accelerate tooth movement.
- b. Bone can be augmented, thereby preventing periodontal defects, which might arise, as a result of thin alveolar bone.

Disadvantages:

- a. High morbidity associated with the procedure.
- b. Invasive procedure.
- c. Chances of damage to adjacent vital structures.
- d. Post-operative pain, swelling, chances of infection, avascular necrosis.
- e. Low acceptance by the patient.

**2. Piezocision:**

The surgery was performed 1 week after placement of orthodontic appliance, under local anaesthesia. Gingival vertical incisions, only buccally, were made below the interdental papilla, as far as possible, in the attached gingiva using a No.15 scalpel. These incisions need to be deep enough so as to pass through the periosteum, and contact the cortical bone. No suturing is required, except for the areas, where the graft material needs to be stabilized. Patient is placed on an antibiotic, mouthwash regimen.



### Advantages

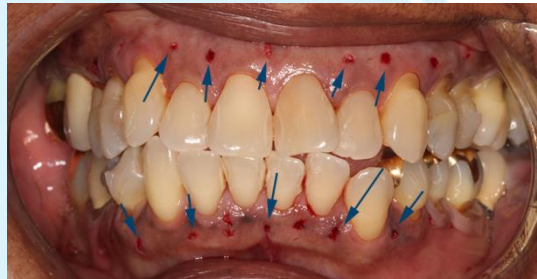- a. Minimally invasive.
- b. Better patient acceptance.

### Disadvantages

Risk of root damage, as incisions and corticotomies are “blindly” done.

### **3. Micro-Osteoperforations (MOP):**

This based on microperforation in which screw like those used for skeletal anchorage is placed through the gingiva into interproximal alveolar bone and then removed. It is said that 3 such perforations in each interproximal area are enough to generate a regional acceleration of bone remodeling, and thereby produce faster tooth movement.



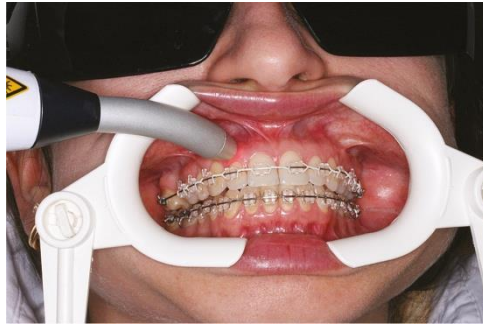
### **III. Physical/Mechanical Stimulation:**

Surgical methods, regardless of technique, are still invasive to some degree, and hence have their associated complications. Hence, non-invasive methods have come to the fore. These modalities include lasers, vibration, direct electric current etc.

#### **1. Laser:**

In the last decade, many histological studies have attempted to determine the effect of low-intensity laser therapy on the histochemical pathways directly associated with orthodontic tooth movement. Increased osteoblastic and osteoclastic activity after low-level laser therapy was observed. The variations amongst the studies seem to arise from variations in frequency of application of laser, intensity of laser, and method of force application on the tooth.

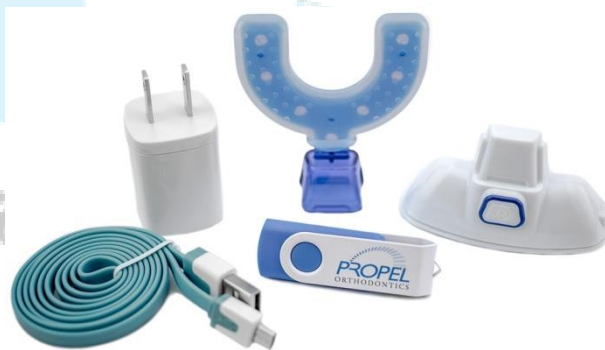



## **2. Vibration:**


This device consists of an activator, which is the active part of the appliance that delivers the vibration impulses with a USB interface through which it can be connected to a computer to review the patient usage of the appliance, a mouthpiece that contacts the teeth.

It is a portable device that can be charged similar to any other electronic device; it is based on delivery of high-frequency vibration (30 Hz) to the teeth for approximately 20 minutes per day. Various case studies using this device have shown the treatment times to be reduced by up to 30-40%.



## **3. Tissue-Penetrating Light:**

It provides light with an 800- to 850-nanometer wave length (just above the visible spectrum) adjacent to the alveolar bone. Light in this spectrum does penetrate soft tissue, and the idea is that it “infuses light energy directly into the bone tissue”. This is said to excite intracellular enzymes and increase cellular activity in the PDL and bone, increasing the rate of bone remodeling and tooth movement.



The intraoral device delivers light at an infrared frequency that penetrates the soft tissue over the alveolar bone

#### 4. Therapeutic Ultrasound:

It is known that therapeutic ultrasound (which is different from diagnostic ultrasound) increases blood flow in treated areas. The theory is that increased blood flow in the PDL would increase the rate of bone remodeling and tooth movement and also could decrease root resorption.

