

## Informed consent

Informed consent: means the patient is given information to help them to understand the:

- Malocclusion
- Proposed treatment and alternatives
- Commitment required
- Duration of treatment
- Cost implications

Treatment alternatives, which must always include no treatment as an option, must be clearly explained, with the risks and benefits of each approach carefully discussed.

Patients who are 16 years or older are presumed to have competence to give consent for themselves. Many orthodontic patients are younger than this, but provided that they fully understand the process, they can give consent. If a competent child consents to treatment, a parent cannot override this decision – this is known as ‘Gillick competence’.

However, it is preferable to have full parental support for the treatment if possible. If the converse occurs – the parent wants the treatment, but the child does not – then it is best not to proceed. Orthodontic treatment requires a great deal of compliance, and unless the patient is totally committed, it is best to delay until such time as they are.

It is advisable to obtain a written consent for the treatment. A copy should be given to the patient with clear details of the:

- 1- Aims of the treatment,
- 2- Risks and benefits,
- 3- Types of appliances to be used,
- 4- Details of any teeth to be extracted,
- 5- Commitment required,
- 6- Likely duration of treatment

Note: When estimating treatment time, it is always better to slightly overestimate the likely treatment duration. If the treatment is completed quicker than first promised, the patient will be pleased. However, if the treatment takes longer, the patient may lose interest, resulting in compliance problems.

- 7- Any financial implications,
- 8- As well as long-term retention requirements.

As well as providing a written record of the aims of the treatment and the treatment plan, it is useful to give the patient a summary of exactly what is expected from them, this involves information about:

- 1- Maintenance of good oral hygiene
- 2- Appropriate diet and regular attendance.
- 3- Also any specific requirements relevant to their case, such as headgear wear, turning expansion screws and elastic wear.

A fully prepared and committed patient is more likely to result in more successful orthodontic treatment.

#### **Orthodontic treatment plan phases:**

- 1- Preventive Orthodontics
- 2- Interceptive Orthodontics
- 3- Corrective Orthodontics

**Preventive Orthodontics:** Includes all those procedures undertaken to preserve the integrity of normally developing occlusion by protecting current conditions or preventing situations that would interfere with growth by the following measures:

#### **1- Parent education:**

A- Should ideally begin much before the birth of the child. The expecting mother should be educated on matters such as nutrition to provide an ideal environment for the developing fetus.

B- Soon after the birth, the mother should be educated on proper nursing and care of the child. In case the child is being bottle fed, the other is advised on the use of physiologic nipple (designed to permit suckling of milk, which more or less resembles normal functional activity as in breastfeeding) and not the conventional nipple.

C- The parents should also be educated on the need for maintaining good oral hygiene of the child's oral cavity (avoid nursing during all the night)

**3-Maintenance of shedding and eruption timetable:** The pattern and schedule of primary teeth exfoliation and subsequent eruption of permanent teeth should be closely monitored so as to intervene as and when need arises.

Generally, the deciduous teeth should exfoliate in about three months of exfoliation of their counterparts in the contralateral arch. Furthermore, the permanent succedaneous teeth should erupt within three months of exfoliation of their predecessors.

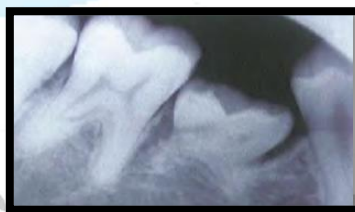**4-Management of premature loss of deciduous teeth:** Premature loss of deciduous teeth leads to the following deteriorative consequences:

- a- Migration of adjacent teeth into the space .
- b- Non-eruption or altered path of eruption of the succedaneous tooth.
- c- Tongue thrusting may develop, especially anterior teeth.
- d- Hampered phonation in the case of anterior tooth loss.
- e- Unaesthetic appearance of face. Psychological effect on the child, especially in the case of anterior tooth loss.

**To prevent that:** Space maintainers given until the eruption of succeeding permanent teeth into the oral cavity.

**5- Management of ankylosis of deciduous teeth:** Ankylosis of deciduous teeth prevents the eruption of succeeding permanent teeth.

**To prevent that:** Surgical extraction of ankylosed deciduous teeth at an appropriate time facilitates the eruption of succeeding permanent teeth. Management of prolonged retention of deciduous teeth.

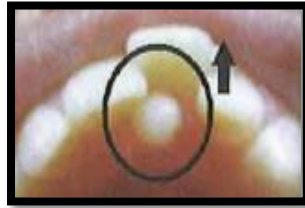


**6- Prolonged retention of deciduous teeth:** may be due to a number of reasons like ankylosis, hypothyroidism, etc. Retained deciduous teeth may lead to abnormal eruptive pathway of succeeding permanent teeth.

**To Prevent that:** Extraction of retained deciduous tooth to facilitate the eruption of underlying succedaneous tooth.

**7-Extraction of Supernumerary Teeth:** Supernumerary teeth may cause the following:

a. Crowding in the arch

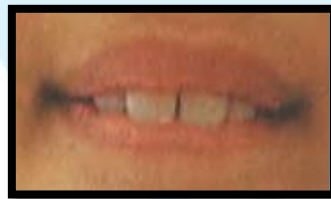

b. Prevent eruption of succeeding permanent teeth.

c. If left untreated, may cause cystic formation.

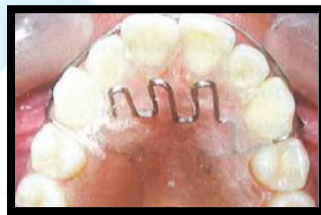**To Prevent that:** Early diagnosis and extraction of supernumerary teeth is recommended to prevent all deleterious consequences associated with supernumerary teeth.

**8- Management of Oral Habits:** Abnormal oral habits such as, thumb/digit sucking , lip biting , tongue thrusting and mouth breathing habits have deleterious effects on oral health including malocclusion and gingivitis among others.



**To Prevent That:**

- a- Education of parents about the consequences of abnormal oral habits.
- b- Educating and motivating the child to stop the habit.
- c- Elimination of oral habits using habit breaking appliances.

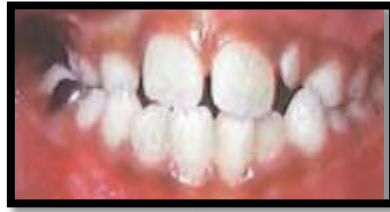

**9-Management of deeply locked first permanent molars:**

Occasionally, the first permanent molar may get deeply locked under the crest of contour of the distal surface of deciduous second molar due to distal inclination of the latter tooth.

**To Prevent that:** Re approximation /proximal stripping to a certain extent on mesial and distal surface of second deciduous molar will guide the eruption of deeply locked first permanent molar.

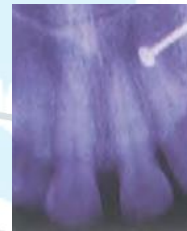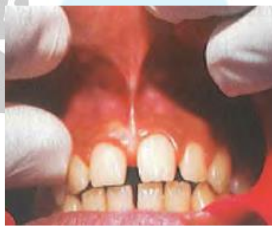**10-Treatment of Occlusal Prematurities:** Occlusal prematurities due to over or underfilled restoration or uneven attrition of teeth causes a tendency of forward placement of mandible. This may lead to pseudo class III malocclusion.



**To Prevent that:**

- a-Correcting the improper restoration.
- b-Treatment of attrition by composite restoration.

**11-Management of Abnormal Frenum Attachment:** Abnormal frenum attachment may cause midline diastema, which can be diagnosed clinically by Blanch test and radiographically by presence of a notch like radiolucency in the alveolar crest between permanent maxillary central incisors.



**To Prevent that:** Surgical removal of abnormal fibrous tissue of the labial frenum is referred as Frenectomy.

**12- Space maintainers:** Whenever primary teeth are lost prematurely, the arch integrity is disturbed due to loss of space and decrease in arch length. Migration of adjacent primary and/or permanent teeth can occur and the available space may be reduced by an amount sufficient to cause some degree of crowding in the permanent dentition.

Therefore space maintainer is a fixed or removable appliance designed to preserve the space created by premature loss of a tooth or a group of teeth .

**Indications:**

- a-The premature loss of primary molars may require the placement of a space maintainer to prevent the migration of the adjacent teeth, depending upon the teeth present and the arch length.

b-When loss of a primary canine occurs, the dental arch midline may be compromised and the arch length also may be reduced. The premature loss of primary canines may therefore require the placement of a space maintaining appliance to prevent midline deviation and/or loss of arch length.

c-The premature loss of primary incisors does not usually require the placement of a dental appliance for the maintenance of space because the mesial movement of the adjacent teeth is not generally expected.

### **Contraindications**

a- A space maintainer is usually not necessary, if there is sufficient amount of space present to allow for the eruption of permanent tooth/teeth.

b-A space maintainer may not be recommended, if severe crowding exists, such that space maintenance is of minimal effect and subsequent orthodontic intervention is indicated.

c-A space maintainer may not be necessary, if the succedaneous tooth will be erupting soon.

e-When succedaneous tooth is absent.

### **Interceptive Orthodontics:**

Interceptive orthodontics is undertaken at a time when malocclusion has already developed or developing. The difference between preventive and interceptive orthodontics lies in the timing of the services rendered. Preventive orthodontic procedures are undertaken when the dentition and occlusion are perfectly normal, while the interceptive procedures are carried out when signs and symptoms of a developing malocclusion are evident.

Interceptive orthodontic procedures may include:

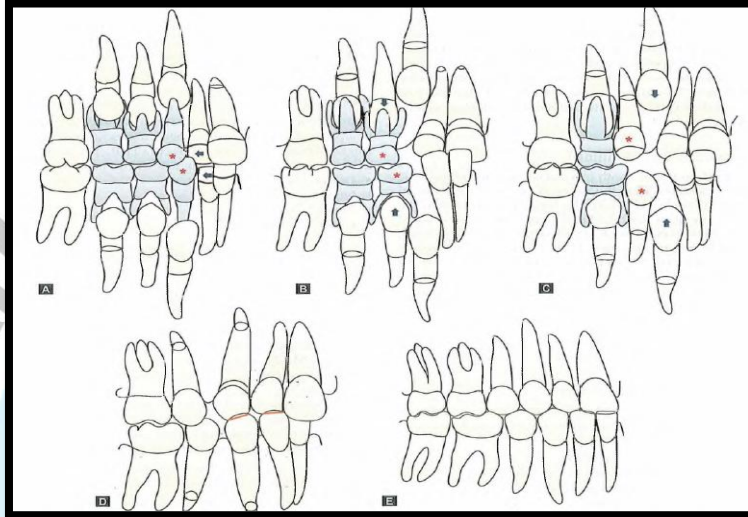
1-Serial extraction/guidance of occlusion: Serial extraction is an interceptive orthodontic procedure undertaken in the (early) mixed dentition period that involves planned removal of certain primary and permanent teeth in a programmed sequence, so as to relieve crowding in the arches and to guide the remaining erupting permanent teeth into a more favorable position.

The procedure includes multiple teeth extractions (Cs,Ds,Es then 4s) in special timing sequence between age of 8-10 years, When executed properly in carefully selected patients with the proper assessment can produce the best possible and the most stable results with minimal or in some cases no further need of corrective mechanotherapy at a later stage when all permanent teeth erupts.

### Indications

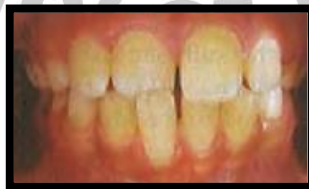Serial extraction procedure is primarily indicated in developing class I malocclusions with moderate to severe arch length-tooth material discrepancy with resultant crowding of teeth. Serial extraction gives best results in patients with ideal orthognathic profile and in whom all the components of stomatognathic system (i.e. neuromuscular envelop, basal jaw bones, and teeth) are in balance with good facial harmony.

(Details will be discussed later on).



**2-Correction of developing cross-bites:** Occasionally, even with adequate arch-length, the maxillary lateral incisors erupt too far palatally and their crowns are forced completely to the palatal side of the crown of the opposing mandibular incisors as the maxillary and the mandibular teeth are brought into habitual occlusion

Anterior crossbite should be intercepted and treated at an early stage so as to prevent future severe dentofacial abnormality. If the condition is left untreated it may develop into severe skeletal malocclusion (e.g. CI III), which requires invasive orthodontic treatment. Therefore, it is desirable to intercept and treat the crossbite, as soon as it is recognized.



**3-Control of abnormal oral habits:** Correction of deleterious oral habits, such as:

- a-Thumb sucking
- b- tongue thrusting

### c- Mouth breathing

Should be undertaken as a part of interceptive orthodontic procedure. Not all oral habits damage the dentoalveolar structures and thus, do not require orthodontic interventions. If definite damage due to any oral habits exists, then thorough case history should be recorded.

The optimal time for appliances placement is between the age of 3.5 – 4.5 years. The oral habits can be intercepted by either removable or fixed orthodontic appliances, with crib.

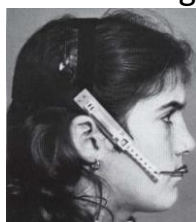**4-Proximal stripping of deciduous teeth to facilitate the eruption of adjacent permanent teeth:** Proximal stripping of first or second deciduous molars often require to facilitate the eruption of adjacent succedaneous permanent teeth into normal occlusion, e.g.,

- a- Proximal stripping of mesial surface of mandibular deciduous first molar can be of help in preventing mandibular anterior crowding
- b- When there is lack of space for maxillary canine to erupt, then space can be created by disking of second deciduous molar, which leads to distal drifting of the first premolar creating space for the canine to erupt.

**5-Correction of occlusal interferences:** Occlusal interferences present during the development of occlusion can deflect the mandible anteriorly, laterally or posteriorly. Once occlusal prematurities are identified by using articulating paper, they are corrected by the reduction of crown height using pearshaped stone in a center-angled handpiece. Occasionally, a lingually placed tooth particularly a maxillary lateral incisor or cuspid can deflect the mandible either anteriorly or posteriorly resulting in crossbite. In such situations, the interferences cannot be corrected by occlusal reduction, therefore orthodontic appliances will help in correcting the malocclusion by eliminating the interference.

### 6-Interception of skeletal malrelations:

A-Interception of Class II Malocclusion: Class II malocclusion due to maxillary excessive growth can be intercepted by restricting the maxillary growth by the use of face bow with head gear.



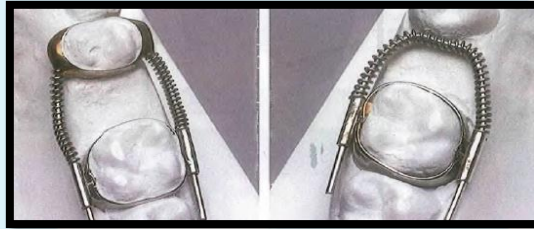


Class II malocclusion due to mandible insufficiency can be intercepted by the use of myofunctional appliances.

Interception of Class III Malocclusion: Class III malocclusion due to mandibular prognathism can be intercepted by restricting the mandibular growth by use of chin cup.

Class III malocclusion due to maxillary deficiency can be intercepted by the use of myofunctional appliances or orthopedic appliance (reversed head gear).

**7- Space regaining:** Space lost usually by the mesial drifting of permanent molar and distal drifting of deciduous first molar when second deciduous molar is lost prematurely or by drifting of teeth adjacent to impacted tooth, therefore it is recommended to re-open the space by different designs of orthodontic appliances.



### 9-Muscle exercises:

Dentoalveolar structures are surrounded on sides by the soft tissue envelop made of orofacial musculature.

Development and maintenance of normal occlusion depends on presence of normal oro-facial muscular balance. Muscle exercises help in improving aberrant muscle activity.

### Exercises for the Lips (Circumoral Musculatures):

A number of exercises have been advocated for the lips and circumoral musculature in patients with hypotonic lips and short upper lips:

A-Stretching of the upper lip to maintain lip seal is an important therapeutic measure in patients having short hypotonic lips. To aid in the stretching, the patient is asked to hold a piece of paper between the lips.

B-Patient can be asked to stretch the upper lip interiorly towards the chin.

C-Lip massaging.

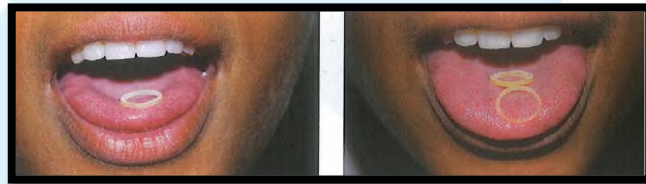D-*Button Pull Exercise:* A button of one and half inch is taken and a thread passed through the button hole. Patient is asked to place the button behind the lips and pull the thread, while restricting it from being pulled out by using lip pressure.

E- *Tug of War Exercise*:- This involves use of two buttons, with one kept behind the lips while the other button is held by another person to pull the thread.

F- *Playing a Reed Musical Instrument*:- Playing a reed musical instrument produces fine lip tonicity.

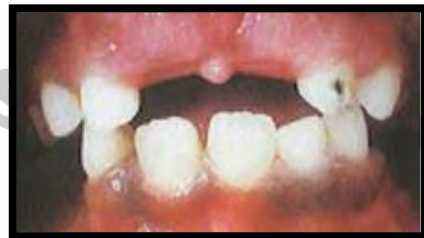### Exercise for Tongue:

- a- *One Elastic Swallow*: Used for Correction of positioning of the tongue when the Patient is asked to keep elastic of 5/16" on the tip of tongue and hold the tongue against the patient's rugae area and swallow .
- b- *Two Elastic Swallow*: Two elastics of 5/16", are replaced over the tongue, one in the midline and the other on the tip and the patient is asked to swallow with the elastic in position .



**10-Removal of soft tissue and bony barriers:** Removal of soft tissue and bony barrier is a surgical interceptive orthodontic procedure, which involves excision of the soft tissue and removal of bone, covering the crown of the unerupted tooth, to create the space so that the tooth can erupt without any hindrance.

The extent of soft tissue and bone removal should be such that the greatest diameter of the crown of the tooth should be able to easily emerge. The surgical wound is given a cement dressing for a period of two weeks.



**Corrective Orthodontics:** Will be discussed later in details