

Partial Veneer Crown(Three quarter crown)

It is a cast metal crown restoration that cover only a part of the clinical crown, most commonly used type of partial veneer crown is $\frac{3}{4}$ (three quarter) crown.

Three quarter ($\frac{3}{4}$) crown:

It is a cast metal crown restoration that cover three quarter of crown (occlusal or incisal, palatal or lingual and proximal) leaving the labial or buccal surface unprepared, it tend to be less retentive and resistance than full veneer crown .It can be used for anterior or posterior teeth. It can be used as single restoration or as a retainer for short span bridge.

Uses:

1. As a retainer for short span bridge.
2. As a single restoration.
3. As a splint in anterior teeth.

Indications***---- For posterior teeth;***

1. Lost moderate amount of tooth structure with intact and well supported buccal surface.
2. Retainer for fixed partial denture.

----- For anterior teeth;

1. Suitable for teeth with a sufficient bulk and intact labial surface.
2. Retainer for F.P.D. or splinting of anterior teeth.

Contraindication:

1. Short clinical crown.
2. High carries index.
3. Extensive destruction
4. Poor alignment.
5. Thin teeth
6. Long span bridge.
7. Non-vital teeth.

Advantages of $\frac{3}{4}$ crown:

- 1- Conservative of tooth structure.
- 2- Easy access of margins.
- 3- Less gingival irritation than complete crown.
- 4- Easy escape of cement and good seating.
- 5- Electrical pulp test is possible.
- 6- Complete seating of the crown can be easily seen by direct observation.

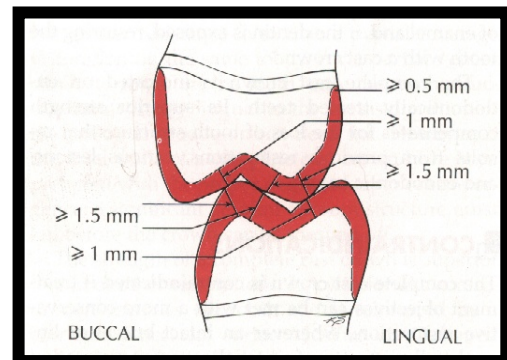
Disadvantages:

- 1-Difficult in preparation compared to other types of crown restorations.
- 2- Possibility of recurrent caries more along the cavo-surface line angle.
- 3- Possibility of showing metal especially in the lower anterior & posterior teeth.
- 4-Less retention and resistance than complete cast crown.
- 5-Limited adjustment can be done in the path of withdrawal.

Tooth Preparation (PJC)

Recommended dimensions

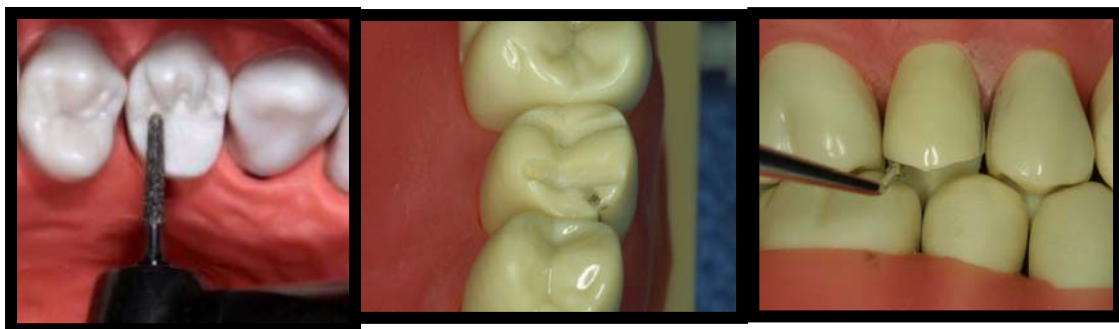- 1.5 mm on functional cusp (lingual)
- 1.0 mm on non-functional cusp (facial)
- Less than 0.5 mm on facial cusp tip if sufficient horizontal overlap
- 1.5 mm clearance
- Follow contours of opposing tooth
- Maintain contours of tooth being prepared
- Extend bevel into lingual embrasure



Steps in preparation on maxillary posterior teeth ;

1.Occlusal surface preparation

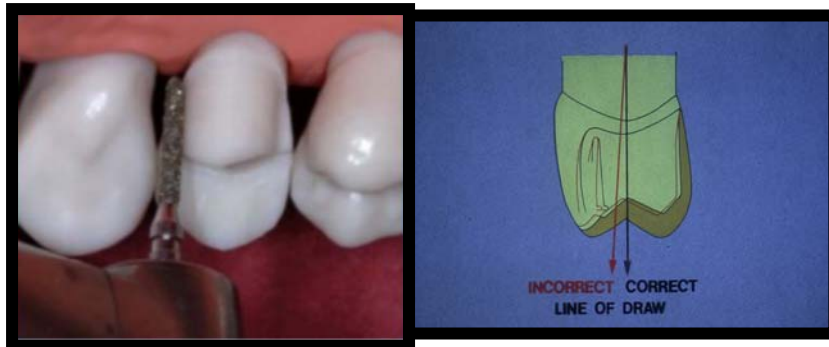1. D.O.G. placed on the anatomic ridge and grooves of occlusal surface using round end taper fissure bur, the grooves should extend through occluso-buccal line angle but only with 0.5mm deep to prevent metal display.
- 2.Occlusal reduction were then complete by removing tooth structure between grooves reproducing the geometric inclined plan pattern of cusps, the depth of reduction should be decrease at the OB line angle.
- 3.Awide bevel is placed on the functional cusps using the same bur .
- 4.Occlusal clearance were then check in centric & eccentric mand.relations.



2.Lingual surface preparation;

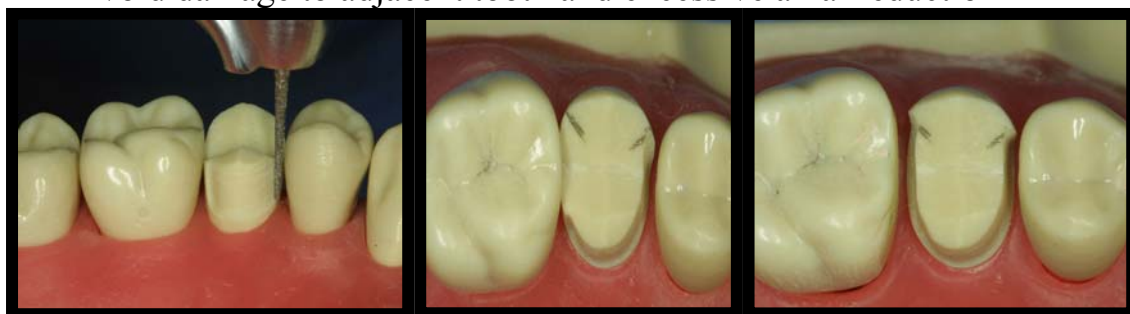It is done similar to other types of crown:

- D.O.G. are placed using the same bur, they should be placed parallel to the long axis of the tooth.
- Reaming tooth structure between grooves were then removed following the contour of the tooth holding the bur parallel to the long axis at the tooth
- A round –end tapered fissure bur is used to obtain Chamfer finish line that 0.5 mm supragingival



3.Interproximal Reduction

- Proximal access is gained by short needle diamond, up and down movement, this continue until contact with adjacent tooth is broken & access for larger bur is produced .
- extend facially and gingivally to break contact with adjacent tooth
- Proximal grooves (mesial and distal) are placed parallel to the path of withdrawal and parallel to each other using carbide fissure bur. Normally, unsupported tooth structure will remain on the buccal side, and this side is flared to remove it.
- Avoid damage to adjacent tooth and excessive axial reduction

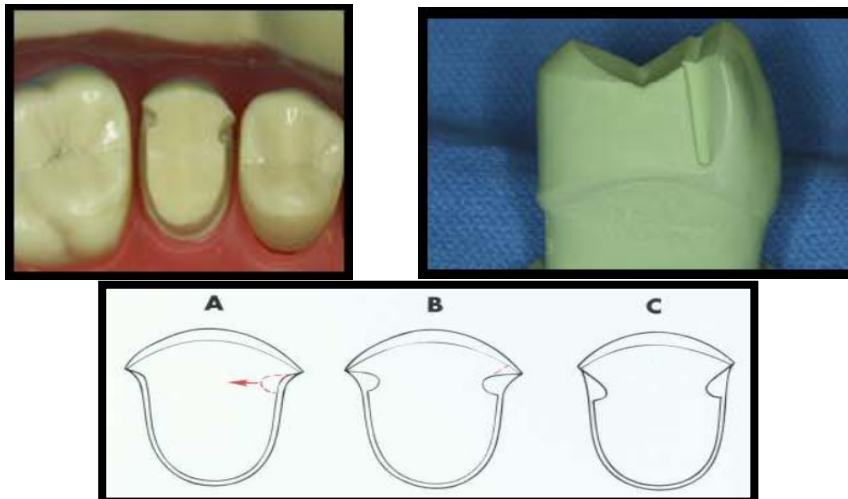


Proximal grooves:

As a part of proximal reduction& in order to improve retention feature of the preparation &as a substitution for the uncover wall, proximal grooves should be placed on each proximal wall. It should be parallel to the long axis of the tooth or path of insertion & parallel to each other. Carbide fissure bur is used to place these grooves.

-Requirements:

- 1.It should cut to full diameter of carbide bur No.171(0.5mm) to create defiant lingual wall.
- 2.It should extend to the full length of proximal wall (ending about 0.5mm to the chamfer).
- 3.It should be placed as far as facially as possible without undermining facial surface (bet. Middle &labial third).
- 4.It should be parallel to the long axis of the tooth.



Advantages of Proximal grooves;

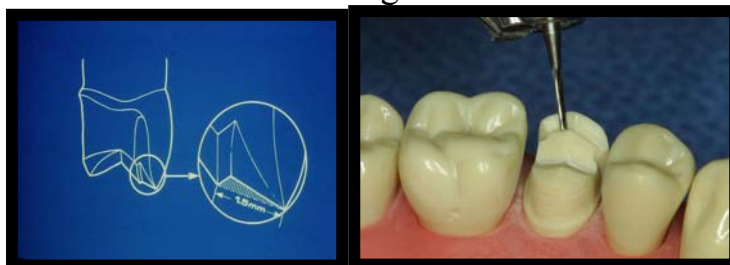
- 1.Increase retention.
2. Prevent rotation (resistance).
- 3.Reinforce the margin of restoration at this area.
- 4.They act as a guide during placement.

Occlusal offset;

1mm.wide groove made on the lingual incline of the facial cusp, it is V shape inverted lie at uniform distance from occlusal finish line.

Advantages;

1. Improve the strength of the casting.
2. Reinforce the margin of the restoration at this area.



Finishing line :

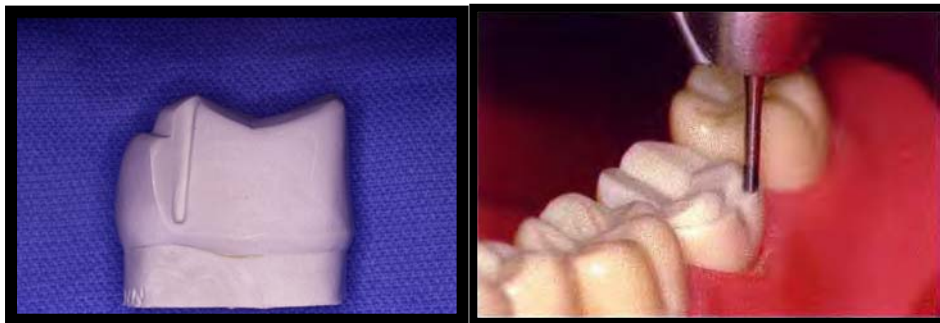
- Chamfer is used as gingival finish line on lingual &proximal surfaces
- 45 degree bevel F.L. were used on proximofacial & occlusofacial margins

Mandibular posterior 3/4 Crown

Differences between upper & lower posterior 3/4 crown preparation:

1. Big difference is the position of FL on facial surface, for max.pos. teeth it terminate near the bucco-occlusal line angle while in mand.pos. teeth the occlusal FL is 1mm. gingival to the lower occlusal contact with the upper teeth, this is because the buccal cusps in lower are the functional cusps.

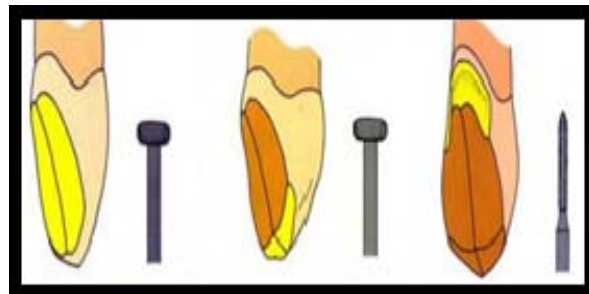
2. In upper, there should be occlusal offset however, for the lower there is no offset, in state, there is bucco-occlusal shoulder (occlusal shoulder on the buccal aspect of the buccal surface), it serve the same purpose as the offset.



3/4 Crown Maxillary Anterior

1-lingual reduction: this is done by two steps similar to other types of crowns.

- a. Cingulum area reduction;
- b. Lingual axial reduction;



2.Incisal termination:

For max. ant. teeth lingo-incisal bevel is place using diamond bur at 45° to the path of insertion, this termination should not be extended labially to prevent showing of metal, however, for lower anterior a reverse bevel is placed on the labial surface. This means that, the metal will extend to cover the incisal edge in order to;

1. Protect the area of unsupported enamel from fracture.
2. To prevent the dislodgment of the crown in lingual direction.

3.Proximal reduction:

The area is prepared similar to the full veneer crown except that the preparation should have a path of insertion parallel to the incisal 2/3 of the labial surface(not to the long axis of the tooth).

Two proximal grooves should be placed ,at the junction between the labial and middle third of the proximal surface, parallel to the incisal 2/3 of the labial surface (path of insertion) using a carbide fissure bur , **this is because;**

1. *We can place the longest groove in this direction (better retention).*
2. *to avoid over cutting to the labial surface (if we do it parallel to the long axis) that effect on esthetic.*

The mesial and distal grooves should be connected with V shape groove incisal offset. **The advantage of the incisal offset are;**

1. *improvement of the strength of casting at this area*
2. *reinforcement of margin by connecting the two proximal grooves together*

Differences between anterior and posterior teeth preparation

In the anterior teeth the retentive proximal groove should be parallel to the incisal 2/3 of the labial surface while in the posterior teeth it is parallel to long axis to get the longest groove for better retention of crown.

