

# Dental Anatomy

**Lec 9**

**Dr. Ahmed Ghazi**

## Permanent Mandibular Premolars

### Mandibular First Premolar

It is the smallest premolar in the human dentition. It resembles both the mandibular canine and the mandibular second premolar in function and has some of the characteristics of each of them.

#### *A. Characteristics that resemble those of the mandibular canine:*

1. The buccal cusp is long, sharp, and is the only occluding cusp.
2. The bucco-lingual measurement is similar to that of the mandibular canine.
3. The occlusal surface slopes sharply lingually in a cervical direction.
4. The mesio-buccal cusp ridge is shorter than the disto-buccal cusp ridge.
5. The outline form from the occlusal aspect resembles the incisal aspect of the mandibular canine.

#### *B. Characteristics that resemble those of the mandibular second premolar:*

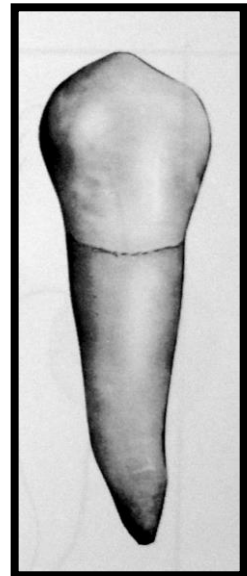
1. The mesial and distal contact areas are located at nearly the same level.
2. The curvature of the cervical line mesially and distally is similar.
3. The tooth has more than one cusp.
4. The length of the root of the mandibular first premolar is closer to the length of the root of the mandibular second premolar.

## **Principal Identifying Features**

1. Marked lingual inclination of the crown.
2. Two cusps: buccal and lingual; the buccal cusp is larger, and the lingual cusp is like a more developed cingulum.
3. Circular occlusal outline.
4. Single rounded root.

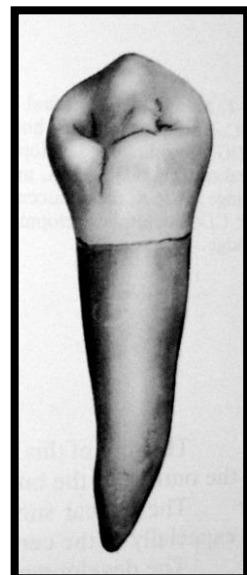
## **Buccal Aspect**

1. The crown is roughly trapezoidal with a prominent middle buccal ridge, which continues from the cusp tip to the cervical line.
2. The mesial slope of the buccal cusp is shorter than the distal slope.
3. The contact areas mesially and distally are broad and at the same level.
4. The mesial and distal outlines from the cervical line to the crest of curvature are slightly concave.
5. The tip of the buccal cusp is sharp and located mesial to the long axis of the crown.



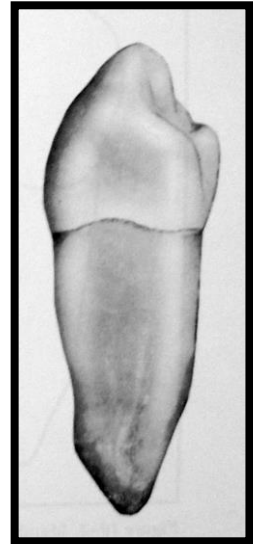
## **Lingual Aspect**

1. The crown and the root taper lingually, and the occlusal surface inclines greatly cervically.
2. The lingual cusp is poorly developed, but is pointed.
3. There is a developmental groove named "mesio-lingual developmental groove", which divides the lingual cusp into the mesio-buccal and lingual lobes.



### **Mesial Aspect**

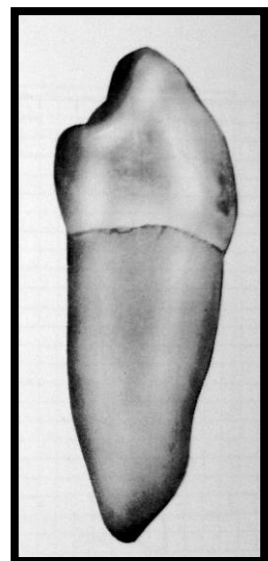
1. The tip of the buccal cusp nearly reaches the center of the root, and the convexity of the lingual outline of the cusp will be lingual to the lingual outline of the root.
2. The buccal outline is very curved, and the crest of curvature is near the middle third of the crown.
3. The lingual outline is less curved than the buccal outline, with the crest of curvature at the center of the middle third.
4. The height of the lingual cusp is two-thirds the height of the buccal cusp from the cervical line to the tip of the cusp.
5. The surface of the crown mesially is smooth except for the presence of the mesio-lingual developmental groove.

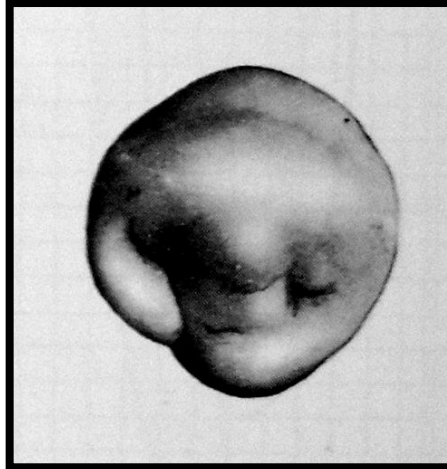


### **Distal Aspect**

The distal aspect of the mandibular first premolar differs from the mesial aspect in the following points:

1. There is no developmental groove in the distal aspect.
2. The distal marginal ridge is higher than the mesial marginal ridge, with less inclination lingually.
3. The curvature of the cervical line distally is null.





### **Occlusal Aspect**

1. The buccal ridge is prominent.
2. The mesio-buccal and disto-buccal line angles are rounded and prominent.
3. The crown converges sharply to the center of the lingual surface.
4. The marginal ridges are well developed.
5. The lingual cusp is small.
6. The triangular ridge of the buccal cusp is large, while the triangular ridge of the lingual cusp is small.
7. There are two fossae: mesial and distal fossae.
8. The mesial contact area is smaller than the distal contact area because it is constricted by the mesio-lingual developmental groove.