

Oral Medicine

Pof. Dr. Fawaz Al-Aswad

SALIVARY GLAND DISEASES

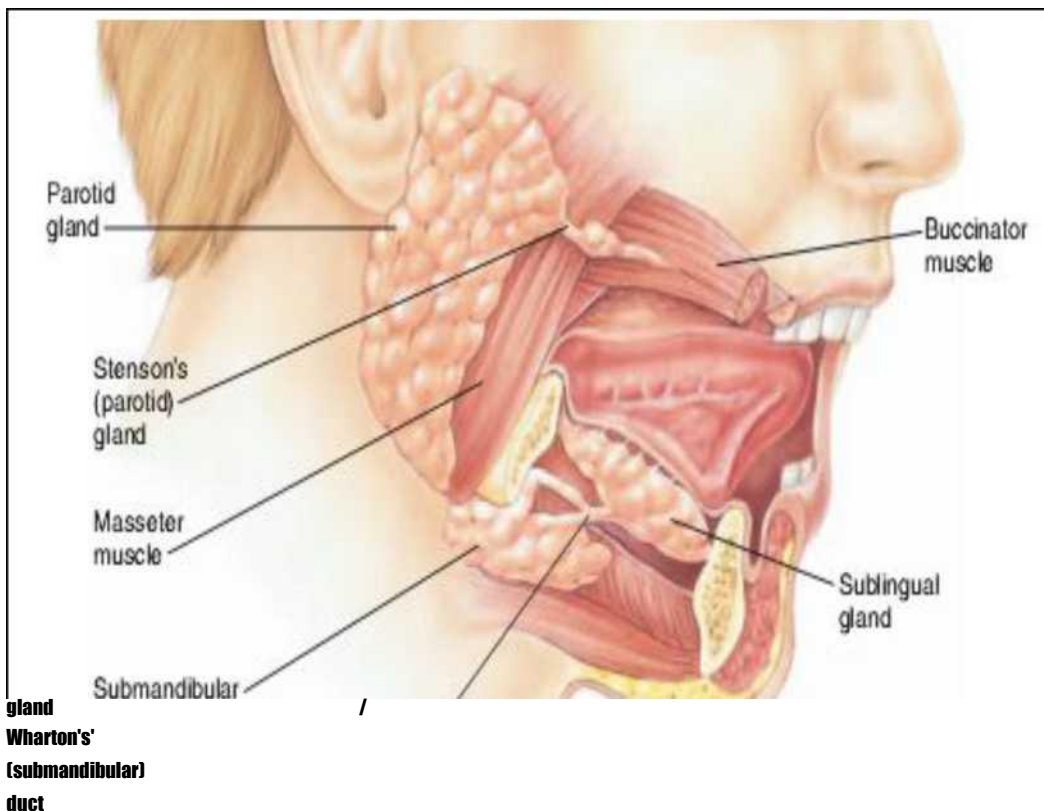
The most common presenting complaints of a patient with salivary gland disease are oral dryness (xerostomia) or a glandular swelling or mass.

There are Major and Minor groups of Salivary Glands:

The Major groups of salivary glands which are consisting of three major glands, the parotid, submandibular and sublingual glands. The parotid and submandibular glands each drain into the mouth in a single long duct. The sublingual glands drain via many small ducts.

The major salivary glands can also be classified based on the dominant saliva-producing acinar cell type: serous, mucous, or a mix of serous and mucous cells. Serous cells produce a more watery, enzyme-rich saliva. Mucous cells secrete a more viscous fluid with plentiful salivary glycoproteins known as mucins.

The parotid gland is composed primarily of serous cells. submandibular gland are a mix of mucous and serous types ,while the sublingual and minor salivary glands are of the mucous type.



There are also between 600 and 1000 minor salivary glands named for the sites which they occupy (i.e., labial, buccal, lingual, palatal, retromolar).

In addition, there are three sets of minor salivary glands of the tongue:

- 1- the glands of Weber, found along the border of the lateral tongue

- 2- the glands of von Ebner, surrounding the circumvallate papillae
- 3- the glands of Blandin and Nuhn, also known as the anterior lingual glands, found in the anterior ventral tongue.

Parotid saliva is secreted through Stensen's ducts, the orifices of which are visible on the buccal mucosa in the vicinity of the maxillary first or second molar.

Submandibular gland saliva is secreted through the submandibular duct (Wharton's duct), which drains saliva from each submandibular gland and exits at the sublingual caruncles on either side of the lingual frenulum .

The sublingual glands are drained by 8-20 excretory ducts called the ducts of Rivinus. The largest of all, the sublingual duct (of Bartholin) joins the submandibular duct to drain through the sublingual caruncle. The sublingual caruncle is a small papilla near the midline of the floor of the mouth on each side of the lingual frenum. Most of the remaining small sublingual ducts open separately into the mouth on an elevated crest of mucous membrane

. Both sublingual glands unite anteriorly and form a single mass through a horseshoe configuration around the **lingual frenulum**. The superior aspect of this U-shape forms an elevated, elongate crest of mucous membrane called the **sublingual fold** (plica sublingualis). Each sublingual fold extends from a posterolateral position and traverses anteriorly to join the **sublingual papillae** at the midline bilateral to the lingual frenulum.

Whole saliva (WS; the mixed fluid contents of the oral cavity) is a hypotonic fluid relative to blood plasma and is composed of secretions from the major and minor salivary glands.

It is composed of greater than 99% water and less than 1% proteins and salts. WS may also contain variable amounts of gingival crevicular fluid, microorganisms, food debris, exfoliated mucosal cells, and mucus.

The most common presentation of salivary gland disease is xerostomia which is a subjective complaint of dry mouth.

Hyposalivation refers to a quantified reduced salivary flow rate and may or may not be accompanied by xerostomia.

Similarly, xerostomia may or may not be associated with hyposalivation and can be a result of, for example, a change in salivary composition to a greater mucous content.

Hypersalivation (ptyalism)

Refers to an increase in production of saliva and/or a decrease in oral clearance of saliva.

Salivary gland dysfunction is commonly used to indicate decreased salivary flow or another quantifiable alteration in salivary performance

Causes of salivary gland hypofunction include:-

1- Medications

xerogenic medications (including many antidepressants, Anticholinergics, antispasmodics, antihistamines, antihypertensives, sedatives, diuretics, and bronchodilators)

2- Other agents (e.g., caffeine, alcohol, cigarette smoking) irradiation to the head and neck (i.e., external and internal beam radiation therapy)

3- Systemic disease (e.g., diabetes mellitus), salivary gland masses

4- Psychological conditions (e.g., depression)

5- Malnutrition (e.g., bulimia, dehydration)

6- Autoimmune disease (e.g., SS)

7- Other unspecified or undiagnosed conditions. (Anxiety)

List of Differential Diagnosis for Salivary Gland Hypofunction

Autoimmune:- Chronic graft-versus-host disease ,Sjogren's syndrome

Developmental :- Salivary gland aplasia Iatrogenic:- External beam

radiation, Internal beam radiation Postsurgical :- (adenectomy, ductal

ligation), Botox injection Inflammatory:- IgG4-related disease (Mikulicz's disease)

Infectious:- Viral: CMV, HIV, hepatitis C

Granulomatous: - Tuberculosis Medication-associated

Neoplastic :- Benign and malignant salivary gland tumors

Nonneoplastic :- Sialolithiasis

Systemic :- Anorexia nervosa, diabetes mellitus, chronic alcoholism, sarcoidosis

Symptoms of Salivary Gland Dysfunction

Symptoms of salivary gland hypo function are related to

1- Decreased fluid in the oral cavity and this may have an effect on mucosal hydration and oral functions.

2- Patients may complain of dryness of all the oral mucosal surfaces, including the lips and throat, and difficulty chewing, swallowing, and speaking.

3- Other associated complaints may include oral pain, an oral burning sensation, chronic sore throat and pain with swallowing.

4- The mucosa may be sensitive to spicy or coarse foods, limiting the patient's enjoyment of meals, which may compromise nutrition.

5- The need to sip liquids to swallow food, or difficulties in swallowing dry food have all been highly correlated with measurable decreases in secretory capacity.

Past and Present Medical History

Over 400 drugs are reported to have dry mouth as a side effect, individual that has recently started taking a tricyclic antidepressant.

A thorough history is essential. If the past and present medical history reveals medical conditions like a patient who has received radiotherapy for a head and the neck malignancy. A patient's report of eye, throat, nasal, skin, or a vaginal dryness, in addition to xerostomia, may be a significant indication of a systemic condition, such as Sjogren's syndrome.

Clinical Examination

Extra and intra oral examination: -

- 1- Signs of mucosal dryness:- Candidiasis, Enlargement of salivary gland. Viscous or scant secretions.
- 2- Enlargement can be associated with a variety of inflammatory, infectious, or neoplastic and other conditions
- 3- A cloudy exudates may be a sign of bacterial infection. The exudates should be cultured if it does not appear clear, particularly in the case of an enlarged gland.
- 4- Function of the facial nerve when evaluating parotid tumors.
- 5- Tumors of the minor salivary glands are usually smooth masses located on the hard or soft palate.
- 6- Ulceration of the overlying mucosa should raise suspicion of malignancy.

The parotid glands

Is the largest of the salivary glands, are positioned on the lateral aspect of the face overlying the posterior surface of the mandible, anteroinferiorly to the auricle.

A superficial and deep lobe based on the course of the facial nerve as it traverses the gland. Most benign tumors of the parotid gland are located within the superficial lobe and therefore are amenable to resection by superficial parotidectomy.

Because of its relationship to the parotid gland, it is important to document function of the facial nerve when evaluating parotid masses. Facial nerve paralysis is usually indicative of malignancy. Rarely, infection or rapidly growing benign tumors may cause facial nerve paralysis.

Other findings suggesting malignancy include

- Hardness.
- Fixation.
- Tenderness.
- Infiltration of surrounding structures - eg, facial nerve, local lymph nodes.
- Overlying skin ulceration.
- Cranial nerve palsy

Bilateral parotid gland masses are usually due to:-

- lymphadenopathy

- Warthin's tumors
- lymphoepithelial cysts (LECs)
- enlarged lymph nodes in the setting of HIV
- SS
- rarely other salivary gland tumors such as the acinic cell adenocarcinoma.

Multiple painless masses within a single parotid gland may be due to:-

- Warthin's tumors
- lymph nodes
- metastatic disease

other benign and malignant tumors.

Tumors in the submandibular or sublingual glands usually present as painless, solitary, slow-growing mobile masses. Bimanual palpation, with one hand intraorally on the floor of the mouth and the other extraorally below the mandible, is necessary to evaluate the glands adequately.

Tumors of the minor salivary glands are usually smooth masses located most commonly on the hard or soft palate but may present anywhere minor salivary glands are present.

Salivary gland neoplasms arise most commonly in the parotid glands followed by the submandibular, sublingual, and minor salivary glands. The relative proportion of malignant neoplasms is greater the smaller the gland: that is, a neoplasm in the parotid gland is more likely to be benign than one arising in a minor Salivary Gland Imaging

Radiography

lateral oblique and anteroposterior (AP) projections are used to visualize the parotid glands. A standard occlusal film can be placed intraorally adjacent to the parotid duct to visualize a stone close to the gland orifice.

It is useful particularly for the visualization of radiopaque sialoliths and the evaluation of bony destruction associated with malignant neoplasms and it can provide a background for interpretation of the sialogram.

Sialography:- is the radiographic visualization of the parotid and submandibular salivary glands and ducts following retrograde instillation of soluble contrast material into the Stensen's or Wharton's ducts .

The ducts of the sublingual glands are too small for reliable injection of contrast medium. It provides the clearest visualization of the branching ducts and acinar end pieces.

It is the recommended method for evaluating intrinsic and acquired abnormalities of the ductal system:-

- 1- ductal stricture, 2- obstruction, 3- dilatation, 4- ruptures
- 5- for identifying and localizing sialoliths

The two contraindications to sialography are:-

- 1- Active infection

2- Allergy to contrast media

Oil-and water-based contrast media are available. (both containing iodine and therefore contraindicated in patients with iodine sensitivity) are available Radiographic views for sialography include panoramic, lateral oblique, AP.

Following the sialographic procedure, the patient should be instructed to massage the gland and/or to suck on lemon drops to promote the flow of saliva and contrast material out of the gland.

After approximately one hour. If a substantial amount of contrast material remains in the salivary gland, follow-up visits should be scheduled until the contrast material elutes or is fully resorbed.

Incomplete clearing can be due to:-

1. obstruction of salivary outflow,
2. extraductal or extravasated contrast medium,
3. collection of contrast material in abscess cavities
4. impaired secretory function

Sialography performed during active infection may lead to :

- 1- further irritate and potentially rupture the already inflamed gland.
- 2- the injection of contrast material might force bacteria throughout the ductal structure and worsen an infection.

The iodine in the contrast media may induce an allergic reaction and can also interfere with thyroid function tests and with thyroid cancer evaluation by nuclear medicine if these are done c- **ULTRASONOGRAPHY (US)**

Advantages,

- 1- initial evaluation of the salivary glands, especially in children and pregnant women
- 2- evaluating for suspected sialolithiasis and salivary gland abscesses.
- 3- differentiating between intra-and extraglandular masses
- 4- used to distinguish focal from diffuse disease,
- 5- assess adjacent vascular structures and vascularity
- 6- distinguish solid from cystic lesions,
- 7- guide fine needle aspiration biopsy (FNAB)
- 8- perform nodal staging.
- 9- It can correctly differentiate malignant lesions from benign in 90% of cases d-

Radionuclide Salivary Imaging

Scintigraphy with technetium (Tc) 99m pertechnetate is a dynamic and minimally invasive diagnostic test to assess salivary gland function and to determine abnormalities in gland up take and excretion.

It is taken up by the salivary glands (following intravenous injection), transported through the glands, and then secreted into the oral cavity.

Only the parotid and submandibular glands are visualized distinctly, as well as the

thyroid gland. It has been used to aid in the diagnosis of:-

1- ductal obstruction, 2- sialolithiasis, 3- gland aplasia, 4- Bell's palsy, 5- sjogren's syndrome.

CT is the method of choice in patients suspicious for inflammatory disease (abscess, calculi, major salivary duct dilatation, and acute inflammation) or in patients with contraindication for MR imaging

- Superior to plain radiographs and US in detection of sialolithiasis
- Allows detection and assessment of extent of salivary gland tumors
- Helpful in the differential diagnosis of salivary gland tumors
- Helpful in assessment of deep lobe of parotid gland and the minor salivary glands
- calcifications (pre-contrast) and enhancement pattern (post-contrast)
- Malignant tumor may mimic a benign tumor on CT scan
- Moderate accuracy (60-70%) in predicting the histological diagnosis of a lesion

also CT provides definition of cystic walls, making it possible to distinguish fluid-filled masses from abscess.

For visualizing masses that are poorly defined on MRI.

For patients who are unable to lie still long enough for adequate MRI (pediatric, geriatric, claustrophobic, and mentally or physically challenged patients).

For patients for whom MRI is contraindicated.

The disadvantage of CT include:-

Radiation exposure, administration of iodine-containing contrast media for enhancement, and potential scatter from dental restoration.

MRI provides images for evaluation salivary gland pathology, adjacent structure, and proximity to the facial nerve

- Non-invasive alternative to conventional/digital sialography
- Allows accurate assessment of salivary gland calculi and stenoses
- Advantages
 - Non-invasive
 - No exposure to ionising radiation
 - Does not require use of contrast material
 - Limitations
- False negative readings may occur in patients with very small calculi that are causing no ductal dilatation
- Inability to distinguish solid calculi from inspissated mucus and/or debris
- Distortion artefacts caused by dental amalgam may impair visualisation of calculi or

- stenoses near the main ductal orifice
- Disadvantages

Expensive

Limited availability.

MRI is contraindicated for:

1. Patients with pacemakers or implants such as aneurismal bone clips. If the implant contains magnetic metal, an MRI can not be performed; however, dental implants are not magnetic and so are not contraindicated.
2. Patients who have difficulty maintaining a still position.
3. Patients with claustrophobia.

Cone Beam CT

Cone beam CT (CBCT) is increasingly being employed in dentomaxillo facial imaging since it provides high spatial resolution of osseous structures at a lower dose of radiation than conventional CT.

Using a cone-shaped x-ray beam and two-dimensional detectors, the CBCT scanner collects volume data by means of a single rotation taking 9-40 seconds

CBCT sialography provides several advantages over conventional sialography including:-

- 1- Three-dimensional reconstruction
- 2- allowing for manipulation of image rotation,
- 3- Slice thickness,
- 4- generation of various cross-sectional slices.

Overall, CBCT sialography appears to offer an improvement in imaging of salivary gland ductal system over conventional sialography.

Salivary gland biopsy

The labial minor salivary glands are most commonly biopsied since they provide the most accessible source of tissue, especially where SS is suspected

SEROLOGIC EVALUATION

No single definitive laboratory test for the diagnosis of Sjogren Syndrome, a combination of abnormal test results is frequently observed:

Elevated erythrocyte sedimentation rate (ESR), mild normocytic anemia, leukopenia.

Autoantibodies are present in the majority of SS cases:-

Elevated immunoglobulins (particularly IgG), : rheumatoid factor (RF), antinuclear antibodies (ANAs), and anti-SSA/Ro and anti-SSB/La are strongly indicative of SS.

The most proposed classification criteria for SS by the American College of Rheumatology (ACR) requires at least two of three criteria for case definition; one of which is a positive serum anti-SSA/Ro and/or anti-SSB/La or positive RF and ANA.

SPECIFIC DISEASES AND DISORDERS OF THE SALIVARY GLANDS

Developmental Abnormalities

- Complete absence (aplasia or agenesis) of salivary gland which is rare, although it may occur together with other developmental defects

- Accessory ducts are common and do not require treatment

- Aberrant salivary glands are salivary tissues that develop at unusual anatomic sites.

Ectopic salivary glands have been reported in a variety of locations, including the middle-ear, external auditory canal, neck, posterior mandible, anterior mandible, pituitary gland, and cerebellopontine angle. These are usually incidental findings and do not require intervention.

- The Stafne bone defect (SBD; also known as Stafne bone cyst):- is an asymptomatic depression of the lingual surface of the mandible often associated with ectopic salivary gland tissue. However, it is not a true cyst as there is no epithelial lining. The most common location of the SBD is in the region of the third molar inferior to the mandibular canal

- Diverticula

By definition, a diverticulum is a pouch or sac protruding from the wall of a duct. Diverticula in the ducts of the major salivary glands often lead to pooling of saliva and recurrent sialadenitis. Diagnosis by sialography. Patients with diverticula are encouraged to regularly milk the involved salivary gland and to promote salivary flow through the duct.

- Darier's Disease

Salivary duct abnormalities have been reported in Darier's disease (also known as dyskeratosis follicularis). Sialography of parotid glands in this condition revealed duct dilation, with periodic stricture affecting the main ducts. Symptoms of occasional obstructive sialadenitis have been reported.

Sialolithiasis (Salivary Stones)

Sialoliths (also termed salivary calculi or salivary stones) are typically calcified organic masses that form within the secretory system of the major salivary glands.

The etiologic factors favoring salivary stone formation may be classified into two groups:

1. factors favoring saliva retention:

- .Irregularities in the duct system

- .local inflammation dehydration

- .Medications such as anticholinergics and diuretics

- 2.saliva composition

- .Calcium saturation

- .Deficit of crystallization inhibitors such as phytate

- .Bacterial infection also promotes sialolith formation due to an associated increase in salivary pH favoring calcium phosphate supersaturation.

Although no causal relationship between tobacco smoking and an increased risk of sialolithiasis has been definitively shown, smoking is known to adversely affect the cytotoxic activity of saliva and salivary amylase. Salivary stones occur most commonly in the submandibular glands (80%-90%), followed by the parotid (5%-15%) and sublingual (2%-5%) and only very rarely occur in the minor salivary glands.

The higher rate of sialolith formation in the submandibular gland is due to:

- (1) the torturous course of Wharton's duct,

- (2) the higher calcium and phosphate levels of the secretion contained within

- (3) the dependent position of the submandibular glands that leaves them prone to stasis
- (4) the increased mucoid nature of the secretion.
- (5) since the submandibular and parotid glands' secretion is dependent on nervous stimulation, when there is an absence of stimulation, secretory inactivity increases the risk of stone development.

Clinical Presentation

Patients with sialoliths most commonly present with a history of acute, colicky pain and intermittent swelling of the affected major salivary gland during meals. The degree of symptoms is dependent on the extent of salivary duct obstruction and the presence of secondary infection.

Salivary gland swelling will be evident upon eating since the stone completely or partially blocks the flow of saliva resulting in salivary pooling within the gland ductal system.

Since the glands are encapsulated and there is little space for expansion, enlargement causes pain. Swelling will subside when salivary stimulation ceases and output decreases.

Stasis of saliva may lead to infection, fibrosis, and gland atrophy. If there is concurrent infection, there may be expressible suppurative or nonsuppurative drainage and erythema or warmth in the overlying skin.

Complications from sialoliths include:-

- Acute sialadenitis ductal
- stricture ductal
- dilatation Fistula and a sinus tract
- Ulceration in the tissue covering the stone in chronic cases.

Diagnosis

Plain film radiographs are helpful to visualize sialoliths; they, readily available, and result in minimal radiation exposure. Since small and poorly calcified stones may Not be readily identifiable, this modality is most useful in cases of suspected submandibular sialolithiasis, where an occlusal radiograph taken at 90° from the floor of the mouth is recommended. However, other calcified entities such as phleboliths (stones that lie within a blood vessel), calcified cervical lymphadenopathy, and arterial atherosclerosis of the lingual artery can also appear on these films.

Stones in the parotid gland can be more difficult to visualize for several reasons. Due to the Superimposition of other anatomic structures, sialoliths may be obscured and therefore the choice of radiographic views is important. An AP view of the face or an occlusal film placed intraorally adjacent to the duct may be useful in these cases.

Contrast sialography using iodinated contrast media may be used to visualize the parotid and submandibular ductal systems.

Sialography can also aid in differentiating calcified phleboliths from sialoliths since the former lie within a blood vessel, where as the latter occur within the ductal structure

Limitations of this modality include the use of ionizing radiation, dependence on successful ductal cannulation, pain during and after the procedure, and potential allergy to the contrast medium. The use of contrast sialography is also contraindicated in the presence of

acute sialadenitis.

Ultrasound (US) is widely used as a first-line imaging modality to assess the presence of salivary gland calculi. Transoral sonography using an intraoral approach has been employed as an imaging modality in suspected sialolithiasis. US is noninvasive, less costly than other imaging, and may be able to visualize radiolucent calculi.

Treatment

During the acute phase of sialolithiasis, therapy is primarily supportive. Standard treatment during this phase often involves the use of analgesics, hydration, antibiotics, and antipyretics, as necessary.

Use Sialogogues (is a drug or substance that increases the flow rate of saliva e.g. chewing gum, pilocarpine, and cevimeline), massage and heat applied to the affected area may also be beneficial. Stones at or near the orifice of the duct can often be removed transorally by milking the gland, but deeper stones require intervention with conventional surgery or sialendoscopy placed to maintain patency of the duct.

Extracorporeal shock wave lithotripsy (ESWL) also allows for fragmentation of large sialoliths of any size or location.

Extravasation and Retention Mucoceles and Ranulas Mucocele

Mucocele is a clinical term that describes swelling caused by the accumulation of saliva at the site of a traumatized or obstructed minor salivary gland duct. Mucoceles can be classified histologically as extravasation types or retention types the extravasation mucocele does not have an epithelial lining or a distinct border. The formation of an extravasation mucocele is believed to be the result of trauma to a minor salivary gland excretory duct. Laceration of the duct results in pooling of saliva in the adjacent submucosal tissue and consequent swelling.

The retention type mucocele is caused by obstruction of a minor salivary gland duct often by sialolith, periductal scarring, or tumor. The blockage of salivary flow results in the accumulation of saliva and dilation of the duct.

Clinical Presentation

Mucoceles often present as discrete, painless, smooth-surfaced swellings that can range from a few millimeters to a few centimeters in diameter. Superficial lesions frequently have a characteristic blue hue. Deeper lesions can be more diffuse, covered by normal-appearing mucosa without the distinctive blue color.

The lesions vary in size over time; superficial mucoceles are frequently traumatized, causing them to drain and deflate. Mucoceles that continue to be traumatized are most likely to recur and may develop surface Ulceration.

Although the development of a bluish lesion after trauma is highly suggestive of a mucocele, other lesions (including salivary gland neoplasms, soft tissue neoplasms, vascular malformations, and vesiculobullous diseases) should be considered in the differential diagnosis.

Extravasation mucoceles most frequently occur on the lower lip, where trauma is common. The buccal mucosa, tongue, floor of the mouth, and retromolar region are other commonly traumatized areas where mucous extravasation may be found. These types of

mucoceles are most commonly seen in children and teenagers.

Treatment

Conventional definitive surgical treatment of mucoceles involves removal of the entire lesion along with the feeder salivary glands and duct. Incomplete removal of the mucocele may result in recurrence.

Surgical management can be challenging since it can cause trauma to adjacent minor salivary glands and lead to the development of a new mucocele.

Alternative treatments that have been explored with varying degrees of success include electrosurgery, cryosurgery using liquid nitrogen, laser surgery and micromarsupialization, intralesional injections of corticosteroids, and sclerotherapy.

Ranula

A form of mucocele located in the floor of the mouth is known as a *ranula*. Ranulas are believed to arise from the sublingual gland. Possible causes include:-

- 1- Mechanical trauma to its ducts of Rivinus, resulting in extravasation of saliva.
- 2- An obstructed salivary duct or a ductal aneurysm.

The predilection of ranulas in the sublingual glands has been thought to be due to the gland's continuous salivary secretion that precludes effective sealing of the mucous extravasation via fibrosis, in contrast to salivary secretion in the parotid and submandibular glands, which is dependent on gustatory stimulation. Ranulas are most common in the second decade of life and in females.

Oral ranula remains confined to the sublingual space. A congenital predisposition toward development of ranulas has been suggested, particularly in those of Asian descent. In addition, particular anatomic variations of the ductal system of the sublingual gland may contribute to the formation of ranulas.

Clinical Presentation

The most common presentation of the "oral" ranula is a painless, slow-growing, fluctuant, movable mass located in the floor of the mouth. Usually, the lesion forms to one side of the lingual frenulum; however, if the lesion extends deep into the soft tissue, it can cross the midline.

As observed with mucoceles, superficial ranulas can have a typical bluish hue, but when the lesion is deeply seated, the overlying mucosa may have a normal appearance. The size of the lesions can vary, and larger lesions can cause deviation of the tongue.

Diagnosis

Imaging to diagnose an oral ranula may not be necessary due to its characteristic clinical appearance, but to rule out other cystic lesions (e.g., thyroglossal duct cyst, epidermoid cyst, cystic hygroma), FNA, ultrasound, CT with contrast, and MRI have been used. Ultrasound has been recommended for oral ranulas.

Treatment

The most predictable method of eradicating both oral and plunging ranulas is to remove the associated sublingual gland because this will almost certainly eliminate recurrences.

Sublingual gland adenectomy combined with intraoral excision of the ranula is suggested for the simple ranula, other procedures used for the treatment of ranulas have

included simple excision, marsupialization,

Injection of the sclerosing agent, silver nitrate, and botulinum toxin (BoNT) all with varying rates of success.

Postsurgical complications include:-lesion recurrence, sensory deficits of the tongue, and damage to Wharton's duct.

Frequency of recurrence is related to the surgical technique selected and has been reported as 67% with marsupialization, 58% with excision alone, and 1% with sublingual gland Excision.

Necrotizing Sialometaplasia (NS)

Description and Etiology

Necrotizing sialometaplasia (NS) is a benign, self-limiting, reactive inflammatory disorder of salivary tissue. NS can resemble a malignancy and its misdiagnosis has resulted in unnecessary radical surgery.

The etiology is unknown, although it likely represents a local ischemic event, infectious process, or perhaps an immune response to an unknown allergen. Development of NS has been associated with smoking, local injury, blunt force trauma, denture wear, and surgical procedures. It has been reported in pregnant patients and those with diabetes mellitus, sickle-cell disease, cocaine abuse, bulimia, and chronic vomiting. The incidence of NS appears to be higher in male patients and especially in those older than 40 years

Clinical Presentation

NS has a spectrum of clinical presentations. Most commonly it presents as a painful, rapidly progressing swelling of the hard palate with central ulceration and peripheral erythema. The associated pain is often described as sharp in character and may precede mucosal changes. Numbness or anesthesia in the associated area may be an early finding. The lesions are of rapid onset and range in size from 1 to 3 cm. Lesions occur predominantly on the palate; however, lesions can occur anywhere salivary gland tissue resides, including the lips, retromolar , buccal mucosa, tongue, nasal cavity, and maxillary sinus. Although the lesions are usually unilateral, bilateral cases have been reported. Lesion affecting the hard palate clinically resemble salivary gland malignancies particularly mucoepidermoid carcinoma and adenoid cystic carcinoma.

Rapid onset of NS may be a distinguishing feature. Lesions often occur shortly after an inciting event to the area such as oral surgical procedures, restorative dentistry, or administration of local anesthesia, but lesions also reported to develop weeks after a dental procedure or trauma. It is also not uncommon for lesions to develop in an individual with no history of trauma or oral habit

Diagnosis

histopathologic diagnosis ,and a complete clinical history, medical history, and ideally, clinical photos should be submitted with the specimen.

Treatment

NS is considered a self-limiting condition typically resolving within 3-12 weeks. During this time, supportive and symptomatic treatment is usually adequate. Appropriate analgesics combined with use of an antiseptic mouthwash such as 0.12% chlorhexidine gluconate have

been recommended.

Surgical intervention is typically not required in cases of NS; however, there are reports of resolution following debridement for particularly large lesions and those secondarily infected with bacterial species and *Candida*.

Cheilitis Glandularis

Description and Etiology

Cheilitisglandularis (CG) is a chronic inflammatory disorder affecting the minor salivary glands and their ducts in which thick saliva is secreted from dilated ductal openings. (CG) is characterized by superficial ulceration, painless crusting, swelling, and induration of the lip; a mucinous exudate is apparent at the ductal openings.

Although the etiology of (CG) is still undetermined, it has been suggested that it is an autosomal dominant hereditary disease. In addition, external factors (mainly UV rays) have been implicated as the condition occurs more frequently in fair-skinned adults and albino patients appear particularly prone to this condition. Additional proposed predisposing factors include poor oral hygiene, chronic exposure to sunlight and wind, smoking, and an immunocompromised state.

Occur in middle-aged and elderly men with only a few cases reported in women and children. it is associated with a relatively high incidence of squamous cell carcinoma of the lip. Although there may be a genetic susceptibility, no definitive cause has been established..

Clinical Presentation

CG presents with a secretion of thick saliva secreted from dilated ostia of swollen labial minor salivary glands. This saliva often adheres to the vermilion causing discomfort to the patient. Edema and focal ulceration may also be present.

CG primarily affects the lower lip, but there are reports of upper lip and even palatal involvement.

Differential diagnosis (DD) of CG includes :- multiple mucocele, chronic sialadenitis of the minor salivary glands, factitious cheilitis, orofacial granulomatosis and actinic cheilitis.

Treatment

Elimination of potential predisposing factors and the use of lip balms, emollients, and sunscreens for those with excessive exposure to the sun and wind are advised. Conservative treatment of CG may involve using topical, intralesional or systemic steroids, systemic anticholinergics, systemic antihistamines, and/or antibiotics.

Refractory cases require surgical intervention such as cryosurgery, vermilionectomy, and/or labial mucosal stripping. Several reports documented the development of squamous cell carcinoma in areas affected by CG, leading some to call CG a premalignant lesion.

External Beam Radiation-Induced Pathology

Description and Etiology

External beam radiation therapy is standard treatment for head and neck cancers, and the salivary glands are often within the field of radiation. Although therapeutic dosages for cancer are typically in excess of 65 Gy, permanent salivary gland damage and symptoms of

oral dryness can develop after only 24-26 Gy.

The etiopathogenesis of radiation-induced salivary gland destruction is multifactorial, including programmed cell death (apoptosis) in conjunction with production of reactive oxygen species and other cytotoxic products. Radiation-associated impaired blood flow may also contribute to the destruction of glandular acinar and ductal cells.

Clinical Presentation

Acute effects on salivary function can be recognized within a week of initiating radiotherapy, with symptoms of oral dryness and thick, viscous saliva developing by the end of the second week.

Oral mucositis is a very common consequence of treatment and can become severe enough to alter the radiation therapy regimen.

Mucositis appears as a sloughing of the oral mucosa with erythema and ulceration. The pain associated with mucositis is described as a burning.

Mucositis generally persists throughout radiotherapy, peaks at the end of the irradiation, and continues for one to three weeks after cessation of treatment.

By the end of a typical six- to seven-week course of radiotherapy, salivary gland function is nearly absent. Hypofunction remains at a steady rate postradiation, with only small increases to two years post-radiotherapy (post-RT).

This can be permanent if the major salivary glands receive more than 24-26 GY. Permanent xerostomia and oral complications of salivary hypofunction impair a patient's quality of life.

Signs and symptoms of radiation-associated xerostomia include a burning sensation of the tongue, Assuring of the tongue and lips, new and recurrent dental caries, difficulty in wearing oral prostheses, and increased thirst.

Additional sequelae of radiation-induced salivary dysfunction include candidiasis, microbial infections, plaque retention, Gingivitis, difficulty in speaking and tasting, dysphagia, and mucosal pain.

Internal Radiation-Induced Pathology .Description and etiology

Radioactive iodine (RAI) is the standard treatment in cases of papillary and follicular thyroid carcinomas following thyroidectomy or in cases of suspected or known metastases.

A significant portion of the RAI taken up by thyroid tissue is concentrated and secreted through the salivary gland tissue resulting in radiation exposure of the salivary parenchyma and possible damage. Standard doses of RAI often cause obstructive duct symptoms, while hyposalivation from Parenchymal damage is usually observed with larger or repeated doses of RAI.

Acute risks associated with RAI include ageusia, salivary gland swelling, and pain, while longterm side effects include recurrent sialadenitis with xerostomia, stomatitis, and dental caries. In some circumstances, RAI treatment may lead to glandular fibrosis and permanent salivary gland hypofunction.

Clinical Presentation

The glandular effect of RAI can be mild to severe. Patients may be asymptomatic or may complain of parotid gland swelling (usually bilaterally), pain, xerostomia, and decreased salivary gland function almost immediately after treatment.

RAI-induced salivary gland injury is irreversible; however, residual functioning salivary gland tissue is often present and responsive to therapy.

Following administration of ¹³¹I, patients should undergo an aggressive salivary stimulation routine that includes sugar-free lozenges, sour candies, and gums to stimulate salivary flow. This will aid in clearing the ¹³¹I from the salivary glands and potentially decrease salivary gland damage. Stimulation of salivary flow by these means, however, should not be initiated within the first 24 hours after ¹³¹I therapy as this has been shown to potentially increase the salivary gland side effects of the RAI.

Pilocarpine and cevimeline used before and after RAI treatment may decrease transit time through the salivary glands, thereby diminishing exposure.

Allergic Sialadenitis

Enlargement of the salivary glands has been associated with exposures to various pharmaceutical agents and allergens. It is unclear whether all of the reported cases are true allergic reaction or whether some represent secondary infections resulting from medication that reduced salivary output.

Compounds associated with allergic Sialadenitis

- Ethambutol.
- Heavy metals.
- Iodine compounds
- Isoproterenol.
- Phenobarbital.
- Phenothiazine.
- Sulfisoxazole

Viral Diseases

MUMPS. (PARAMYXOVIRUS OR EPIDEMIC PAROTITIS) : acute viral infection caused by a ribonucleic acid (RNA) paramyxovirus and is transmitted by direct contact with salivary droplets.

Clinical Presentation

Mumps typically occurs in children between the ages of 4 and 6 years. The incubation period is two to three weeks.

The symptoms of mumps normally appear 2-3 weeks after the patient has been infected. However, almost 20 percent of people with the virus do not suffer any symptoms at all.

Initially, flu-like symptoms will appear, such as:

- Body aches

- Headache
- Loss of appetite and/or nausea
- General fatigue
- Fever (low-grade)

Over the next few days, the classic symptoms of mumps will develop. The main symptom is painful and swollen parotid glands, one of three sets of salivary glands; this causes the person's cheeks to puff out. The swelling normally does not occur in one go - it happens in waves.

Other associated symptoms can include:

- Pain in the sides of the face where it is swollen.
- Pain experienced when swallowing.
- Trouble swallowing.
- Fever (up to 103 degrees Fahrenheit).
- A dry mouth.
- Pain in joints.

Rarely, adults can contract mumps. In these cases, the symptoms are generally the same, but sometimes slightly worse and complications are slightly more likely.

Treatment for mumps

Drinking plenty of fluids may help to relieve the symptoms of mumps.

Because mumps is viral, antibiotics cannot be used to treat it, and at present, there are no anti-viral medications that can treat mumps.

Current treatment can only help relieve the symptoms until the infection has run its course and the body has built up an immunity, much like a cold. In most cases, people recover from mumps within 2 weeks.

Some steps can be taken to help relieve the symptoms of mumps:

- Consume plenty of fluids, ideally water - avoid fruit juices as they stimulate the production of saliva, which can be painful.
- Place something cold on the swollen area to alleviate the pain.
- Eat mushy or liquid food as chewing might be painful.
- Get sufficient rest and sleep.
- Gargle warm salt water.

- Take painkillers. Many painkillers are available to purchase over-the-counter or online, such as acetaminophen or ibuprofen.

Causes of mumps

Mumps is due to an infection by the mumps virus. It can be transmitted by respiratory secretions (e.g. saliva) from a person already affected with the condition. When contracting mumps, the virus travels from the respiratory tract to the salivary glands and reproduces, causing the glands to swell.

Examples of how mumps can be spread include:

- Sneezing or coughing.
- Using the same cutlery and plates as an infected person.
- Sharing food and drink with someone who is infected.
- Kissing.
- An infected person touching their nose or mouth and then passing it onto a surface that someone else may touch.

Individuals infected with the mumps virus are contagious for approximately 15 days (6 days before the symptoms start to show, and up to 9 days after they start). The mumps virus is part of the paramyxovirus family, a common cause of infection, especially in children.

Complications of mumps

Complications are more frequent in adults than children, the most common are:

- **Orchitis** - testicles swell and become painful, this happens to 1 in 5 adult males with mumps. The swelling normally goes down within 1 week; tenderness can last longer than that. This rarely results in infertility.
- **Oophoritis** - ovaries swell and are painful; it occurs in 1 in 20 adult females. The swelling will subside as the immune system fights off the virus. This rarely results in infertility.
- **Viral meningitis** - this is one of the rarest of the common complications. It happens when the virus spreads through the bloodstream and infects the body's central nervous system (brain and spinal cord).
- **Inflamed pancreas (pancreatitis)** - pain will be experienced in the upper abdomen; this occurs in 1 out of 20 cases and is usually mild.

If a pregnant woman contracts mumps in the first 12-16 weeks of her pregnancy, she will have a slightly increased risk of miscarriage.

Rarer complications of mumps include:

- **Encephalitis** - the brain swells causing neurological issues. In some cases, this can be fatal. This is a very rare risk factor and affects just 1 in 6,000 cases.
- **Hearing loss** - this is the rarest of all the complications affecting just 1 in 15,000.

As rare as some of these complications are, it is important to seek medical advice or help if an individual suspects they or their child, may be developing them.

Tests and diagnosis of mumps

Normally, mumps can be diagnosed by its symptoms alone, especially by examining the facial swelling. also:

- Check inside the mouth to see the position of the tonsils - when infected with mumps, a person's tonsils can get pushed to the side.
- Take the patient's temperature.
- Take a sample of blood, urine, or saliva to confirm diagnosis.
- Take a sample of CSF (cerebrospinal fluid) from the spine for testing - this is usually only in severe cases.

Prevention of mumps

The MMR vaccine will prevent mumps, measles, and rubella.

The mumps vaccine is the best method for preventing mumps; it can come on its own or as part of the MMR vaccine. The MMR vaccine also defends the body against rubella and measles.

The MMR vaccine is given to an infant when they are just over 1 year old and again, as a booster, just before they start school.

Mumps usually presents with one to two days of malaise, anorexia, and low- grade pyrexia with headache followed by nonpurulent gland enlargement. Glandular swelling increases over the next few days, lasting about one week. Twenty-five percent of cases may involve unilateral salivary gland swelling, or swelling may develop in the contralateral gland after a time delay, which can complicate diagnosis unless there is a high index of suspicion. Ninety-five percent of symptomatic cases involve the parotid gland only, while about 10% of cases involve the bilateral submandibular and sublingual glands concomitant with the parotid swelling. A minority of cases may involve the submandibular glands alone. Salivary gland

enlargement is sudden and painful to palpation with edema affecting the overlying skin and the duct orifice. If partial duct obstruction occurs, the patient may experience pain while eating.

Bacterial Sialadenitis

Bacterial infections of the salivary glands are most commonly seen in the patients with reduced salivary gland function. An acute and sudden onset of a swollen and painful salivary gland is termed an acute bacterial sialadenitis, whereas repeated infections are termed chronic bacterial sialadenitis .

Bacterial sialadenitis occurs more frequently in the parotid glands. It is theorized that the submandibular glands may be protected by the high level of mucin in the saliva, which has potent antimicrobial activity.

A purulent discharge may be expressed from the duct orifice, and samples of these exudates should be cultured for aerobes and anaerobes.

Risk factors

Include dehydration, the use of xerogenic drugs, salivary gland diseases, nerve damage, ductal obstruction, irradiation, and chronic diseases such as diabetes mellitus and SS. Retrograde bacterial parotitis following surgery under general anesthesia is a well-recognized complication. It is due to the markedly decreased salivary flow during anesthesia, often as the result of anticholinergic drugs and relative dehydration.

Although bacterial sialadenitis occurs most frequently in the parotid glands, it can occur in any of the glands. It is thought that the antimicrobial activity of mucin, found in the saliva of the submandibular and sublingual glands, may competitively inhibit bacterial attachment to the epithelium of the salivary ducts. The serous parotid gland saliva also contains less lysosomes, IgA antibodies, and sialic acid.

Anatomy may also play a protective role; tongue movements tend to clear the floor of the mouth and protect Wharton's duct. In contrast, the orifice of Stensen's duct is located adjacent to the molars, where heavy bacterial colonization occurs.

Clinical Presentation

Patients usually present with a sudden onset of unilateral or bilateral salivary gland enlargement. Approximately 20% of the cases present as bilateral infections. Complaints of fevers, chills, malaise, trismus, and dysphagia may accompany these findings. Observation of dry oral mucosa may indicate systemic dehydration.

The involved gland is enlarged, warm, painful, indurated, and tender to palpation. If Stensen's duct is involved, it may appear erythematous and edematous. There may also be erythema of the overlying skin.

Clinical examination of the involved glands involves bimanual palpation along the path of the excretory duct. In approximately 75% of cases, purulent discharge may be expressed from the orifice.

Diagnosis

Bacterial parotitis is largely a clinical diagnosis. If purulent discharge can be expressed from the duct orifice, samples should be cultured for aerobes, anaerobes, fungi, and mycobacteria. Differentiating between viral and bacterial infectious parotitis can be challenging. In general, viral infections are bilateral, affect younger patients, have prodromal

symptoms, do not involve purulent drainage, and patients appear to have less toxicity. Although systemic symptoms follow the development of a symptomatic gland in suppurative parotitis, the order is usually reversed in viral parotitis.

Sialoendoscopy, US, CT, MRI sialography, or percutaneous aspiration may be helpful to rule out chronic salivary gland infections, cysts, obstructions, or neoplasms

Treatment

Treatment goals of bacterial sialadenitis include resolution of signs and symptoms of infection, elimination of the causative bacteria, rehydration, and elimination of obstruction where present. This may involve the use of antibiotics, analgesics, heat application, fluids, glandular massage, oral hygiene products, and sialogogues.

Anti-inflammatory agents including steroids may help to rapidly reduce pain and swelling. (Patients should also be instructed to massage the gland several times a day. Where possible,) medications implicated in salivary gland hypofunction should be discontinued.

With these measures, significant improvement should be observed within 24 -48 hours.

Appropriate empiric antibiotic regimens should include coverage for *S. aureus* as well as oral polymicrobial aerobic and anaerobic infections. It is estimated that up to 75% of infections are caused by P-lactamase-producing bacteria, and therefore, treatment with anti-Staphylococcal penicillin, a combination P-lactamase inhibitor, or a first-generation cephalosporin is appropriate.

Macrolides such as azithromycin with metronidazole can be an alternative for those with a penicillin allergy. Antibiotics should not be started routinely unless bacterial infection is clinically obvious. Under all circumstances, purulent discharge from the salivary gland should be cultured to confirm the diagnosis and determine antibiotic sensitivity. Antibiotic therapy may need to be modified later based on culture results.

Additional potential complications include facial nerve palsy, sepsis, mandibular osteomyelitis, internal jugular vein thrombophlebitis, and respiratory obstruction. Systemic Condition with Salivary Gland Involvement

1- METABOLIC CONDITIONS include -

- Diabetes
- Anorexia Nervosa/Bulimia
- Chronic Alcoholism
- Dehydration

2- MEDICATION-INDUCED SALIVARY DYSFUNCTION

There are over 400 medications that are listed as having dry mouth as an adverse event .Some drugs may not actually cause impaired salivary output but may produce alteration in saliva composition that lead to the perception of oral dryness. Common Medication Categories Associated with Salivary Hypofunction

- Anticholinergics
- Antihistamines
- Antihypertensive
- Anti-Parkinson's disease

- Antiseizure
- Cytotoxic agents , Sedative and tranquilizers, Skeletal muscle relaxants, Tricyclic antidepressants

3- IMMUNE CONDITIONS

A- Mikulicz's disease previously known as benign lymphoepitheliallesion, is characterized by symmetrical lacrimal, parotid, and submandibular gland enlargement with associated lymphocytic infiltrations. Histopathologically, Mikulicz's disease is associated with prominent infiltration of IgG4-positive plasmacytes in to involved exocrine glands.

Diagnosis is based on finding of salivary gland biopsy and the absence of the alterations in peripheral blood and autoimmune serologies seen in Sjogren's syndrome

B- Sjogren's syndrome (Primary and Secondary) Sjogren's syndrome is a chronic autoimmune disease characterized by symptoms of oral and ocular dryness, exocrine dysfunction and lymphocytic infiltration, and destruction of the exocrine

4. GRANULOMATOUS CONDITIONS

A-Tuberculosis (TB) is a chronic bacterial infection, caused by Mycobacterium tuberculosis, leading to the formation of granulomas in the infected. Diagnosis depends on the identification of the bacterium. Treatment of the salivary involvement involves standard multidrug anti-TB chemotherapy.

B- Sarcoidosis is a chronic condition in which T lymphocytes, mononuclear phagocytes, and granulomas cause destruction of involved tissue. Parotid gland involvement occurs in approximately 6% of patients with sarcoidosis.

Unilateral salivary gland enlargement has been reported. Examination of a minor salivary gland biopsy specimen can confirm the diagnosis of sarcoidosis with classic noncaseating granulomata.

MANAGEMENT OF XEROSTOMIA

1- Preventing Therapy :

*The use of topical fluorides in a patient with salivary gland hypofunction is absolutely critical to control dental caries.

*avoiding cariogenic foods and beverages and brushing immediately after meals. Chronic use of alcohol and caffeine can increase oral dryness and should be minimized.

2- Symptomatic Treatment :

*Patients should be encouraged to sip water throughout the day; this will help moisten the oral cavity, hydrate the mucosa, and clear debris from the mouth.

*There are a number of oral rinses, mouthwashes, and gels available for dry mouth patients.

*The frequent use of products containing aloe vera or vitamin E should be encouraged.

*saliva replacements ('artificial salivas') can be use

3- Salivary Stimulation :

LOCAL OR TOPICAL STIMULATION: Chewing sugar-free gums or mints. Acupuncture, with application of needles in the perioral and other regions, has been proposed as a therapy for salivary gland hypofunction and xerostomia.

SYSTEMIC STIMULATION: pilocarpine. A parasympathomimetic drug Pilocarpine and Cevimeline.

- 4- Therapy of Underlying Systemic Disorders:- Anti-inflammatory therapies to treat the autoimmune exocrinopathy of Sjogren's syndrome.

SIALORRHEA

Sialorrhea is defined as an excessive secretion of saliva or hypersalivation.

The cause is an increase in saliva production or a decrease in salivary clearance.

Causes

medications (pilocarpine, cevimeline, lithium, and nitrazepam), hyperhydration , infant teething, the secretory phase of menstruation, idiopathic paroxysmal hypersalivation, heavy metal poisoning (iron, lead, arsenic, mercury, thallium), organophosphorous

(acetylcholinesterase) poisoning, nausea, gastroesophageal reflux disease, obstructive esophagitis, neurologic changes such as in a cerebral vascular accident (CVA), neuromuscular diseases, neurologic diseases, and central neurologic infections.

Minor hypersalivation may result from local irritations, such as aphthous ulcers or an ill-fitting oral prosthesis.

- Most cases of hypersalivation are a secretion clearance issue. a blood sample should be obtained and evaluated for heavy metals
- There are three types of treatments for hypersalivation:
- Physical therapy, medications, and surgery.

SALIVARY GLAND TUMORS

- The majority of salivary gland tumors (about 80%) arise in the parotid glands. The submandibular glands account for 10 to 15% of tumors, and the remaining tumors develop in the sublingual or minor salivary glands.

Approximately 80% of parotid gland tumors and approximately half of submandibular gland and minor salivary gland tumors are benign. In contrast, more than 60% of tumors in the sublingual gland are malignant.

Benign Tumors.

PLEOMORPHIC ADENOMA(most common.) The majority of these tumors are found in the parotid glands. Histologically, the lesion demonstrates both epithelial and mesenchymal elements. The epithelial cells make up a trabecular pattern that is contained within a stroma. The stroma may be chondroid, myxoid, osteoid, or fibroid. The presence of these different elements accounts for the name pleomorphic tumor or mixed tumor. One characteristic of a

pleomorphic adenoma is the presence of microscopic projections of tumor outside of the capsule.

Surgical removal with adequate margins is the principal treatment.

what are the complications of the pleomorphic adenoma ?

does pleomorphic adenoma change into malignant?

Frey syndrome

The best described and more frequent complication following parotidectomy is gustatory sweating or Frey syndrome. The pathogenesis of Frey syndrome is based on the aberrant regeneration of sectioned parasympathetic secretomotor fibres of the auriculotemporal nerve with inappropriate innervation of the cutaneous facial sweat glands that are normally innervated by sympathetic cholinergic fibres. As a consequence, Frey syndrome is a disorder characterized by unilateral sweating and flushing of the facial skin in the area of the parotid gland occurring during meals that becomes evident usually 1-12 months after surgery.

- **MONOMORPHIC ADENOMA**

A monomorphic adenoma is a tumor that is composed predominantly of one cell type.

- **PAPILLARY CYSTADENOMA LYMPHOMATOSUM**

Known as Warthin's tumor, is the second most common benign tumor of the parotid gland. It represents 6 to 10% of all parotid tumors and is most commonly located in the inferior pole of the gland, posterior to the angle of the mandible. Because this tumor contains oncocytes, it will take up technetium and will be visible on Tc 99m scintiscans.

Larger tumors that involve a significant amount of the superficial lobe of the parotid gland are best treated by a superficial parotidectomy

- **ONCOCYTOMA**

Less common benign tumors that make up less than 1% of all salivary gland neoplasms. This tumor occurs almost exclusively in the parotid glands, Bilateral presentation of this tumor can occur, and it is the second most common salivary gland tumor that occurs bilaterally (after Warthin's tumor), these tumors appear noncystic and firm. The treatment for parotid oncocytomas is superficial parotidectomy with preservation of the facial nerve.

- **BASAL CELL ADENOMA CANALICULAR**

- **ADENOMA MYOEPITHELIOMA SEBACEOUS**

- **ADENOMA**

These lesions are derived from sebaceous glands located within salivary gland tissue. The parotid gland is the most commonly involved gland. Benign forms contain well-differentiated sebaceous cells, whereas malignant forms consist of more poorly differentiated cells. Intraoral lesions are surgically removed with a border of normal tissue.

- **DUCTAL PAPILLOMA**

Ductal papillomas form a subset of benign salivary gland tumors that arise from the excretory ducts, predominantly of the minor salivary glands.

MALIGNANT TUMORS

MUCOEPIDERMOID CARCENOMA

It is the most common malignant tumor of the parotid gland and the second most common malignant tumor of the submandibular , after adenoid cystic carcinoma ADENOID CYSTIC CARCINOMA

Account for approximately 6 to 10% of all salivary gland tumors and are the most common malignant tumors of the submandibular and minor salivary glands. It is characterized by frequent late distant metastases and local recurrences, which account for low long-term survival rates.

TREATMENT. Because of the ability of this lesion to spread along the nerve sheaths, radical surgical excision of the lesion is the appropriate treatment. Even with aggressive surgical margins, tumor cells can remain, leading to long-term recurrence. Factors affecting the long-term prognosis are the size of the primary lesion, its anatomic location, the presence of metastases at the time of surgery, and facial nerve involvement.

ACINIC CELL CARCINOMA

Represents about 1% of all salivary gland tumors. Between 90 and 95% of these tumors are found in the parotid gland; almost all of the remaining tumors are located in the submandibular gland. It is the second most common malignant salivary gland tumor in children, second only to mucoepidermoid carcinoma. The superficial lobe and the inferior pole of the parotid gland are common sites of occurrence. Bilateral involvement of the parotid gland has been reported in approximately 3% of cases. Treatment consists of superficial parotidectomy, with facial nerve preservation if possible. When these tumors are found in the submandibular gland, total gland removal is the treatment of choice

CARCINOMA EX PLEOMORPHIC ADENOMA

Is a malignant tumor that arises within a preexisting pleomorphic adenoma. The malignant cells in this tumor are epithelial in origin. This tumor represents 2 to 5% of all salivary gland tumors. Surgical removal with postoperative radiation therapy is the recommended treatment. Early removal of benign parotid gland tumors is recommended to avoid the development of this lesion.

Treatments

For patients of any age involve surgical removal and adjuvant radiotherapy for more advanced cancers.

Efficacy of treatment of malignant tumors is dependent upon stage, location, presence of perineural invasion, treatment modality, histologic type, and presence of regional invasion.

ADENOCARCINOMA

It is a tumor arising from salivary duct epithelium.

- The tumors may be present for weeks, months, or even several years, prior to diagnosis
- A mass or lump on the side of the face may be observed, since mostly the parotid gland is affected
- Most tumors are locally infiltrative, but some are well-defined
- Some individuals with basal cell adenocarcinomas may have other unrelated skin tumors, such as adnexal tumors of skin
- Most tumors are asymptomatic and no significant signs and symptoms are observed
- Neurological signs and symptoms, such as facial muscle weakness and pain, due to facial nerve involvement may be seen (in 1 in 4 cases)
- Pain while eating/chewing
- Persistent facial pain at the site of swelling of the tumor; this requires an immediate checkup by a healthcare provider
- Tumor infiltration into the bone
- Involvement of the lymphatic system may be seen in 25% of the cases

LYMPHOMA

Primary lymphoma of the salivary glands probably arises from lymph tissue within the glands. However, primary lymphoma of the salivary glands is rare. The major forms of lymphoma are non- Hodgkin's lymphoma (NHL) and Hodgkin's disease. Histologic examination demonstrates B-cell lymphoma tissue that originates from lymphoid tissue associated with malignant mucosa.

MYOEPIHELIAL CARCINOMA

Myoepithelial carcinoma or malignant myoepithelioma is a very rare malignant salivary gland neoplasm with good short-term survival and poor long-term survival. Due to their morphologic heterogeneity, these neoplasms can be confused easily with other tumors. Early and aggressive surgical removal with close follow- up is required.