

A Class II incisor relationship is defined as being present when the lower incisor edges occlude posterior to the cingulum plateau of the upper incisors. Class II division 2 includes those malocclusions where the upper central incisors are retroclined. The overjet is usually minimal, but may be increased. The prevalence of this malocclusion in a Caucasian population is approximately 10 percent.

Aetiology

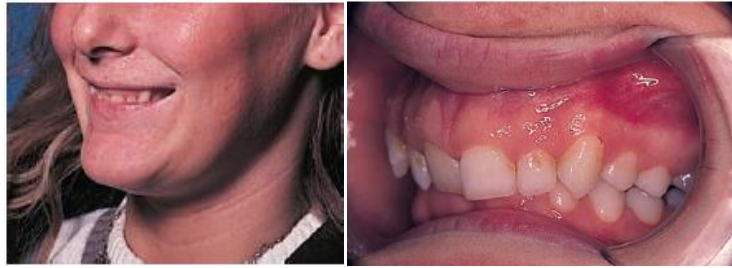1. Skeletal pattern

Class II division 2 malocclusion is commonly associated with a mild Class II skeletal pattern, but may also occur in association with a Class I or even a Class III dental base relationship. Where the skeletal pattern is more markedly Class II the upper incisors usually lie outside the control of the lower lip, resulting in a Class II division 1 relationship, but where the lower lip line is high relative to the upper incisors a Class II division 2 malocclusion can result.

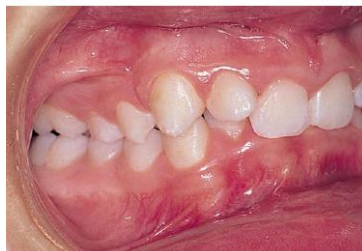The vertical dimension is also important in the aetiology of Class II division 2 malocclusions, and typically is reduced. A reduced lower face height occurs in conjunction with a Class II jaw relationship often results in the absence of an occlusal stop to the lower incisors, which then continue to erupt leading to an increased overbite. A reduced lower facial height is associated with a forward rotational pattern of growth. This usually means that the mandible becomes more prognathic with growth. While this pattern of growth is helpful in reducing the severity of a Class II skeletal pattern, it also has the effect of increasing overbite

2. Soft tissue causes

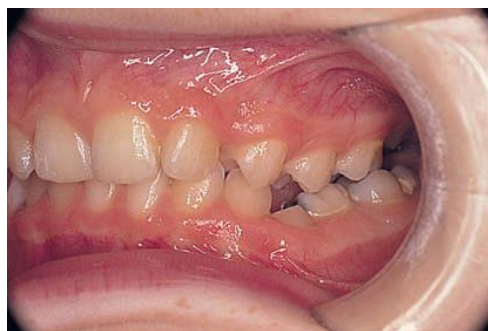The influence of the soft tissues in Class II division 2 malocclusions is usually mediated by the skeletal pattern. If the lower facial height is reduced, the lower lip line will effectively be higher relative to the crown of the upper incisors (more than the normal one-third coverage). A high lower lip line will tend to retrocline the upper incisors.



In some cases, the upper lateral incisors, which have a shorter crown length, will escape the action of the lower lip and therefore lie at an average inclination, whereas the central incisors are retroclined.



Class II division 2 incisor relationships may also result from bimaxillary retroclination caused by active muscular lips, irrespective of the skeletal pattern.



3. Dental factors

Crowding is commonly seen in conjunction with a Class II division 2 incisor relationship. In addition, any pre-existing crowding is exacerbated because retroclination of the upper central incisors results in them being positioned in an arc of smaller circumference.

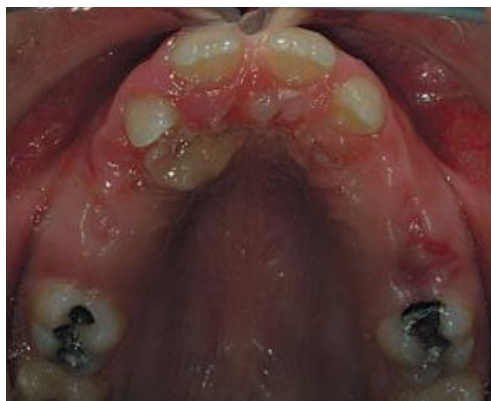In the upper labial segment this usually manifests in a lack of space for the upper lateral incisors which are crowded and are typically rotated mesiolabially out of the arch. In the same manner lower arch crowding is often exacerbated

by retroclination of the lower labial segment. This can occur because the lower labial segment becomes 'trapped' lingually to the upper labial segment by an increased overbite. Lack of an effective occlusal stop to eruption of the lower incisors may result in their continued development, giving rise to an increased overbite.

This may be due to a Class II skeletal pattern or retroclination of the incisors as a result of the action of the lips, leading to an increased inter-incisal angle. In addition, it has been found that in some Class II division 2 cases, the upper central incisors exhibit a more acute crown and root angulation. However, rather than being the cause, this crown–root angulation could itself be due to the action of a high lower lip line causing deflection of the crown of the tooth relative to the root after eruption.

4. Occlusal features

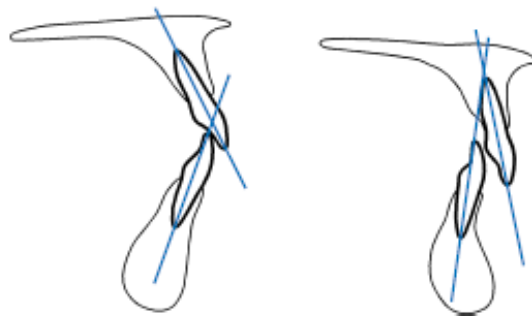
The upper central incisors are retroclined and the lateral incisors are at an average angulation or are proclined, depending upon their position relative to the lower lip. Where the lower lip line is very high, the lateral incisors may be retroclined. The more severe malocclusions occur either where the underlying skeletal pattern is more Class II or where the lip musculature is active, causing bimaxillary retroclination. In mild cases the lower incisors occlude with the upper incisors, but in patients with a more severe Class II skeletal pattern the overbite may be complete onto the palatal mucosa. In a small proportion of cases, the lower incisors may cause ulceration of the palatal tissues and, in some patients, retroclination of the upper incisors leads to stripping of the labial gingivae of the lower incisors. In these cases, the overbite is described as traumatic, but fortunately both are comparatively rare.



Another feature associated with a more severe underlying Class II skeletal pattern is lingual crossbite of the first and occasionally the second premolars.

Management

Stable correction of a Class II division 2 incisor relationship is difficult as it requires not only reduction of the increased overbite but also reduction of the inter-incisal angle which classically is increased. If re-eruption of the incisors and, therefore, an increase in overbite is to be resisted, the inter-incisal angle needs to be reduced, preferably close to 135° , so that an effective occlusal stop is created. In addition, it has been shown that stability is increased if at the end of treatment the lower incisor edge lies 0–2 mm anterior to the mid-point of the root axis of the upper incisors.



The treatment approach chosen for a particular patient will depend upon the aetiology of the malocclusion, the presence and degree of crowding, the patient's profile, their age and their wishes.

It is advisable in the management of Class II division 2 malocclusions to minimize lingual movement of the lower incisors in order to avoid any possibility of worsening the patient's overbite; indeed, it may be preferable to accept some proclination of the lower incisors and permanent retention rather than run this risk. Certainly, extraction of permanent teeth in the lower arch in Class II division 2 malocclusions should be approached with caution.

Space closure occurs less readily in patients with reduced vertical skeletal proportions, which are commonly associated with Class II division 2 malocclusions, than in those with increased lower face heights. In view of this,

it is not surprising that Class II division 2 malocclusions are managed more frequently on a non-extraction basis, particularly in the lower arch, than are other types of malocclusion.

Proclination of the lower incisors is helpful in reducing both overbite and the inter-incisal angle. In general, proclination of the lower labial segment should be considered unstable, but it has been argued that in some Class II division 2 malocclusions due to the increased overbite, the lower labial segment is trapped behind the upper labial segment, resulting in retroclination of the lower incisors and constriction of the lower intercanine width with growth.

Approaches to the reduction of overbite

- **Intrusion of the incisors**

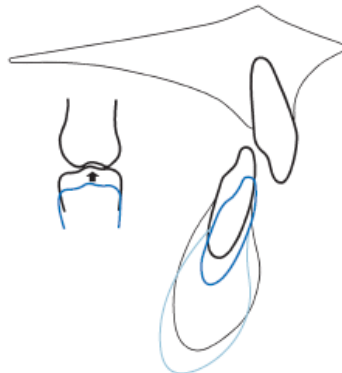
Actual intrusion of the incisors is difficult to achieve. Fixed appliances are necessary and the mechanics employed pit intrusion of the incisors against extrusion of the buccal segment teeth; as it is easier to move the molars occlusally than to intrude the incisors into bone, the former tends to predominate. In practice, the effects achieved are relative intrusion, where the incisors are held still while vertical growth of the face occurs around them, plus extrusion of the molars.

Increasing anchorage by using temporary anchorage screws or by reinforcing the anchorage unit posteriorly by including second permanent molars (or even third molars in adults) will aid intrusion of the incisors and help to limit extrusion of the molars .

Eruption of the molars

Use of a flat anterior bite-plane on an upper removable appliance to free the occlusion of the buccal segment teeth will, if worn conscientiously, limit further occlusal movement of the incisors and allow the lower molars to erupt, thus reducing the overbite. This method requires a growing patient to accommodate the increase in vertical dimension that results, otherwise the molars will re-intrude under the forces of occlusion once the appliance is withdrawn. However, this tendency can be resisted to a degree if the

treatment creates an effective occlusal stop and reduction of the inter-incisal angle.



- **Extrusion of the molars**

As mentioned, the major effect of attempting intrusion of the incisors is often extrusion of the molars. This may be advantageous in Class II division 2 cases as this type of malocclusion is usually associated with reduced vertical proportions. Again, vertical growth is required if the overbite reduction achieved in this way is to be stable.

- **Proclination of the lower incisors**

Advancement of the lower labial segment anteriorly will result in a reduction of overbite as the incisors tip labially. However, in a few cases where the lower incisors have been trapped behind the upper labial segment by an increased overbite, fitting of an upper bite-plane appliance may allow the lower labial segment to procline spontaneously.

- **Surgery**

In adults with a markedly increased overbite and those patients where the underlying skeletal pattern is more markedly Class II, a combination of orthodontics and surgery is required.

Practical management

Where treatment is indicated there are three possible treatment modalities as described below:

1. Fixed appliances

When fixed appliances are used the inter-incisal angle can be reduced by palatal/lingual root torque or by proclination of the lower incisors.

The relative role of these two approaches in the management of a particular malocclusion is a matter of fine judgement.

Torquing of incisor apices is dependent upon the presence of sufficient cortical bone palatally/lingually and places a considerable strain on anchorage. This type of movement is also more likely to result in resorption of the root apices than other types of tooth movement.

Mild crowding in the lower arch may be eliminated by forward movement of the lower labial segment and/or interdental stripping.

If crowding is more marked, extractions will be required and a lower fixed appliance used to ensure that space closure occurs without movement of the lower incisor edges lingually. For this reason lower second premolars are often extracted rather than first premolars.

Space for correction of the incisor relationship and for relief of crowding, if indicated, can be gained by upper arch extractions or by distal movement of the upper buccal segments. If headgear is used for anchorage or distal movement, a direction of pull below the occlusal plane (cervical pull) is usually indicated in Class II division 2 malocclusions as the vertical facial proportions are reduced.

Following treatment, the prognosis for the corrected position is good as cuspal interlock will help to prevent relapse.

The retention phase is particularly important in Class II division 2 malocclusions, with regard to the following:

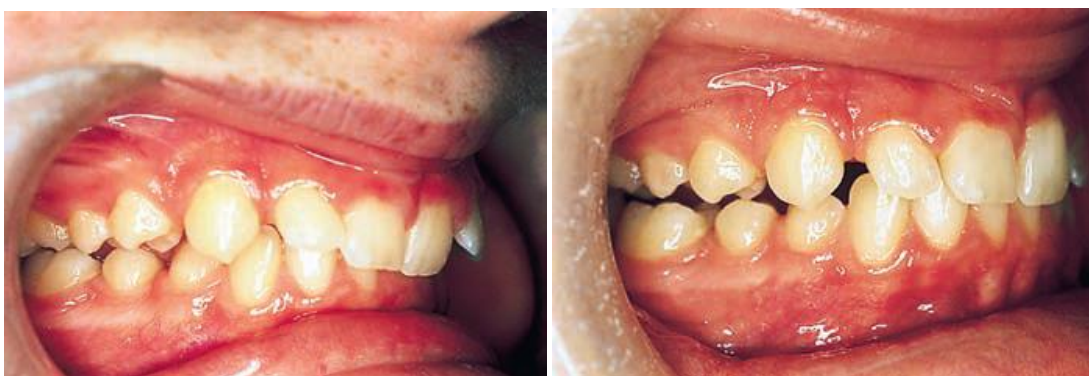- To prevent an increase in overbite.
- To retain any de-rotated teeth, for example, the upper lateral incisors.
- To maintain alignment of the lower labial segment, particularly if it has been proclined during treatment.

2. Functional appliances

Functional appliances can be utilized in the correction of Class II division 2 malocclusions in growing patients with a mild to moderate Class II skeletal pattern.

Reduction of the inter-incisal angle is achieved mainly by proclination of the upper incisors, although some proclination of the lower labial segment may occur as a result of the functional appliance. If the upper incisors are retroclined it may be helpful to have a pre-functional phase to procline them and, if indicated to ensure the correct buccolingual arch relationship at the end of treatment, to expand the upper arch.

Alternatively a sectional-fixed appliance can be placed on the upper labial segment teeth to achieve their alignment during the functional phase. After anteroposterior correction with the functional appliance, fixed appliances are required to detail the occlusion.



3. Surgery

A stable aesthetic orthodontic correction may not be possible in patients with an unfavourable skeletal pattern anteroposteriorly and/or vertically, particularly if growth is complete. In these cases, surgery may be necessary.

A phase of presurgical orthodontics is required to align the teeth. However, arch levelling is usually not completed as extrusion of the molars is much more easily accomplished after surgery.