

**Republic of Iraq
Ministry of Higher Education
And scientific Research
University of Baghdad
College of Dentistry**



Extraction in orthodontic

A project

Submitted to Collage of Dentistry, University of Baghdad. Department of orthodontics in fulfillment for the requirement to award the degree B.D.S

Done by

Montather khalouq Abraham
5th Grade

Supervisor

Dr. Haider Mohammed Ali
B.D.S, M.S.C lecturer

Baghdad Iraq

2017_1438

List of content

List of content	II
List of figures	IV
Introduction	1
Chapter one	2
Review of literature	2
1.1 EXTRACTION GUIDELINES	2
<i>1.1.1 Less than 4 mm arch length discrepancy:</i>	<i>2</i>
<i>1.1.2 Arch length discrepancy 5 to 9 mm:</i>	<i>2</i>
<i>1.1.3 Arch length discrepancy 10 mm or more:</i>	<i>2</i>
1.2 SELECTION OF TEETH TO BE EXTRACTED	3
1.3 TYPES OF EXTRACTION IN ORTHODONTICS	4
<i>1.3.1 Balancing Extractions</i>	<i>4</i>
<i>1.3.2 Compensating Extractions</i>	<i>4</i>
<i>1.3.3 Enforced Extractions</i>	<i>5</i>
<i>1.3.4 Therapeutic extraction</i>	<i>6</i>
<i>1.3.5 Wilkinson extraction</i>	<i>6</i>
1.4 TEETH TO BE EXTRACTED	6
<i>1.4.1 Incisors</i>	<i>6</i>
<i>1.4.2 Canines</i>	<i>9</i>
<i>1.4.3 Permanent premolars</i>	<i>10</i>
<i>1.4.4 First permanent molars</i>	<i>13</i>
<i>1.4.5 Second permanent molars</i>	<i>15</i>
<i>1.4.6 Third permanent molars</i>	<i>17</i>
1.5 SERIAL EXTRACTION	18
<i>1.5.1 Advantages of Serial Extractions</i>	<i>19</i>
<i>1.5.2 Disadvantages of Serial Extractions</i>	<i>19</i>
<i>1.5.3 Complications of Serial Extractions</i>	<i>19</i>

<i>1.5.4 Indications For serial Extractions</i>	20
<i>1.5.5 Contra-indication for serial extractions</i>	20
CHAPTER TWO	21
MATERIAL METHOD	21
CHAPTER THREE	22
RESULT	22
CHAPTER FOUR	27
DISCUSSION	27
CHAPTER FIVE	29
SUGGESTION	29
REFERENCE	30

List of figures

Figure 1.2.balancing extraction	4
Figure 1.3.Compensating extraction	5
Figure 1.6.Enforced extraction of carious tooth	5
Figure 1.5.Enforced extraction of fracture tooth.....	5
Figure 1.4.Enforced extraction of impacted second molar	5
Figure 1.7.Poor periodontal teeth health	5
Figure 1.8.Therapeutic extractions.....	6
Figure 1.9.Crowding of 5mm localized in lower labial segment	7
Figure 1.8.Single lower incisor excluded from the arch	7
Figure 1.10.Deep openbite	8
Figure 1.12.Maxillary central incisor with dilacerated root	9
Figure 1.11.Peg shaped lateral inciser	9
Figure 1.13.Impacted upper incisors.....	9
Figure 1.14.Orthopantomgraphe view impacted canine	9
Figure 1.15.Occlusal view of impacted canine.....	9
Figure 1.6.Extraction of first premolar for proper alignment of caine.....	11
Figure 1.17.Impacted second premolars	12
Figure 1.18.Hypomineralized permanent molars.....	15
Figure 1.19.Impacted third and second molar	16
Figure 2.1 sample of survey paper	21
Table 3.1.How do you decide extraction in your clinic	22
Chart 3.1.Percentage of answers of question one	22
Table 3.2.In cl I molars and canines relationship, we have anterior crowding more than 6 mm in upper arch do you prefer	23
Chart 3.2.Precentage of answers of questions two	23

Table 3.3. In cl I molars and canines relationship , we have have anterior crowding more than 6 mm in lower arch do you prefer..... 24

Chart 3.3.Percentage of answers of questions two24

Table 3.4.Which approach do you follow in your clinic25

Chart 3.4.Percentage of answers of questions four25

Table 3.5 Do you set your anchorage posteriorly (TPA or TADs) and placing working stainless steel wires before doing extraction? 26

Chart 3.5 percentage of answers of question five26

Introduction

The role of extractions in orthodontic treatment has been a controversial subject for over a century. It is fair to say that even today, opinion is divided on whether extractions are used too frequently in the correction of malocclusion.

Recently, the extraction debate has reopened, with some individuals believing that expansion of the jaws and retraining of posture can obviate the need for extractions and produce stable results (**Travess et al. 2004**).

These claims are for the most part unsubstantiated. If teeth are genuinely crowded as opposed to being irregular then arch alignment can be achieved by Enlargement of the arch form or Reduction in tooth size or Reduction in tooth number. The reduction in tooth number is usually achieved with extractions and these cases ideally need to be compared with treated non extraction cases with spacing, cases treated by arch expansion to accommodate crowding and untreated normal occlusions. In a review of these issues it was concluded that arch length reduces in most cases, including untreated normal occlusion (**Travess et al.2004**).

Any lateral expansion across the mandibular canines decreases after treatment but this is also seen in those cases which have no orthodontic treatment. It was further recognized that mandibular anterior crowding is a continuing phenomenon seen in patients into the fourth decade and likely beyond. The degree of anterior crowding seen at the end of retention is variable and unpredictable (**Travess et al.2004**).

Chapter one

Review of literature

1.1 Extraction Guidelines

Extraction Contemporary guidelines for orthodontic in Class I crowding cases can be summarized as follows:

1.1.1 Less than 4 mm arch length discrepancy:

Extraction rarely indicated (only if there is severe incisor protrusion or in a few instances, a severe vertical discrepancy) (**Phulari.2011**).

Some cases, this amount of crowding can be managed without arch expansion by slightly reducing the selected teeth, being careful to coordinate the amount of reduction in the upper and lower arch (**Proffit et al.2013**).

1.1.2 Arch length discrepancy 5 to 9 mm:

Non-extraction or extraction treatment possible (**Phulari.2011, Proffit et al 2013**).

The decision depends on both the hard- and soft-tissue characteristics of the patient and on how the final position of the incisors will be controlled, any of several different teeth could be chosen for extraction. Non-extraction treatment usually requires transverse expansion across the molars and premolars, and additional treatment time if the posterior teeth are to be moved distally, to increase arch length (**Proffit et al. 2013**) (**Jeryl et al.2015**).

1.1.3 Arch length discrepancy 10 mm or more:

Extraction almost always required (**Phulari.2011, Proffit et al.2013**).

For these patients, the amount of crowding virtually equals the amount of tooth mass being removed, and there would be little or no effect on lip support and facial appearance. The extraction choice is four first premolars or perhaps upper first

premolars and mandibular lateral incisors. Second premolar or molar extraction rarely is satisfactory because it does not provide enough space near crowded anterior teeth or options to correct midline discrepancies (Proffit et al.2013).

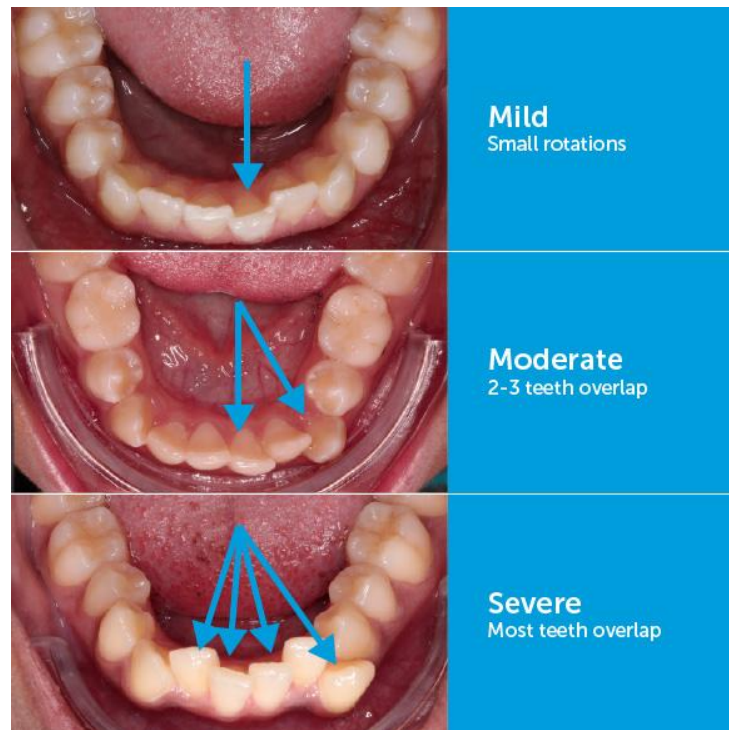


Figure 1.1. Crowding level

1.2 Selection of teeth to be extracted

Extraction for orthodontic reasons will be governed by:

1- Condition of the teeth: Fractured, high grossly carious teeth, root canal treated teeth and teeth with large restorations are preferred for extraction over healthy teeth. The main consideration is the long-term prognosis for the tooth rather than the appearance (Phulari.2011, Millet et al.2005).

2- Position of the crowding: Crowding in one part of the arch is more readily corrected if extractions are done in that part rather than a remote area of the arch. However, incisor crowding is usually relieved by premolar extraction as it gives a more pleasing appearance and occlusal balance than with incisor extraction. The first premolar, positioned in the center of each quadrant, is usually near the area of crowding whether

in the anterior or buccal segment. Hence, it is also the tooth most frequently extracted along with orthodontic treatment (**Phulari.2011, Millet et al.2005**).

3- Position of the teeth: Grossly malpositioned teeth which are difficult to align, may often be the teeth of choice for extraction. The position of the apex of the tooth must be considered as it is more difficult to move the apex than the crown (**Phulari.2011, Millet et al.2005**).

1.3 Types of Extraction in orthodontics

1.3.1 *Balancing Extractions*

Balancing extractions may be defined as the removal of a tooth on the opposite side the same arch (although not necessarily the same) in order to preserve symmetry (**Phulari. 2011**).

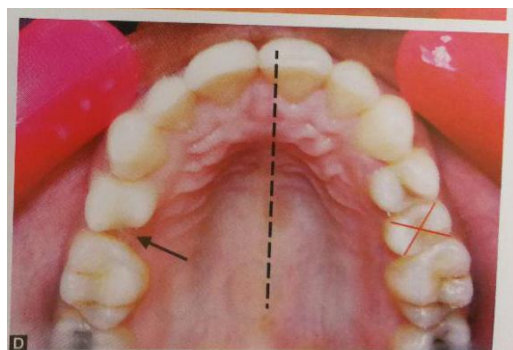


Figure 1.2.balancing extraction

1.3.2 *Compensating Extractions*

Removal of the equivalent tooth in the opposing arch to maintain buccal occlusion, if the third molar is extracted in the right quadrant of the maxillary arch then the third molar in the right quadrant of the mandibular arch is also extracted. This type of extraction is called as compensatory extraction (**Phulari.2011**).

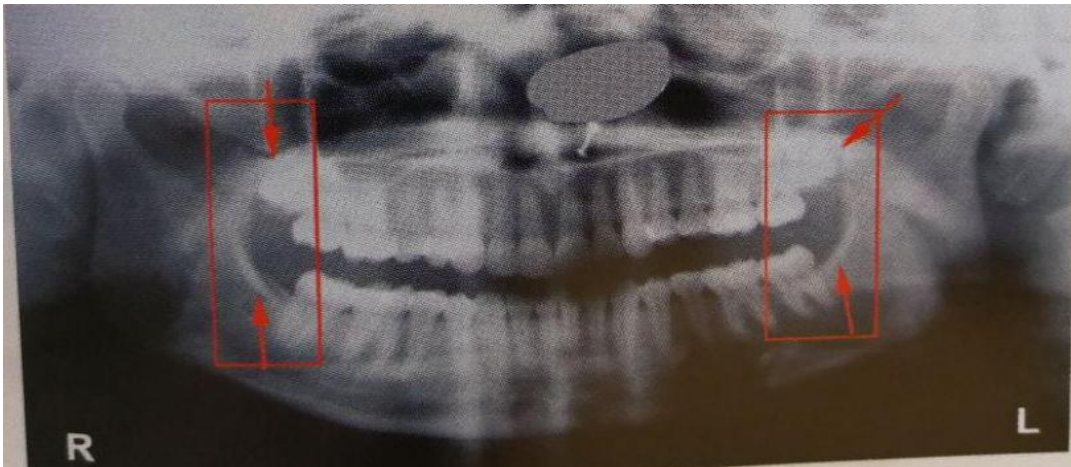


Figure 1.3. Compensating extraction

1.3.3 Enforced Extractions

These extractions are carried out because they are necessary as in the case of grossly decayed teeth, poor periodontal status, fractured tooth, impacted tooth, etc (Phulari.2011).

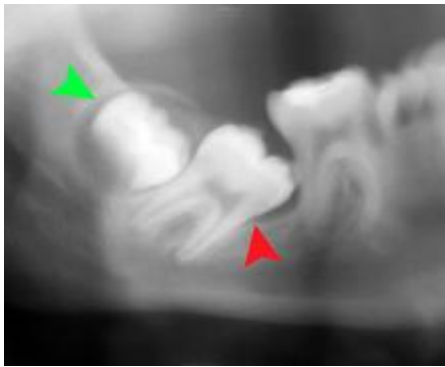


Figure 1.4. Enforced extraction of impacted second molar

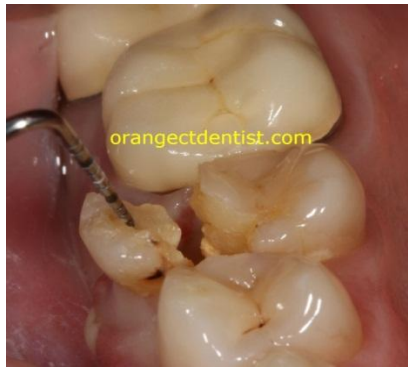

Figure 1.5. Enforced extraction of fracture tooth

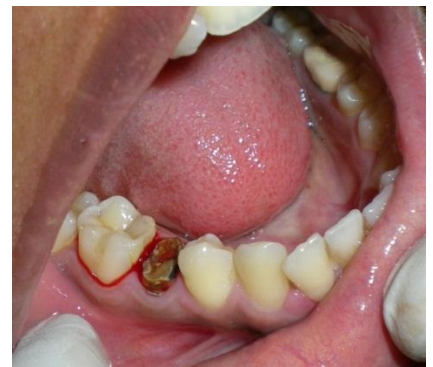

Figure 1.6. Enforced extraction of carious tooth

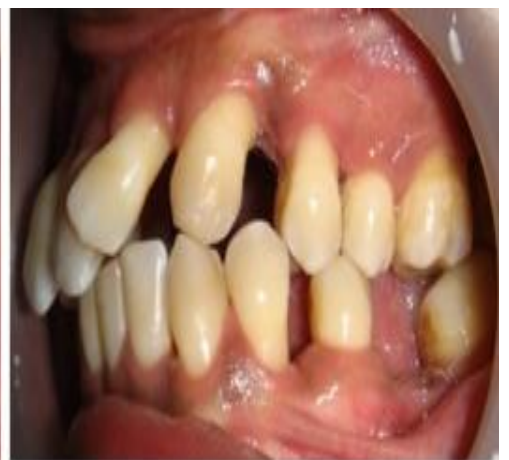
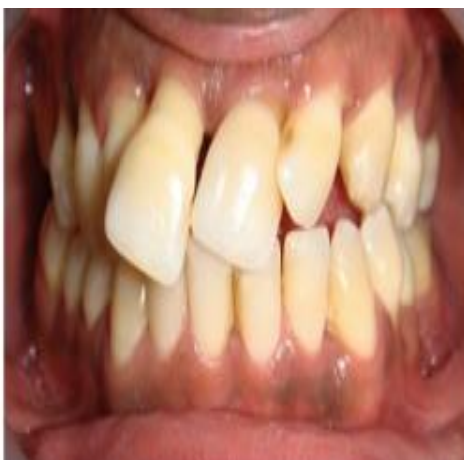
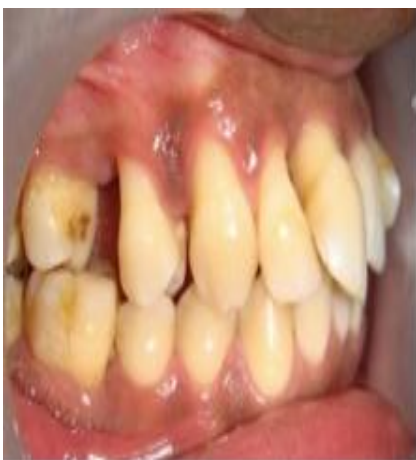Figure 1.7. Poor periodontal teeth health

1.3.4 Therapeutic extraction

Certain sound healthy teeth may have to be sacrificed to facilitate proper alignment of other teeth in cases of severe arch length-tooth material discrepancy. Such extraction of sound teeth or the purpose of orthodontic treatment is called as therapeutic extraction (Phulari.2011).

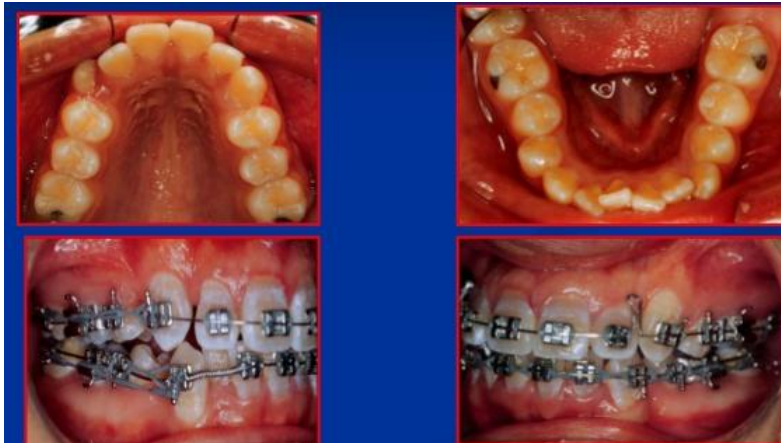

Figure 1.8. Therapeutic extractions

1.3.5 Wilkinson extraction

Wilkinson advocated extraction of entire first molars between the age of 8.5 years and 9.5 years, as this:

- Prevents impaction of third molars.
- It relieves crowding in the dental arch.
- It helps in decreasing the incidence and occurrence of dental caries (Phulari.2011).

1.4 Teeth to be extracted

1.4.1 Incisors

1.4.1.1 lower incisors

1.4.1.1.1 Indications for lower incisor extraction:

- Incisor has poor prognosis or compromised periodontal support, figure 1.7 (Mitchell.2007, Alcock et al .2009, Phulari.2011).
- Distally tipped canines (Alcock et al.2009).

- Distally fanned lower incisors (**Alcock et al.2009**).
- Excessive size of lower incisor teeth (**Alcock et al.2009**).
- Ectopic eruption of lower lateral incisor (**Alcock et al.2009**).
- Single lower incisor excluded from the arch and remaining incisors well aligned figure 1.8 (**Alcock et al.2009**).
- Crowding of 5mm (equivalent to a lower incisor) localized in lower labial segment with buccal segments well intercusped (**Alcock et al. 2009, Mitchell.2007, Jeryl et al .2015**).
- Class III cases where the upper is well aligned and want to narrow the lower intercanine width and retrocline lower incisors to improve the incisor relationship (**Alcock et al.2009, Mitchell.2007, Jeryl et al.2015**).
- Adult presenting with full unit Class II in the buccal segment and 5 mm crowding in the lower arch extraction of 2 premolars in the lower arch may be extremely challenging (**Alcock et al.2009, Mitchell.2007, Jeryl et al.2015**).
- Long term stability, more favorable than with premolar extraction (**Alcock et al.2009**).

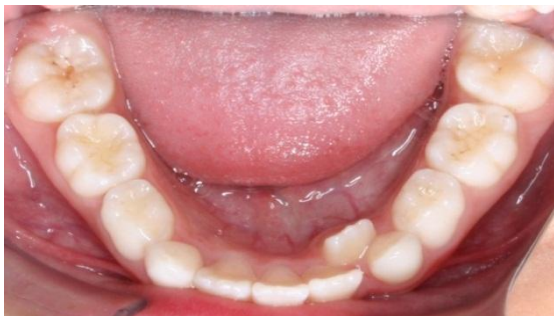

Figure 1.8. Single lower incisor excluded from the arch

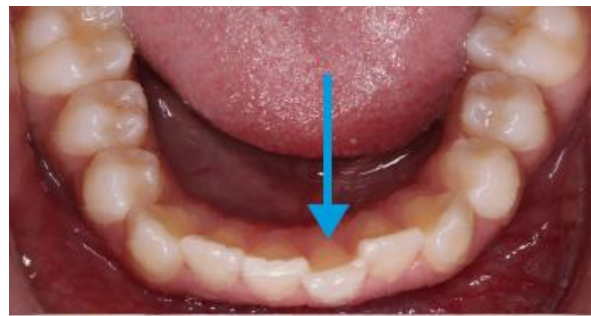

Figure 1.9. Crowding of 5mm localized in lower labial segment

1.4.1.1.2 Contraindication of extraction:

- Deep openbite.
- Poor buccal segment relationship.
- Mesially inclined canines.
- Poor prognosis of posterior teeth figure 1.6.
- Mild < 3mm or severe >7mm, lower incisor crowding Problems associated.

with lower incisor extraction.

- Loss of interdental papillae.
- Occlusal interferences between 3 and 2 (**Alcock et al.2009**).

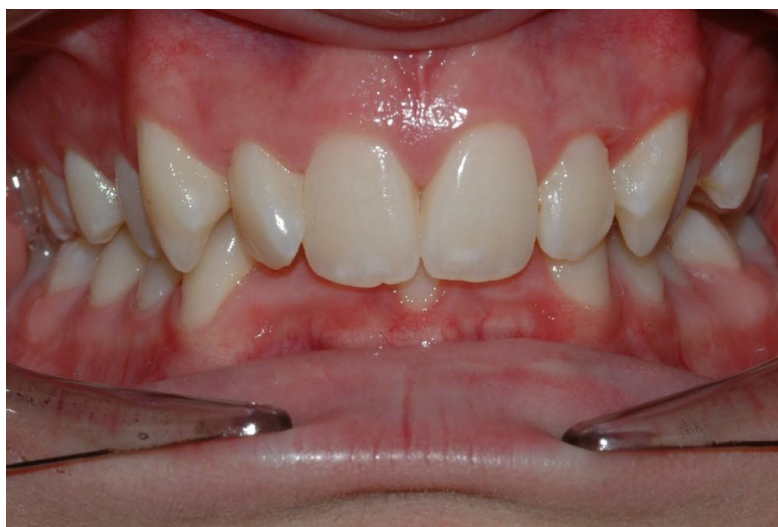

Figure 1.10. Deep openbite

1.4.1.2 Upper incisors

Incisors are esthetically the most prominent teeth due to their position in the arches. Thus, extraction of incisors, especially which of upper centrals is rarely undertaken unless their condition necessitates their extraction (**Phulari.2011**).

1.4.1.2.1 Indications for extraction

- Unfavorably impacted upper incisors (**Phulari.2011**).
- Grossly carious incisor that cannot be restored (**Phulari.2011**).
- Grossly decayed tooth that cannot be conserved (**Phulari.2011**).
- Maxillary central incisor with severely dilacerated root, which cannot be moved orthodontically (**Phulari.2011**).
- Trauma irreparable incisors by fracture (**Phulari.2011**).
- If peg shaped, small or invaginated (**Alcock et al.2009**).
- When one maxillary lateral is congenitally missing, the lateral incisors on the other side of the arch may have to be extracted so as to balance the arch symmetry (**Phulari.2011**).

- Buccally or lingually blocked out lateral incisor with good contact between central incisor and canine (**Phulari.2011**).
- When one maxillary lateral is congenitally missing, the lateral incisors on the other side of the arch may have to be extracted so as to balance the arch symmetry (**Phulari.2011**).

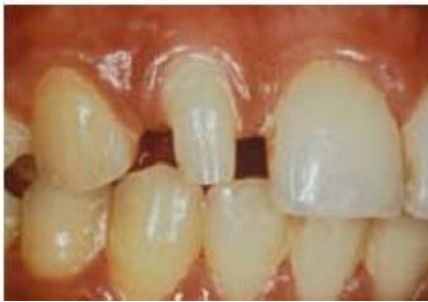

Figure 1.11. Peg shaped lateral inciser

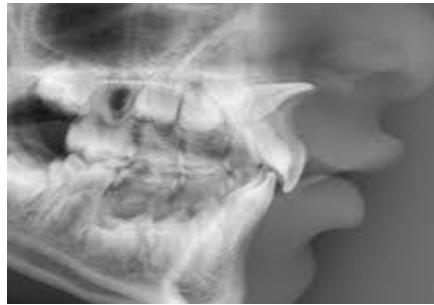

Figure 1.12. Maxillary central incisor with dilacerated root

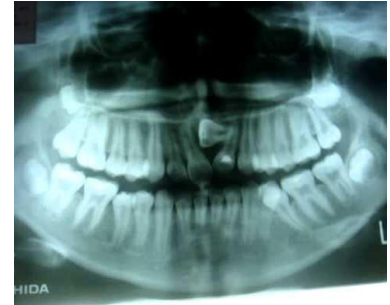

Figure 1.13. Impacted upper incisors

1.4.2 Canines

Rarely tooth of choice to extract

- Aesthetic important - canine eminence
- Functionally important - canine guidance
- Long root - useful restoratively
- Contact between 2 and 4 is not ideal - occlusal interferences (**Alcock et al.2009**).

1.4.2.1 Indication:

Canine may be extracted in one of the following instances:

1 Mandibular canine may be extracted when it is likely to be very difficult to align, eg when it is excluded from the arch and the apex is severely malpositioned or when it is unfavorably impacted (**Alcock et al.2009**).

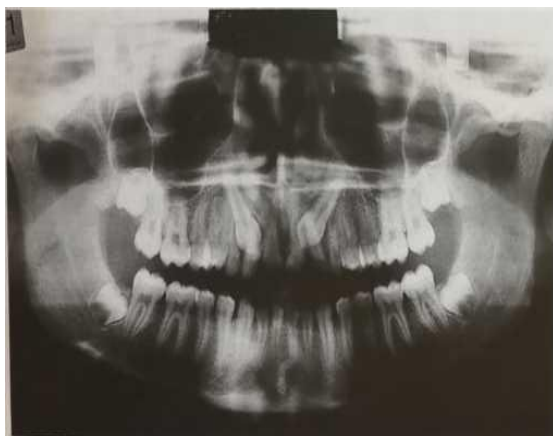

Figure 1.14. Orthopantomgraphe view impacted canine

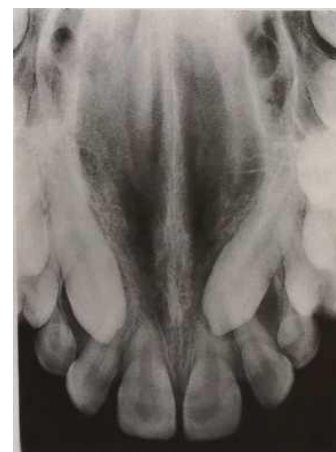

Figure 1.15. Occlusal view of impacted canine

2-Upper canines develop far away from their final location and have a long path of eruption from their development site to their final position in the oral cavity. Therefore, they are commonly impacted or ectopic and their alignment is difficult, even impossible, Extraction may be required in such cases (**Alcock et al.2009, Phulari.2011**).

3- When upper canine is completely excluded from the arch and approximal contact between lateral incisor and first premolar is good, extraction of the canine may be considered (**Alcock et al.2009, Phulari.2011**).

1.4.2.2 The following factors need to be taken into consideration in deciding on treatment.

- 1 The general state of oral health and the patient's age and desire to accept treatment.
- 2 The position of the unerupted tooth.
- 3 The space available in the dental arch.
- 4 The condition, position and appearance of neighboring teeth, i.e. the lateral incisor, first premolar and primary canine.
- 5 The occlusal relationship of the dental arches (**Foster.1990**).

1.4.3 Permenant premolars

1.4.3.1 .Lower first premolar

1.4.3.1.1.Indications for extraction:

- Tooth most commonly extracted for relief of moderate to severe lower arch crowding (figure 1.1) (**Alcock et al.2009, Phulari.2011**).
- Usefully sited to relieve anterior crowding and to correct molar relationship (figure 1.1) (**Alcock et al.2009**).
- In class II malocclusions spontaneous improvement in dental arch relationship occurs with age if premolars are extracted in mixed/early permanent dentition (**Alcock et al.2009**).

- Spontaneous improvement is rarely sufficient to correct CI II molar relationship, active treatment is required (**Alcock et al.2009**).
- Approximately 60% of lower 5/3 contact points are satisfactory without active treatment (**Alcock et al.2009**).
- First premolars are also extracted as a part of serial extraction procedure undertaken in early mixed dentition period to intercept the development of crowding in the arches (**Phulari. 2011**).

1.4.3.1.2 Contraindication:

- Other teeth of poor prognosis, figure 1.4 (**Alcock et al.2009**).
- Mild crowding (**Alcock et al.2009**).
- Risk of excessive lingual movement of lower incisors (**Alcock et al.2009**)

1.4.3.2 Upper first premolar

1.4.3.2.1 Indications for extraction

- In high anchorage cases, it is preferred over second premolars.
- Commonest tooth to extract for upper arch crowding Bradbury, 1985 (**Phulari.2011**).
- Space is conveniently sighted to reduce overjet.
- It is the first tooth to erupt in the buccal segment - early extraction is possible
- First premolars are also extracted as a part of serial extraction procedure undertaken in early mixed dentition period to intercept the development of crowding in the arches (**Phulari.2011**).

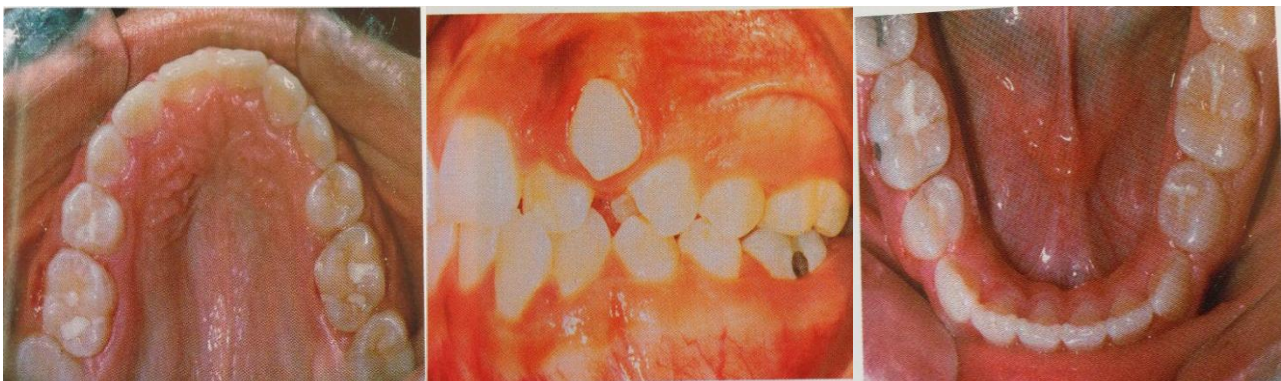

Figure 1.6.Extraction of first premolar for proper alignment of caine

1.4.3.2.2 Contra-indications

- Distally inclined canines (Choo Yew On et al .2011).
- Poor prognosis of canines - grossly carious or hypoplastic (extract canine instead) **(Choo Yew On et al.2011)**.
- Grossly displaced canines ; good contact between lateral incisor & 1st
- Premolar (extract canine) **(Choo Yew On et al.2011)**.
- Class III incisor relationship **(Choo Yew On et al.2011)**.

1.4.3.3 Lower second premolars

1.4.3.3.1 Indications for extraction of premolars.

- For relief of mild-moderate crowding Tulloch, 1978 **(Michelle.2007, Phulari.2011)**.
- May avoid excessive lingual movement of lower incisors (which may occur with first premolar extraction), alters anchorage balance.
- Better sited than first premolar for correction of molar relationship and posterior crowding.
- . Unfavorably impacted second premolars **(Phulari.2011)**.
- If .5 is small or hypoplastic or grossly carious or periodontally compromised second premolar **(Alcock et al.2009)**.

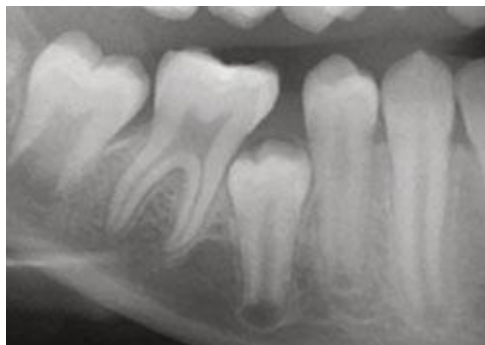

Figure 1.17.Impacted second premolars

1.4.3.3.2 Contraindication of extraction

- Fixed appliance usually necessary to establish good 6-4 contact.

- Never tooth of choice to extract - functionally important (**Alcock et al.2009, Michelle.2007**).

1.4.3.4 Upper second premolar

1.4.3.4.1 Indications for extraction:

- Extracted in preference to the 4 if crowding or overjet is less severe in upper arch
- Extraction of .5 rather than 4 may avoid over retraction of the labial segment, useful with class III malocclusions.
- If .5 is excluded from the arch e.g. if early loss of deciduous second molar (**Jeryl et al .2015, Mitchell.2007, Phulari.2011**).
- If .5 is small or hypoplastic or grossly carious or periodontally compromised second premolar (**Jeryl et al.2015, Phulari.2011**).

1.4.3.4.2 Contraindication for extraction

- Fixed appliance often necessary to establish satisfactory contact between 4 and 6
- As with the lower first molar this is rarely the tooth of choice to extract (**Alcock et al.2009**).

1.4.4 First permanent molars

First molars are regarded as the cornerstones of dental arches and are considered to play a key role in the establishment of occlusion by Angle. They are usually not extracted unless otherwise indicated (**Phulari.2011**).

Extraction of first permanent molars often makes orthodontic treatment more difficult and prolonged. However, their extraction may need to be considered due to their limited prognosis (**Mitchell.2007**).

Extraction of first molars may be advantageous in open bite cases as this may lead to deepening of the bite (**Phulari.2011**).

1.4.4.1 Extraction of first permanent molars is not advisable due to the following reasons:

- Extraction of first molars does not provide adequate space for the relief of anterior crowding.
- First molar extraction can lead to deepening of the bite, which may not be desirable in all cases.
- Following first molar extraction, the second premolar may tip into the extraction space.
- Masticatory function of the patient may get affected. **(Phulari.2011)**.

1.4.4.2 Lower first molar

1.4.4.2.1 Indications for extraction

- If tooth is carious consider the following Lower second molar:
 - 1) Severity of crowding: Spaced (try to restore the tooth if possible). Mild-moderate crowding (extract the tooth). Moderate-severe crowding (wait until definitive planning in permanent dentition before extraction).
 - 2) Stage of development of molar.
Ideal timing is between crown complete to root formed, i.e. when the bifurcation of roots are forming.
 - 3) Status of the other first permanent molars:
Extract all, do not worry about balancing in the lower arch, do consider compensating because upper first molar will over erupt **(Alcock et al.2009)**.

1.4.4.2.2 Contraindication for extraction

- Late extraction of first molars results in rotation and mesial tipping of lower second molar tooth.
- Missing third molars **(Alcock et al.2009)**.

1.4.4.3 Upper first molar

1.4.4.3.1 Indication for extraction

- Hypoplastic or carious (Alcock et al.2009).

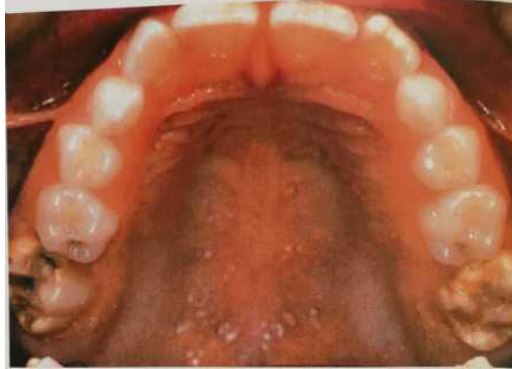

Figure 1.18. Hypomineralized permanent

- As a compensating extraction if lower first molar removed.
- Enforced due to caries then balancing and compensating extraction should be considered - but not essential (Alcock et al.2009).

1.4.5 Second permanent molars

1.4.5.1 Lower second molar

1.4.5.1.1 Indications for extraction.

- Relief of molar crowding.
 - i. Early permanent dentition with a well aligned (or minimally crowded) lower arch, third molar impaction likely.
 - ii. Extraction in early permanent dentition may prevent or at least limit late lower arch crowding.
- Relief of premolar crowding.
 - i. Vertically impacted premolar in the line of the arch.
 - ii. Early extraction indicated for spontaneous correction (Alcock et al.2009).

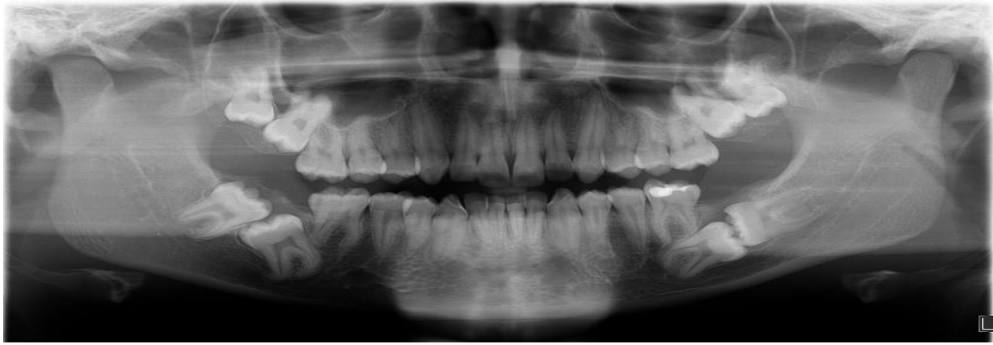

Figure 1.19. Impacted third and second molar

1.4.5.1.2 Contraindication of extraction.

- Developmental absence or diminutive third molar.
- Lower anterior crowding > 1-2 mm.

1.4.5.1.3 Advantages of second molar extraction.

- Obviate the need for surgical removal of third molar: financial and patient morbidity considerations.
- Shorter treatment = unsubstantiated.
- Facilitation of openbite reduction = unsubstantiated (**Alcock et al.2009**).

1.4.5.1.4 Disadvantages of second molar extraction

- Third molars may erupt into an unsatisfactory position, rarely with proper angulation and contact relationship.
- Wide discrepancy between studies on the number of unsatisfactory third molar eruptions: e.g. 25% Cryer, 20% Dacre, 4% Richardson.
- Difficult to predict which third molars will erupt unsatisfactorily.
- Second course of treatment to orthodontically upright the third molar may be required. (**Alcock et al.2009**).

1.4.5.2 Upper second molar.

1.4.5.2.1 Indications for extraction.

- To aid distal movement of the upper buccal segments with EOT - good cooperation with HG essential.
- Not indicated for relief of anterior crowding or overjet reduction.

- Generally accepted that third molars erupt into satisfactory contact with first molar.
- Accelerated eruption of third molar into acceptable position often occurs (**Alcock et al. 2009**).

1.4.5.2.2 Contra indications for extraction.

- Heavily restored first molar.
- Developmentally absent third molar.
- Prevalence of impaction may be increasing because fewer teeth extracted due to caries (**Alcock et al.2009**).

1.4.6 Third permanent molars

In the past. Early extraction of these teeth has been advocated to prevent lower labial segment crowding (**Millet et al.2005, Mitchell.2007**).

However, it is much more likely that late lower incisor crowding is caused by subtle growth and soft tissue changes that continue to occur throughout life It is now not acceptable to extract third molars purely on the grounds of preventing crowding of the lower labial segment (**Mitchell.2007**).

1.4.6.1 Indications for removal

- Third molars are the most common teeth to be impacted in oral cavity figure 1.19 (**Phulari.2011**).
- Impacted third molars, which are not likely to erupt into ideal position are frequently extracted (**Phulari.2011**).
- Pericoronitis development may also necessitate third molar extraction (**Phulari.2011**).
- Progressive crowding of lower anteriors is observed in adolescence and early adult life. This has often been blamed on the erupting lower third molar teeth although it is not proved. Some orthodontists advocate extraction of third molars to prevent such late crowding (**Phulari.2011**)
- Teeth that present with symptoms other than transiently associated with eruption.

- Teeth unlikely to contribute to occlusal function and whose position jeopardizes the continuing health of surrounding tissues:
 - i. Resorption of second molar.
 - ii. Follicular cyst.
 - iii. Bone loss due to chronic periodontitis.
 - iv. Concealed caries in distal surface of second molar (**Alcock et al.2009**).

1.5 Serial extraction

Serial extraction was first advocated in 1948 by Kjellgren, a Swedish orthodontist, as a solution to a shortage of orthodontists. Kjellgren hoped that his scheme would facilitate the treatment of patients with straight forward crowding by their own dentists, thus minimizing demands upon the orthodontic service (**Mitchell.2007**).

This treatment technique involves the sequential removal of deciduous teeth to facilitate the unimpeded eruption of the permanent teeth (**Graber et al.2017**).

Step 1: Extraction of deciduous canines

In this step, the deciduous canines are extracted at around 8-9 years to create space for the alignment of the incisors. The main objective of extracting primary canines is to establish the integrity of upper and lower incisors. This prevents the development of lingual crossbite of maxillary laterals and resultant mesial migration of maxillary canines.

Step 2: Extraction of deciduous first molars

In this step, deciduous first molars are extracted when first premolars reach half of the root length as evidenced by radiographs. This would be some 12 months after the extraction of deciduous canines at around 9-10 years of age. The objective of deciduous first molar extraction is to accelerate the eruption of first premolars. This ensures that the first premolars emerge into oral cavity, before the eruption of permanent canines.

Step 3: Extraction of first premolars

In this step, first premolars are extracted as they are emerging into oral cavity and when the permanent canines have developed beyond half of the root length. Extraction of first premolars facilitates proper eruption and alignment of permanent canines after serial extraction procedure, the teeth are fairly aligned. However, the establishment of proper intercuspation usually requires orthodontic mechanotherapy of minimal duration, although it may not be necessary in some cases **(Phulari. 2011)**.

For lower arch if the level of eruption of permanent canine is at a level higher than that of the first premolar, on radiographic evaluation, the enucleation of the developing first premolar crown at the time of extraction of deciduous first molar must do. Another modification advised in such clinical conditions is to extract the deciduous second molars instead of first premolar enucleation after placement of a lingual holding arch, so as to allow the first premolar to erupt distally. On eruption of permanent canines the first premolars are extracted **(Gurkeerat et al.2007)**.

1.5.1 *Advantages of Serial Extractions*

It brings about early self-induced alignment of the permanent teeth there is improved overall oral health.

1.5.2 *Disadvantages of Serial Extractions*

Not indicated for class II and class III malocclusions, if at all extraction is carried only in class II in upper arch It can have psychological impact on the child, if totally 12 teeth have to be extracted. Deepening of bite can occur Requires prolonged patient follow-up The procedure alone is not sufficient to bring impacted canine into proper position. Early extraction can lead to the loss of space and delayed the eruption of permanent teeth. **(Phulari.2011)**.

1.5.3 *Complications of Serial Extractions*

It can result in flat face with prominent chin. Patient may look aged.

It can result in lingual inclination of incisors.

1.5.4 Indications For serial Extractions

- Minimum 7.0 mm of crowding in the anterior areas per arch (**Jeryl et al.2015**).
- Severe arch length-tooth material discrepancy of 10 mm or more in the arch (**Phulari.2011**)
- Coincident upper and lower midlines (**Jeryl et al.2015**).
- Bilateral Class I molar relationship (**Jeryl et al.2015, Phulari.2011**).
- Balanced skeletal pattern in all three planes of space (**Jeryl et al.2015**).

1.5.5 Contra-indication for serial extractions

- Class III and Class II molar relationships (**Phulari.2011, Jeryl et al .2015**) .
- Unbalanced skeletal patterns of any kind (transverse, anteroposterior, or vertical) (**Jeryl et al.2015**).
- Unequal crowding in the maxillary and mandibular arches (**Jeryl et al.2015**).
- Unequal crowding bilaterally in either arch (**Jeryl et al.2015**).
- Midline discrepancies (more than 2 mm) (**Jeryl et al.2015, Phulari.2011**).
- Open bites or impinging deep bite (**Jeryl et al.2015, Phulari.2011**).
- Presence of midline diastema (**Phulari.2011**).

Chapter two

Material method

A Survey about extraction in orthodontics was conducted in Baghdad University, Collage of Dentistry, in which a eighteen orthodontists involved and were given a questioner form about how they make their decisions regarding extraction for therapeutic purposes in their clinical practice as in figure2.1.

Survey about extraction in orthodontic

How do you decide extraction in your clinic.

- a_ Depending on my experience.
- b_ Making space analysis on a study model.

.....
2. In class I molars and canines relationship, we have anterior crowding more than 6 mm in upper arch do you prefer?

a- Stripping and why ?

.....
b_ Extraction of first premolars and why ?

.....
3. In class I molars and canines relationship, we have anterior crowding more than 6 mm in lower arch do you prefer.

a_ Stripping and why ?

.....
b_ Extraction of first premolars and why ?

.....
4. Which approach do you follow in your clinic?

a_ Removal of impacted canine and reshaping of the first premolar and why?

.....
b_ Exposure of canine and orthodontic alignment and why ?

.....
c_ Removal of impacted canine then replacing with prosthesis?

.....
5. Do you set your anchorage posteriorly (TPA or TADs) and placing working stainless steel wires before doing extraction and why?

.....

..

Figure 2.1. Questionare form

Chapter three

Result

Questioners were introduced to our samples about (How do you decide extraction in your clinic?). Answers are 61.6% is depend on their experience and 38.8% is making space analysis on study model as the table 3.1 below.

Answers	Percentages
Depending on my experience	61.1%
Making space analysis on study model	38.8%

Table3.1.How do you decide extraction in your clinic

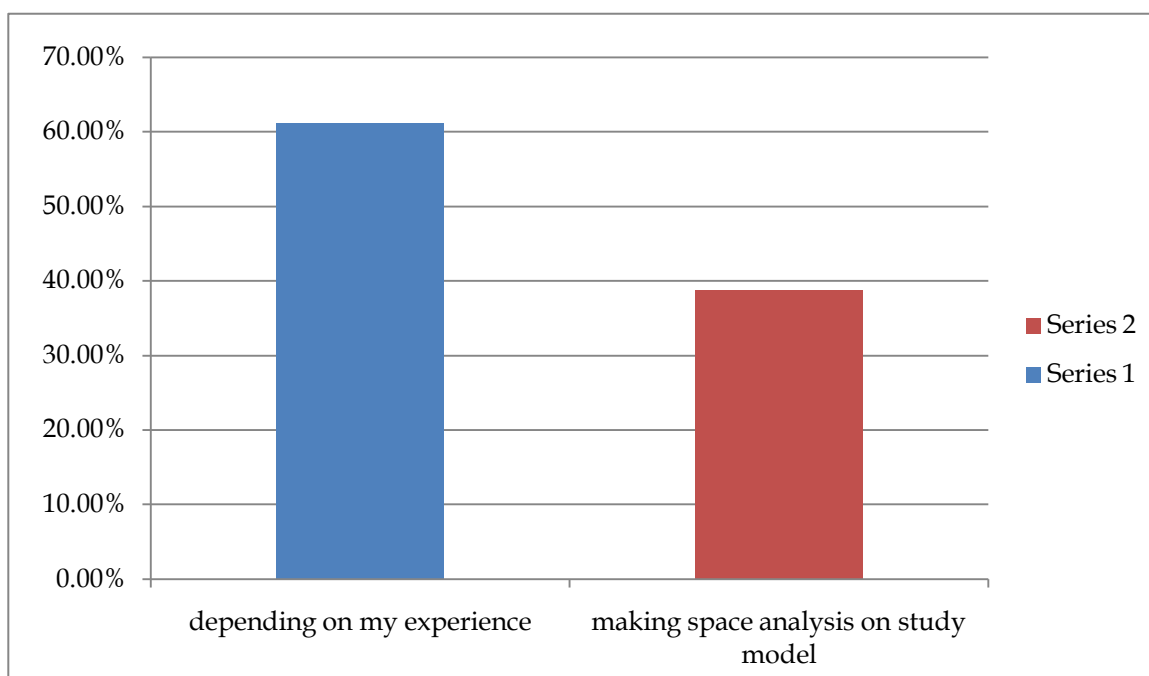


Chart 3.1.Percentage of answers of question one

Questioner was introduced to our samples about (In class I molars and canines relationship, we have anterior crowding more than 6 mm in upper arch do you prefer?).Answers are 33.3% is stripping and 66.6% is extraction of first premolars as the table 3.2 below.

Answers	Percentages
Stripping	33.3%
Extraction of first premolars	66.6%

Table 3.2.In cl I molars and canines relationship, we have anterior crowding more than 6 mm in upper arch do you prefer

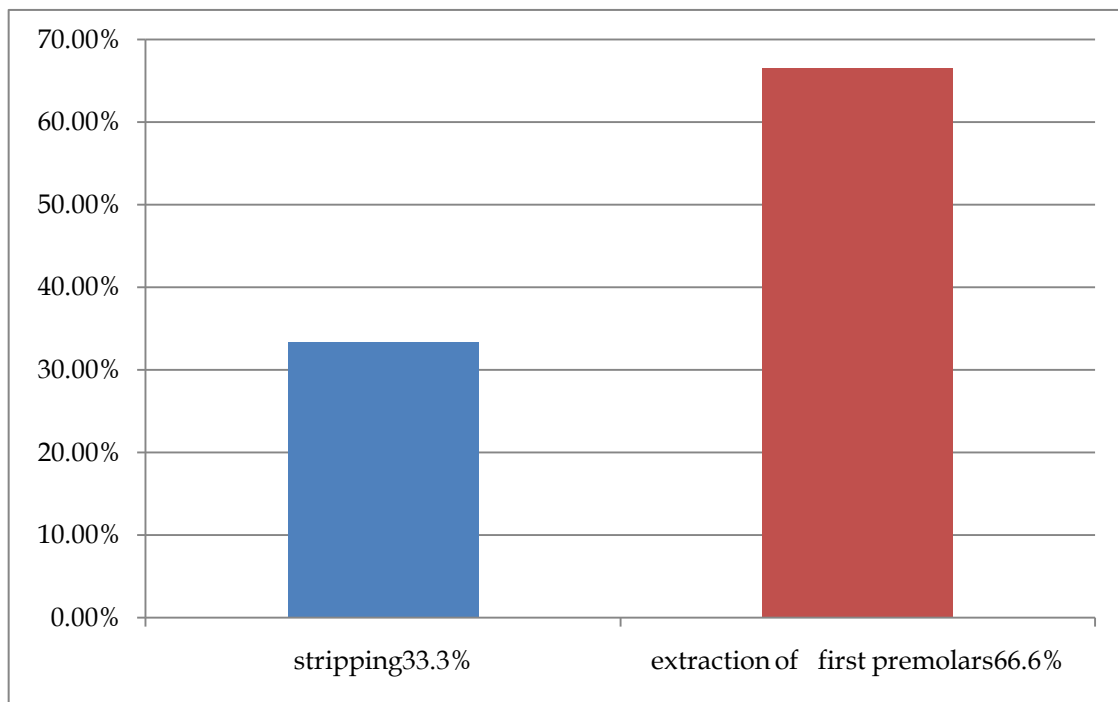


Chart 3.2.Percentage of answers of questions two

Questioner was introduced to our samples about (In class I molars and canines relationship, we have anterior crowding more than 6 mm in lower arch do you prefer ?

).Answers are 44.4% is stripping, 50% is extraction of first premolars 5.5% is no answer as the table 3.3 below.

Answers	Percentages
Stripping	44.4%
Extraction of first premolars	50%
No answer	5.5%

Table 3.3. In cl I molars and canines relationship , we have have anterior crowding more than 6 mm in lower arch do you prefer

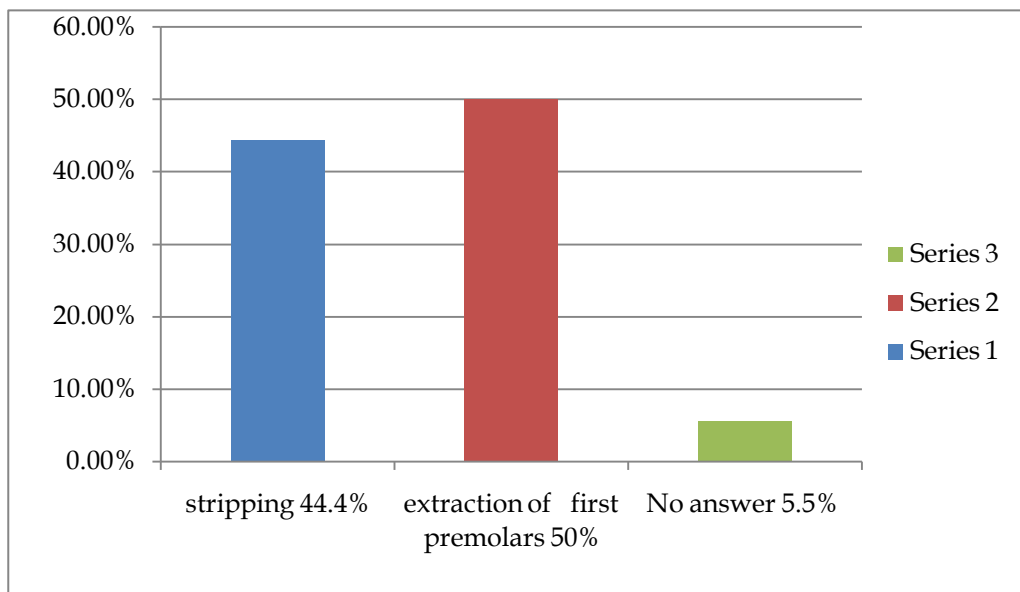


Chart 3.3. Percentage of answers of questions two

Questioner was introduced to our samples about (Which approach do you follow in your clinic?). Answers are 11.1% is removal of impacted canine and reshaping of the first premolar,66.6% is exposure of canine and orthodontic alignment Zero is

removal of impacted canine then replacing with prosthesis and 22.2% is Depend on case as the table 3.4 below.

Answers	Percentages
Removal of impacted canine and reshaping of the first premolar	11.1%
Exposure of canine and orthodontic alignment	66.6%
Removal of impacted canine then replacing with prosthesis	Zero
Depend on case	22.2%

Table 3.4. Which approach do you follow in your clinic

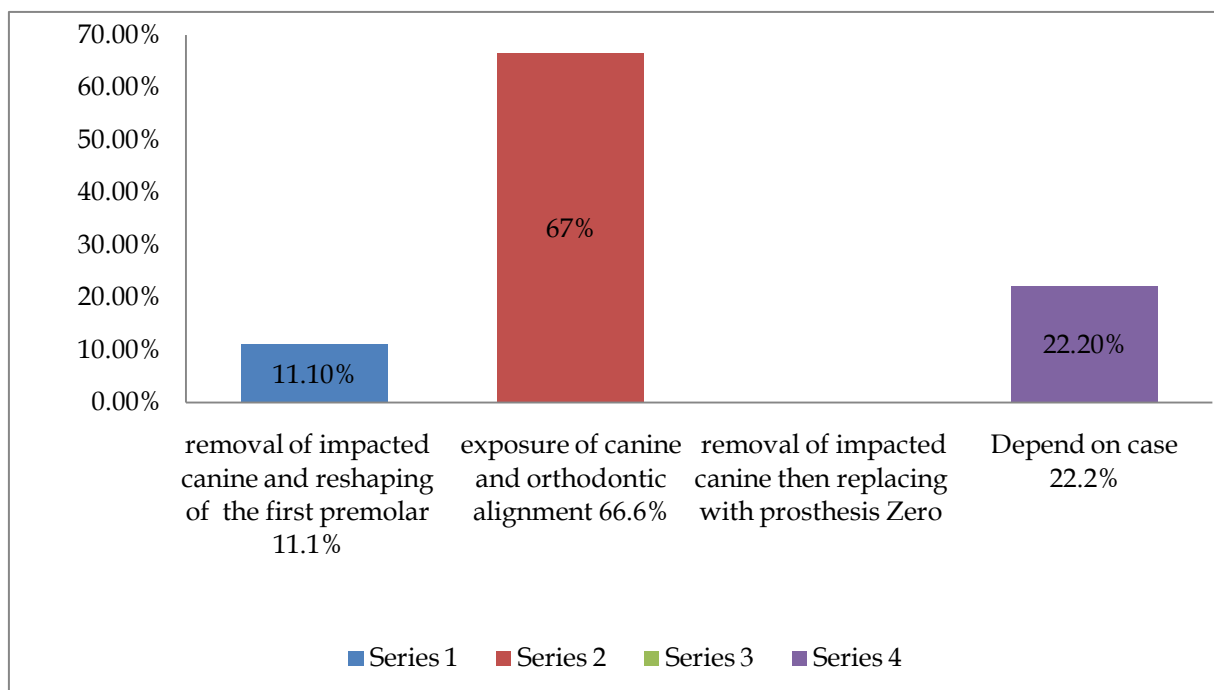
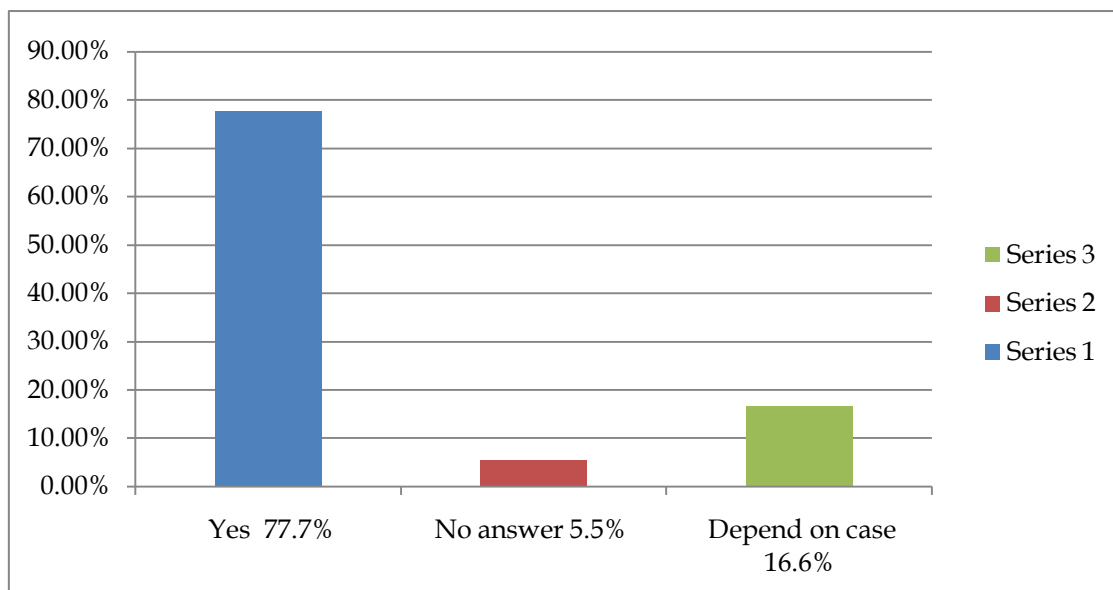


Chart 3.4. Percentage of answers of questions four

Questioner was introduced to our samples about (Do you set your anchorage posteriorly (TPA or TADs) and placing working stainless steel wires before doing extraction?).Answers are 77.7% is Yes, 16.6% is Depend on case and 5.5%is No answer as the table 3.5 below.

Answers	Percentages
Yes	77.7%
Depend on case	16.6%
No answer	5.5%

(Table 3.5 Do you set your anchorage posteriorly (TPA or TADs) and placing working stainless steel wires before doing extraction ?)



(Chart 3.5 percentage of answers of question five)

Chapter four

Discussion

In table 3.1 61.6% of orthodontists depend on their experience in deciding extraction properly because they treat so many cases and that qualify them to decide extraction without doing space analysis of the study models.

While 38.8% of orthodontists depend on space analysis of study model because they follow the scientific method in order to be in the safe side so that they will not end up with extra space and elongating treatment time.

In table 3.2 33.3% of orthodontist choose stripping as the stripping more conservative, more esthetic in some cases and to avoid extraction of first premolar, as it make canine relation CL II.

While 66.6% of orthodontists choice extraction of first premolars, because having moderate to severe crowding is one of indication of extract first premolar (**Michelle.2007**).also choosing stripping may cause flattening of contact area, tooth sensitivity (0.5 mm reduction of each tooth) and sometimes the patients refuse stripping.

In table 3.3 44.4% of orthodontists choice stripping as it More conservative, more esthetic in some cases and to avoid extraction of first premolar, as it make canine relation class II.

While 50% of orthodontist choice extraction of first premolars, because having moderate to severe crowding is one of indication of extract first premolar (**Michelle.2007**). Also they are not choose as stripping may cause flattening of contact area, tooth sensitivity (0.5 mm reduction of each tooth) and sometimes the patients refuse stripping.

5.5% of orthodontists refuse answer to this question.

In table 3.4 0% prefers extraction of impacted canine and replace with prosthesis.

11.1% of orthodontists choice removal of impacted canine and reshaping of the first premolar as this decrease treatment time, good contact between lateral incisor and first premolar if the contact is poor we will not have good occlusion less time consuming and the patient prefer it sometime.

On the other hand 66.6% of orthodontists choose exposure of canine and orthodontic alignment as the canine form the cornerstone of the arch and are important both aesthetically (for lip support) and functionally (providing canine guidance in lateral movements).Their extraction causes flattening of the face, altered facial balance and change in facial expression. While 22.2% depend on the case.

In table 3.5 77.7% the answer was yes in order to avoid loss of space that might happen if the patient fail to attend his appointments.

16.6% depend on case.

5.5% no answer.

Chapter five

Suggestion

- Run the same survey on larger sample.
- Run the same survey in an advanced questioner.

Reference

1. Choo yew on . Ling chern chern. (2011). Orthodontic lecture manual (second edition).
2. Declan millet and richard welbury. (2005). Clinical problem solving in orthodontic and paediatric dentistry (1st edition). St louis, sydney ,london,toronto,philadelphia.oxford, new york: elsevier.
3. Foster, t. D. (1990). A textbook of orthodontics (third edition). Oxford londonand edinburgh boston melbourne: blackwell scientific publications.
4. Gurkeerat singh,navjot singh,ankur kaul et el. (2007). Textbook of orthodontics (second edition). New delhi: jaypee brothers medical publishers.
5. H travess, d roberts-harry and j sandy. (2004, february 28). Extractions in orthodontics. Pp. 196:195 - 203.
6. Jeryl d. Sercan akyalcin. Timo peltomäki. Kate litschel. (2015). Mosby's orthodontic review (second edition). St. Louis, missouri: elsevier.
7. Joe alcock ,saud ai-anezi,nikki atack,sinaed barlow,matt clover,scott deacon,tony ireland,nicky et el. (2009). Postgraduate notes in orthodontics (fifth edition). The division of child dental health, bristol dental school, university of bristol.
8. Laura mitchell. (2007). An introduction to orthodontic (third edition). United states: oxford university press.
9. Lee w. Graber,robert l. Vanarsdall jr.,katherine w.l. Vig,greg j. Huang,. (2017). Orthodontics current principles and techniques (6th edition). St. Louis, missouri: elsevier.

- 10. Phulari, b. S. (2011). Orthodontics principles and practice (1st edition ed.). New delhi: jaypee brothers medical publishers.**
- 11. William r. Proffit, dds, phd, henry w. Fields, dds, ms, msd, and david m. Sarver, dmd, ms. (2013). Contemporary orthodontics, (5th edition ed.). St. Louis, missouri: elsevier.**