

## ANATOMICAL LANDMARKS

A good knowledge about the intra-oral landmarks for the maxillary and mandibular arch will help the clinician to carefully manage a patient and it will act as positive guides to the limit of the impression and denture extensions.

The intra-oral anatomical landmarks divided into:

### 1. Maxillary arch anatomical landmarks: which is divided into:

- a. Supporting structures
- b. Limiting structures
- c. Relief areas

#### a. Supporting structures:

1. Residual alveolar ridge
2. Maxillary tuberosity
3. Incisive papilla
4. Rugae area
5. Median palatal rhae
6. Canine eminence
7. Zygomatic process
8. Hamular notch
9. Torus palatinus

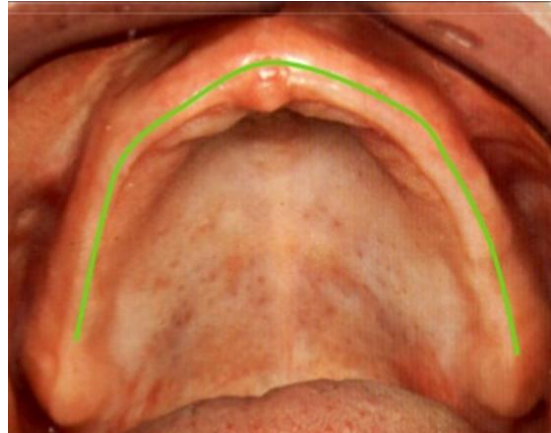
Support is the resistance to the displacement towards the basal tissue or underlying structures and it can be Primary stress bearing areas or supporting area represented by the horizontal portion of the hard palate lateral to the midline and Slopes of residual alveolar ridge and a Secondary stress bearing area or supporting areas represented by Rugae area and Maxillary Tuberosity.

### 1. Residual alveolar ridge:

The bony process that remain after teeth have been lost is known as **Residual alveolar ridge** which is covered by mucous membrane.

The Residual alveolar ridge considered to be as a primary stress bearing area.

And it will produce the ridge fossa or groove in the impression or denture.



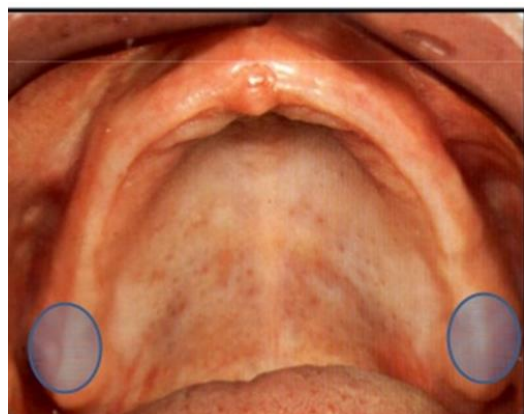
#### Types of Residual alveolar ridge:

- a. Flat
- b. Rounded
- c. V Shape
- d. U Shape



### 2. Maxillary tuberosity

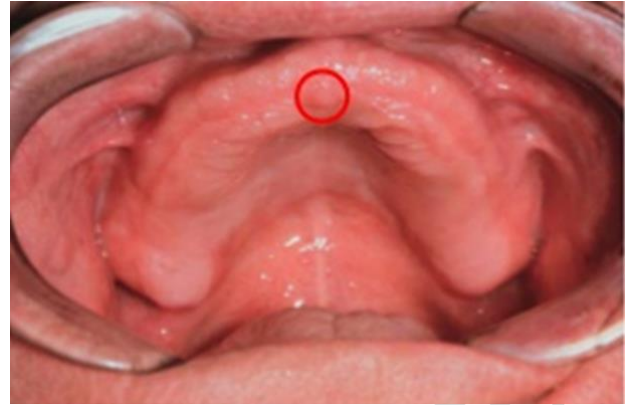It is the area of the alveolar ridge that extends distally from the second molar to the hamular notch in some cases it may be very large in size and not allow for proper placement of the denture so may need surgical interferences.



Maxillary tuberosity may be oversized, resorbed or undercut areas; in case of oversized and undercut type surgical corrections may be needed.

### 3. Incisive papilla

It is a pad of connective tissues lies between the two central incisors on the palatal side overlying the incisive foramen of the nasopalatine duct where the nasopalatine nerves and vessels arise. In an edentulous mouth



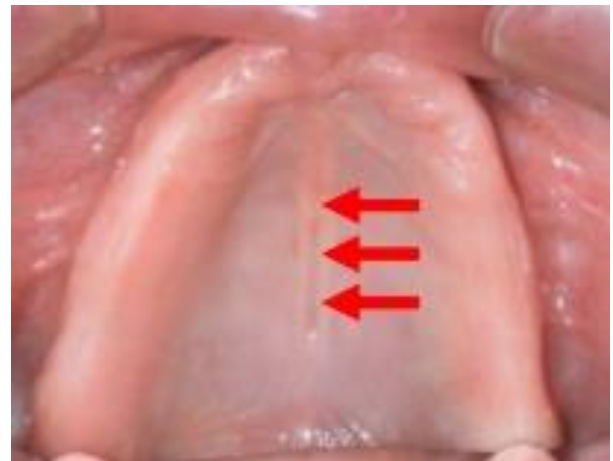it may lie close to the crest of the residual ridge. Relief over the Incisive papilla should be provided in the Denture to avoid pressure on the nerve and blood supply.

### 4. Rugae area

These are raised areas of dense connective tissue in the anterior One-third of the palate. It aid in the formation of vocal sound also regarded as a secondary stress bearing area.

### 5. Median palatal raghae

It overlies the medial palatal suture; extend from the incisive papilla to the distal end of the hard palate. The mucosa over this areas is usually tightly attached and thin, the underlying bonny union being very dense and often raised, the palatal tori are located here if present.

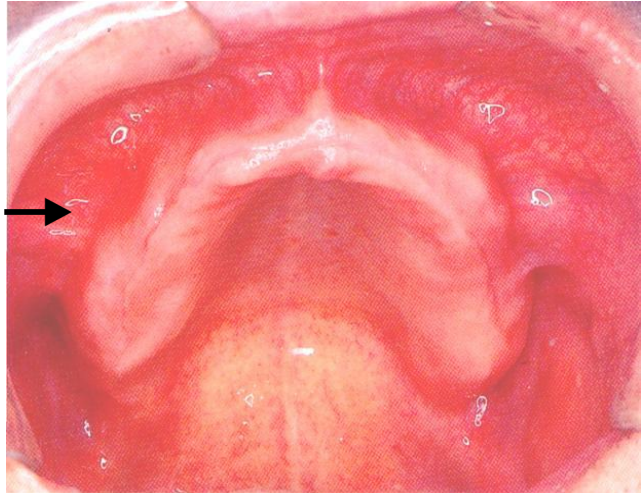


### 6. Canine eminence

It is a round elevation in the corner of the mouth, it represent the location of the root of the canine which is helpful to be use as a guide for the arrangement of maxillary anterior teeth.

### 7. Zygomatic process

It is located opposite to the 1st molar region, hard area found in the mouth that has been edentulous for long time. Relief over this area may be required to prevent soreness of the underlying tissues.



### 8. Hamular notch

It is a narrow cleft of loose connective tissue situated between the maxillary tuberosity and the pterygoid hamulus (approximately 2mm antero-posteriorly). It is used as boundary of the posterior border of maxillary denture.

### 9. Torus palatinus

It is a hard bony enlargement occurs in the midline of the roof of the mouth (hard palate). It is found in 20% of some patient, surgical correction may be needed if the tori very large.

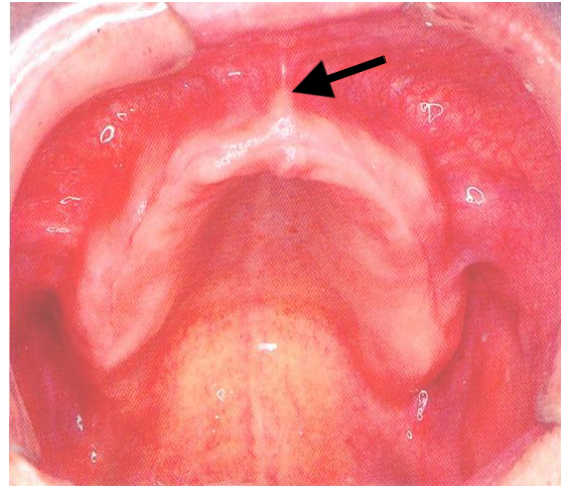
#### b. Limiting structures:

1. Labial frenum
2. Buccal frenum
3. Labial vestibule
4. Buccal vestibule

5. Foveae palatinae
6. Vibrating line

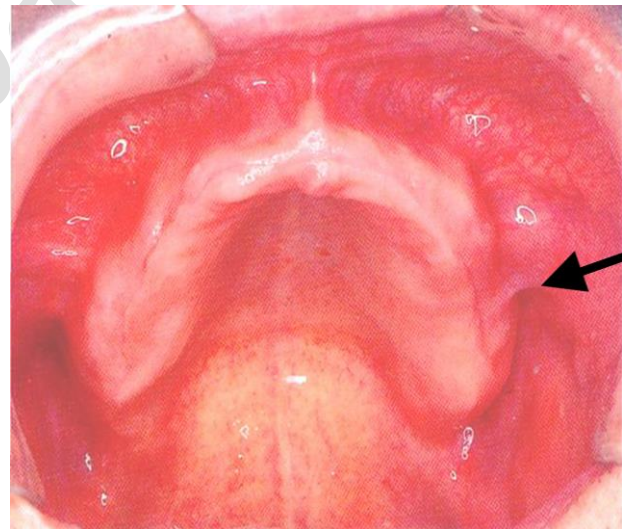
### 1. Labial Frenum

It is a fold of mucous membrane extends from the mucosal lining of upper lip to the labial surface of the residual ridge. The Frenum may be single or multiple, narrow or broad. It contains no muscle fibers and insert in a vertical direction which creates a maxillary labial notch in the maxillary impression or denture.



### 2. Buccal Frenum

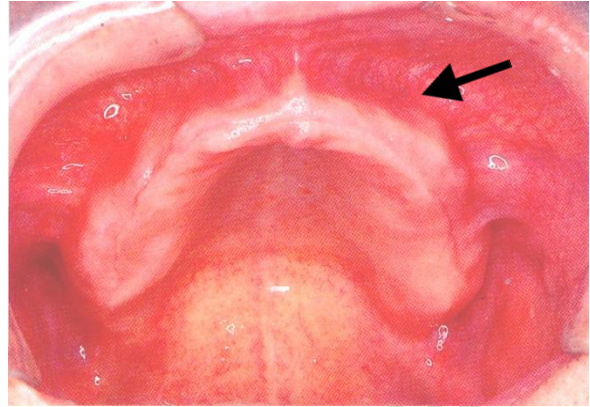
A fold or folds of mucous membrane varies in size and shapes. It extends from the buccal mucous membrane reflection area toward the slope or crest of the residual alveolar ridge. It contains no muscle fibers and its direction antero-posteriorly. It produce the maxillary buccal notch in the maxillary impression or denture which



must be broad enough because of the movement of the Frenum which is affected by some of the facial muscles as the orbicularis muscle pull it forward while buccinator muscle pull it backward.

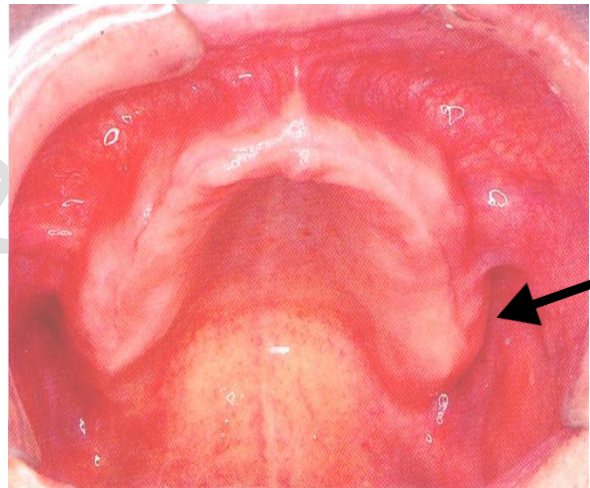
### 3. Labial vestibule

It extends on both sides of the labial frenum to the buccal frenum, bounded by the upper lip and residual alveolar ridge. The reflection of the mucous membrane superiorly determines the height of the vestibule. It contains no muscle fibers. In the denture the area that fills this space is known as labial flange.



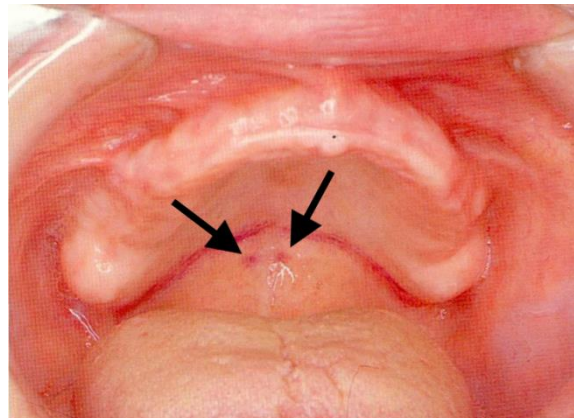
### 4. Buccal vestibule

Is the space distal to the buccal frenum. It is bounded laterally by the cheek and medially by the residual alveolar ridge. The area of the denture which will fill this space is known as buccal flange. The stability and retention of a denture are greater enhanced if the vestibule space properly filled with the flange distally.



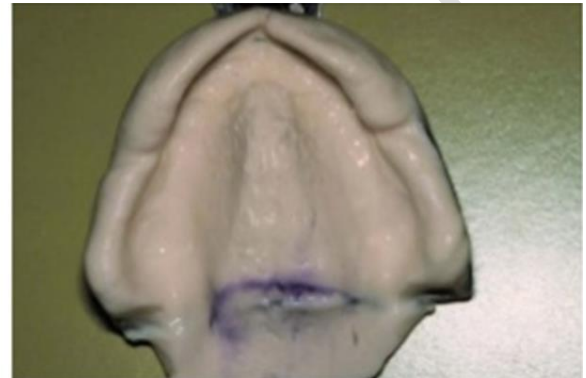
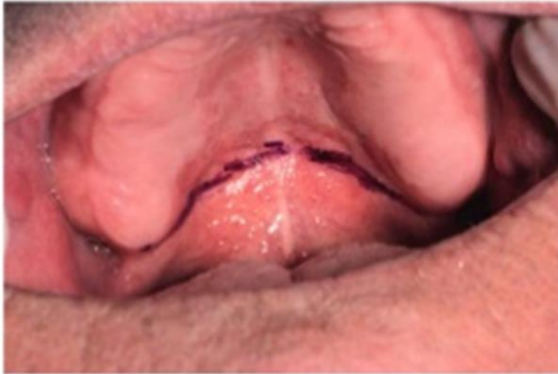### 5. Fovea palatinae

These are two indentations on each side of the midline formed by a coalescence of several mucous gland ducts. They act as a guide in the location of the vibrating line of the posterior border of the denture.

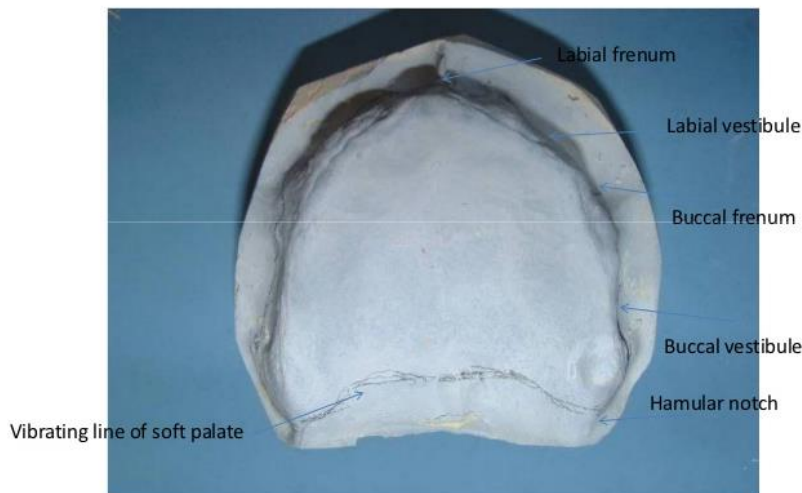


## 6. Vibrating line

An Imaginary line drawn across the palate extended from one hamular notch to the other. It is not well defined as a line; therefore it is better to describe it as an area rather than a line. The direction of the line varies according to the shape of the palate in the denture. The posterior border of the denture known as posterior palatal seal area.

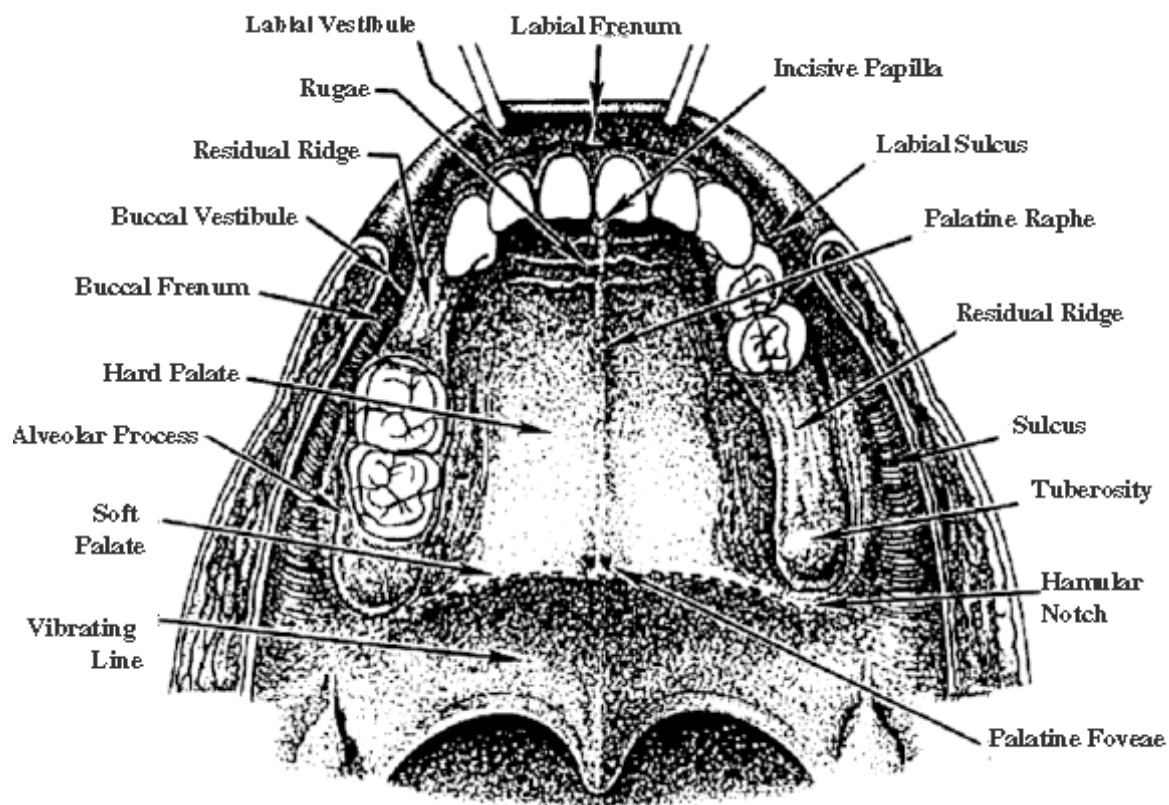


### Limiting structures of maxillary denture



### C. Relief Areas:

1. Incisive papilla
2. Mid-palatine raphe
3. Crest of the residual alveolar ridge
4. Cuspid eminence
5. Zygomatic Process



**Anatomical Landmarks of the maxillary arch**