

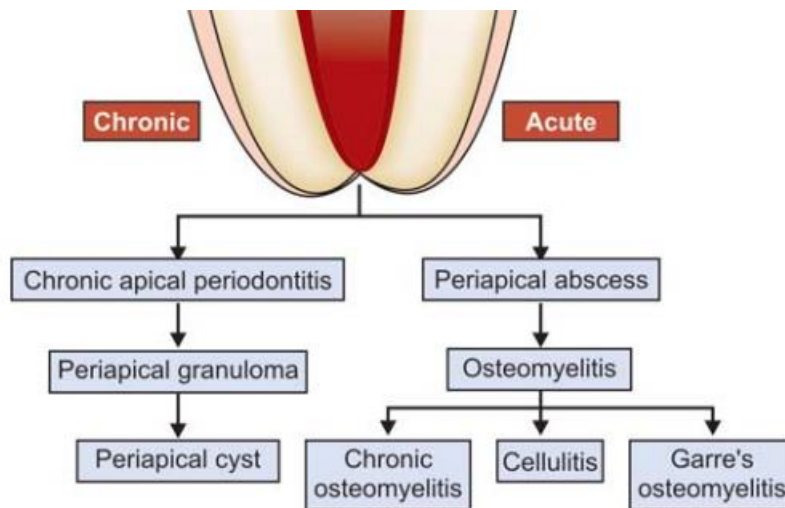
ENDODONTICS

Lecture 2

Asst. Prof. Raghad Al-Hashimi

Classification of periapical disease

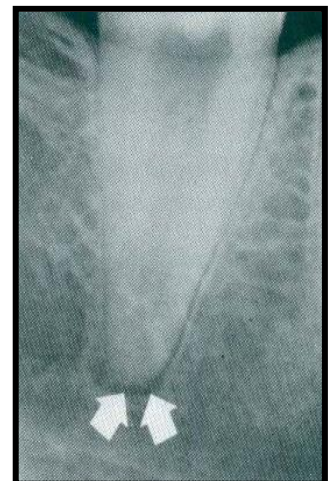
Untreated pulpal infection leads to total pulp necrosis. If left untreated, irritants leak into periapical region forming periapex pathologies. Severity of periapical inflammation is related to microorganisms in root canals and the length of exposure to infecting microorganisms.



Sequelae of pulpal inflammation

Acute apical periodontitis (AAP)

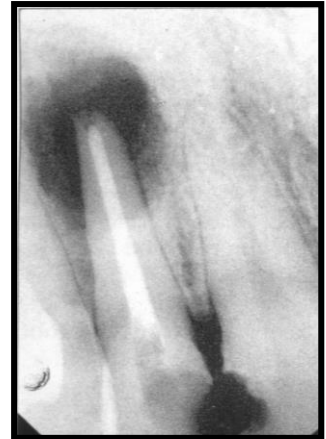Acute apical periodontitis is defined as painful inflammation of the periodontium as a result of occlusal trauma, egress of bacteria from infected pulps, toxins from necrotic pulps, chemicals, irrigants or over instrumentation in root canal therapy. Clinically, the tooth is tender to biting. The distinctive features of AAP are dull throbbing constant pain, it occurs over a short period of time. Cold stuff may relieve pain, whereas heat may exacerbate pain. Widening of the periodontal ligament space may be seen on a radiograph.



Treatment depends on pulpal diagnosis; it may range from occlusal adjustment to root canal therapy or extraction.

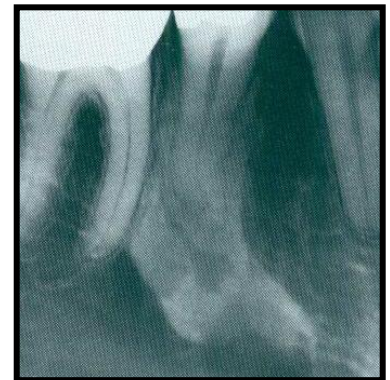Chronic apical periodontitis

Chronic apical periodontitis occurs as a result of pulp necrosis. Affected teeth do not respond to pulp sensitivity tests. Tenderness to biting is usually mild; however some tenderness may be noted to palpation over the root apex. Radiographic appearance is varied, ranging from minimal widening of the periodontal ligament space to a large area of destruction of periapical tissues. Treatment involves root canal therapy or extraction.



Condensing osteitis

Condensing osteitis is a variant of chronic apical periodontitis and represents a diffuse increase in trabecular bone in response to irritation. Radiographically, a concentric radiopaque area is seen around the offending root. Treatment is only required if symptoms/pulpal diagnosis indicate a need.

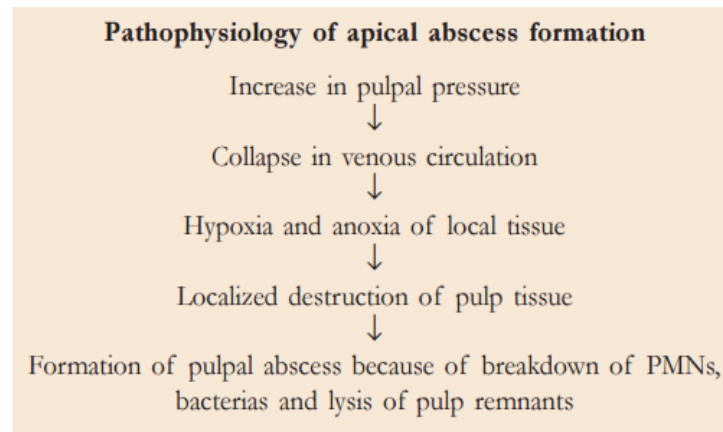


Acute apical abscess

It is a localized collection of pus in the alveolar bone at the root apex of the tooth, following the death of pulp with extension of the infection through the apical foramen into periradicular tissue. The most common cause of Acute Apical Abscess is invasion of bacteria from necrotic pulp tissue. Symptoms vary from moderate discomfort or swelling to systemic involvement, such as raised temperature and malaise. Teeth involved are usually tender to both palpation and percussion. The tooth is non vital and the pain is being of rapid onset with Readily localized as tooth becomes increasingly tender to percussion.

Radiographic changes are variable depending on the amount of periradicular destruction already present; however, usually there is a well-defined radiolucent area, as in many situations an acute apical abscess is an acute exacerbation of a chronic situation. Initial treatment of an acute apical abscess involves removal of the cause as soon as possible. Drainage should be established either by opening the tooth or

incision into a related swelling. An antibiotic may need to be prescribed, depending on the patient's condition. Once the acute symptoms have subsided, then root canal therapy or extraction may be performed. If the apical abscess is not treated, it will spread to surrounding tissues.



Chronic apical abscess

Chronic periapical abscess is also known as suppurative apical periodontitis which is associated with gradual egress of irritants from root canal system into periradicular area leading to formation of an exudate. In a chronic apical abscess, the abscess has formed a communication through which it discharges. Such communications may be through an intraoral sinus or, less commonly, extraorally. Alternatively the discharge may be along the periodontal ligament; such cases resemble a periodontal pocket. Usually these communications or tracts heal spontaneously following root canal therapy or extraction.

Access Opening

Access opening is the cavity that is prepared in the crown of a tooth to obtain adequate and direct access (straight line access) to the apical foramen to ensure free movement of the instruments during pulp extirpation, preparation and obturation of the root canal. Preparing the endodontic access cavity is a critical step in a series of procedures that potentially leads to the three-dimensional obturation of the root canal system. Access cavities should be cut so the pulpal roof, including all overlying dentin, is removed.

Objectives of Access Opening:

- 1) To facilitate visualization of all the root canal orifices by removing the pulp chamber and exposure of pulp horns.
- 2) To provide direct access (straight-line access) to the apical portion of the canal.
- 3) Conserve sound tooth structure as much as possible so as to avoid weakening of remaining tooth structure.

The outline form of the access cavity must be correctly shaped and positioned according to:

- I. **The size of the pulp chamber.**
- II. **The shape of the pulp chamber.**
- III. **The number of individual root canals and their direction of curvature.**

The outline form is affected by the size of the pulp chamber, so access opening for young patients is larger, because the pulp chamber is larger, while in old patients the pulp chamber is smaller.

The finished outline should reflect accurately the shape of the pulp chamber, e.g. in premolars the pulp chamber is oval in cross section so the access opening is oval, elongated buccolingually than mesiodistally (following the pulp chamber shape). Sometimes a modification is needed to get the objective of access opening.

Access objectives are confirmed when all the orifices can be visualized without moving the mouth mirror. Ideally, endodontic access cavities should parallel the principle of restorative dentistry where the axial walls of a “finished” preparation taper and provide draw for a wax pattern.

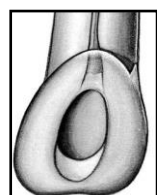
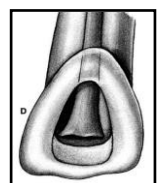
The number of individual root canals and their curvature modifies the outline of the access opening. Sometimes we have to remove part of a cusp of a molar or incisal ridge in order to facilitate better visualization to the root canals.

The dentist must be able to see, locate and reach by the instruments each root canal.

Shape of access opening for each anterior tooth

1- Maxillary Central Incisor: The access opening is triangular in shape.

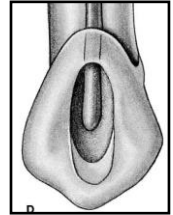
The root is straight, single, large, oval at the beginning, then tapered till it becomes rounded apically. **Average tooth length=22.5mm**



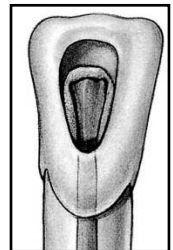
2- Maxillary Lateral Incisor: Similar in shape to the max. central incisor, but smaller in size with: disto-palatal curvature at the apex of the root.

Average tooth length= 21mm

3- Maxillary Canine: The canal is big and it is wider bucco-lingually than mesiodistally. At the cervical third the orifice is oval, at the middle third: it is oval., and in the apical third it is rounded. **Average length=26.5mm**

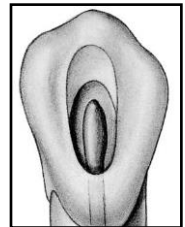


4- Mandibular Incisors: If we take an x-ray from buccal direction we will find small, tiny root canal, but if we take an x-ray film from mesial or distal direction, we will find large, wide pulp “labio-lingually” with a possibility of two canals one labially and the second one is located lingually, so we have to widen the root canal orifice “Labiolingually”. **Average length=21mm**



Also, in the lower incisor, some times we have slight curvature in the root apex “to the lingual side” so, there is a possibility of perforation during instrumentation.

5- Mandibular Canine: There is one canal which is big and oval in shape. Another root canal may be present lingually to the major root canal but this rarely happens. **Average length=22.5mm**

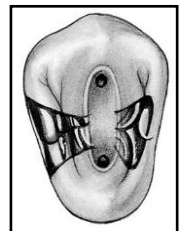


Access openings of each posterior tooth

1- Maxillary first premolar-

- Access opening: ovoid and elongated buccopalatally. **Average length=21mm**

- The canal shape is wide in buccopalatal direction at cervical portion, slight ovoid at mid-root and rounded at apical third.



- Canal Orifices: below and slightly central to cusps tips. - Multiple canal possibilities:

(i) 20% single canal in single root, elliptical or figure (8) in shape, wider buccopalatally than mesiodistally. It may be mistaken as two canals.

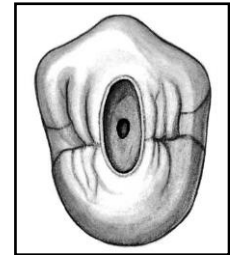
(ii) 80%: two canals, either single root with either one or two apical foraminae, or two canals with two separated roots “and the palatal one is longer”.

(iii) Rarely there are (3) roots with (3) root canals.

Type (ii) or (iii), usually have two roots.

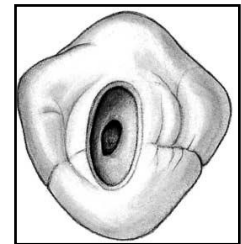
2- Maxillary Second Premolar

- Mostly it has a single root and the canal shape is ovoid and very wide in buccopalatal direction, ovoid in the mid root, and rounded in the apical area. **Average length=21.5mm**
- Canal orifice is centrally located and often appears as a slot than as a single ovoid opening.
- Multiple canals possibilities: 40% → 2 canals, 60% → one canal.



3- Mandible First Premolar:

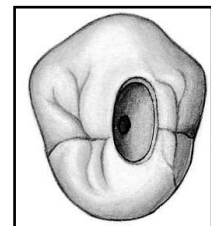
Mandibular first premolar has well developed buccal cusp and a small lingual cusp, the root is more rounded than mandibular second premolar and shorter. The pulp chamber is ovoid and buccal pulp horn higher. **Average length=21.5mm**



- Canal shape: At cervical level is wide in buccolingual dimension. At the mid-root area it is ovoid and at the apical third it is rounded.
 - Canal configuration possibilities: Type I = 73.5%, Type II = 6.5%, Type III = 19.5%
- We may also see Type IV.
- Access opening: ovoid and made slightly buccally to the central groove and the final preparation should have a slightly lingual inclination.

4- Mandibular second Premolar:

It has a well developed buccal cusp and much less formed lingual cusp. There is a one root canal, and the pulp chamber is gradually merging with root canal. **Average length=22.5mm**

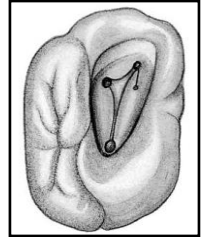


- Canal orifice:
 - a- At cervical → wide in buccolingual dimension.
 - b- Mid-root level → elongated ovoid.

c- Apical third level → generally round.

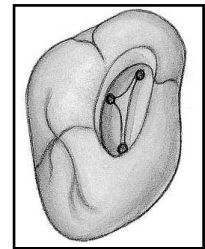
5- Maxillary 1st Molar

- There are three roots, with three root canals mesiobuccal, distobuccal, and palatal canal which is the biggest one. **Average length=21mm**
- The access opening is in the mesial part of the tooth and we may leave the oblique ridge as it is if it is caries free.
- The final preparation of the access opening is triangular in shape and there are three canals:
 - a- Mesiobuccal canal: It is a tiny canal, difficult to find. It is possible to find another mesiobuccal canal (70%) lingual to the main one.
 - b- Distobuccal canal: It is toward the distopalatal side.
 - c- The palatal canal: It is in between.



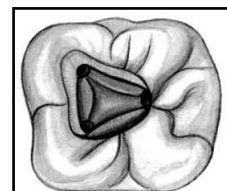
6- Maxillary 2nd Molar

- Similar to max. 1st molar but the distobuccal canal is located in between the mesiobuccal canal and palatal canal and slightly distally. **Average length=20mm**
- Variations: We may have 2 canals: one buccally and one palatally instead of 3 canal, in this case the two canals are large in size and opposite to each other.



7- Mandibular 1st Molar

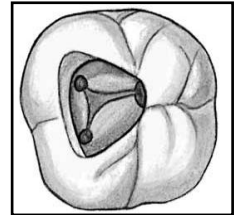
- There are 3 canals, 2 mesial “mesiobuccal and mesiolingual” and one located distally. **Average length=21mm**
- We start preparation in mesial part of the tooth and access opening is triangular-rectangular in shape.
- There is a possibility of 2 canals located distally (33%) “and they may end with separate orifices or joined orifice so if the distal canal is tiny and more toward the buccal side then the possibility of 2 canals is high but if it is in the center



buccolingually then the possibility of one canal is high.

8- Mandibular 2nd Molar

- The access opening resembles that of the mand. 1st molar with 3 root canals, 2 mesially and 1 distally. **Average length=20mm**
- There is a possibility of 2 canals: mesial canal and distal canal with each canal opposite to other.



NOTE:

Currently, new concepts in endodontic access opening have been developed namely **Ninja access opening** in order to preserve the amount of tooth structure during root canal treatment procedure. Ninja access opening is one of the important steps towards improving the quality of root canal treatment as well as achieving “a minimally invasive endodontic” concept.

Minimally invasive endodontics: is paramount, even for preparing endodontic access cavity, as removing as little tooth structure as possible allowing us to maintain as much tooth strength as possible. Thus, improving fracture resistance of endodontically treated teeth.