

**Anatomy of the TMJ and Mandibular Movement**

**Temporomandibular joint (TMJ):** Is the articulation of the condyloid process of the mandible and the interarticular disk with the mandibular (glenoid fossa) of the temporal bone. The TMJ consist of the following parts:

1. The mandibular or glenoid fossa.
2. The condyle or head of the mandible.
3. The articular disc or "Meniscus" which is found between the condyle and the glenoid fossa. It divides the synovial joint or TMJ into upper (superior) and lower (inferior) compartments.
4. Synovial cavity.

**How does the TMJ move during function:-**

Replacement dentures must work in harmony with the patients TMJ which consist of the condyles which articulate with the temporal bones and are located in the elliptical concave depressions called the glenoid fossae in which they travel forward, from side to side, and in some instances slightly backward. Between the dome- shaped concavities in the temporal bones and the condyles are interposed the interarticular fibrocartilages, the meniscus, which are attached at their margins to the articular capsules. The meniscus divided the joint into upper and lower compartments. Normally the movements in the upper compartment is chiefly gliding anteroposterior motion in which the condyles and the cartilage move as a unite, the movement in the lower compartment is hinge like. Therefore condylar path are the controlling factor in the mandibular movements. These movements are results of action of muscles of mastication, suprahyoid, and infrahyoid muscles.

**Temporomandibular joint**

**The ligaments** that effect the movement of the mandible consist of:

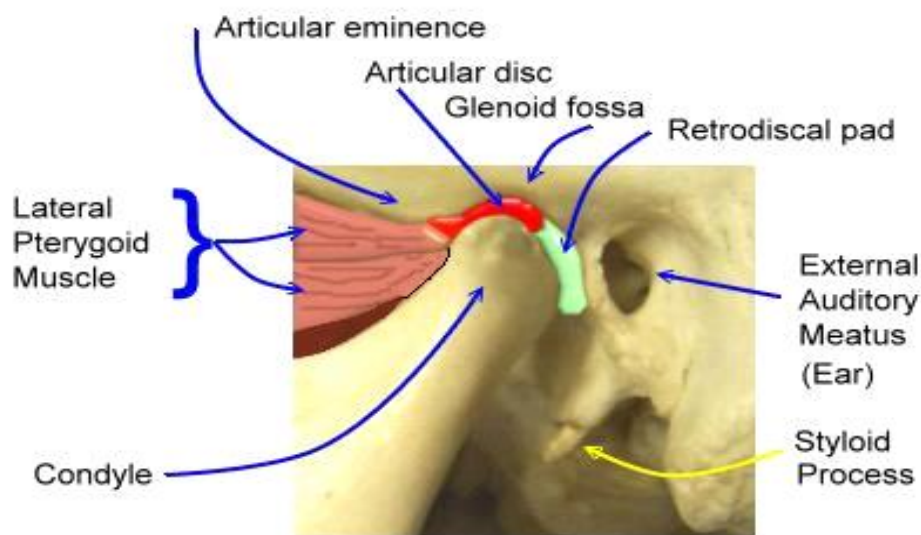
1. Tempromandibular and capsular ligaments.
2. Sphenomandibular ligament.
3. Stylomandibular ligament.

The mandibular bone has specific relationships to the bones of the cranium. The mandible is connected to the cranium at the two temporomandibular joint by the temporomandibular and capsular

ligaments. The sphenomandibular and Stylomandibular ligaments also connect the bones in such a way as to limit some motions of the mandible.

**The muscles** that control the movement of the mandible may be considered in 3 groups:

1. Closing muscles.
2. Gliding muscles.
3. Opening muscle.



### **The closing muscles include**

- The masseter muscle ( muscle of mastication)
- The temporal muscle =
- The medial pterygoid muscle.

The direction of their fibers is essentially vertical, their origin is superior to their insertion on the mandible.

### **The gliding muscles include:**

Medial pterygoid muscles (muscle of mastication). The actions of these muscles are to pull the mandible forward if they both contract simultaneously, or to pull the mandible laterally if they contract individually.

### ***The opening muscles:***

- Suprahyoid muscles their origin below the mandible
- Infrahyoid muscles action-downward and backward

The teeth could not occlude or disocclude without the action of four (paired) muscles of mastication that make it all possible.

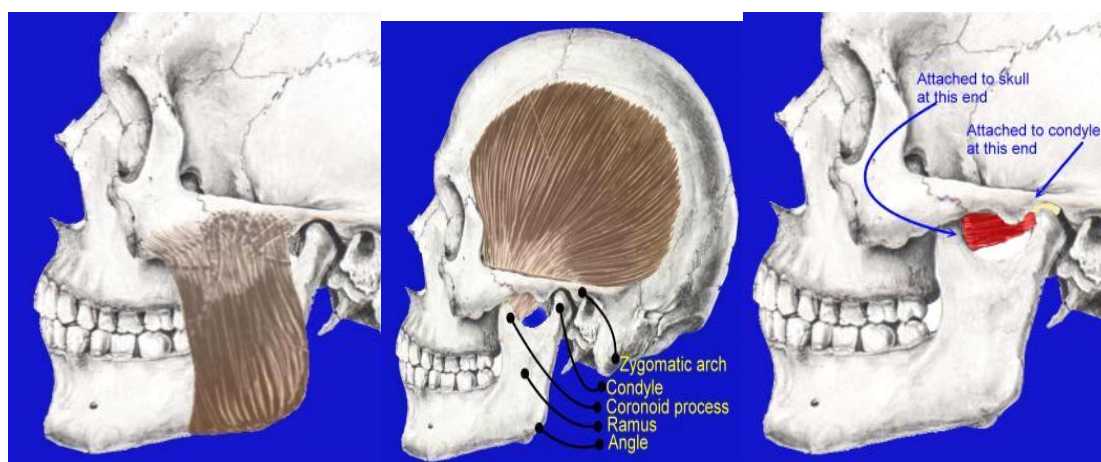
The masseter, temporalis & medial pterygoid muscles supply the power for pulling the mandible against the maxillae (elevating & closing mandible).

\*The lateral pterygoid muscles connect the mandible to the lateral pterygoid plate in such a way as to act as the steering mechanism for the mandible & act to protrude the jaw or to move it laterally.

\* While the muscles that depress the mandible (open) consist of three groups, suprahyoid muscle and platysma, infrahyoid muscles, and lateral pterygoid muscles.

Good prosthodontic treatment bears a direct relation to the structures of the temporomandibular articulation, since occlusion is one of the most important parts of treatment of the patients with complete dentures. The temporomandibular joints affect the dentures and likewise the dentures affect health and function of the joints.

### **The muscles of mastication**

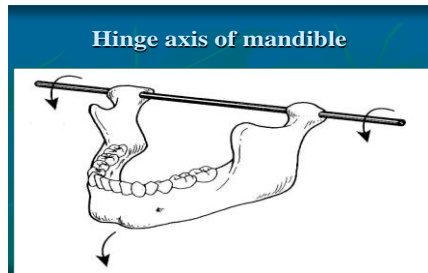


**Masseter and the Temporalis muscle, lateral pterygoid, Medial Pterygoid muscles**

**Mandibular axis:** There are three axes around which the mandibular movements takes place in horizontal, sagittal and frontal planes. These axes include the followings:

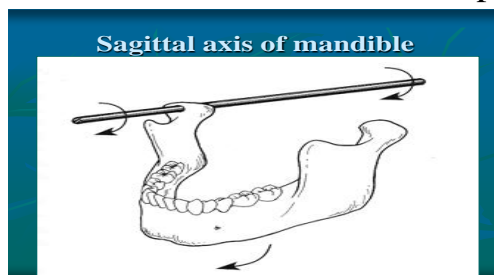
**1. Hinge axis:** or transverse horizontal axis:

An imaginary line around which the mandible may rotate within the sagittal plane. (During the opening and closing movement).



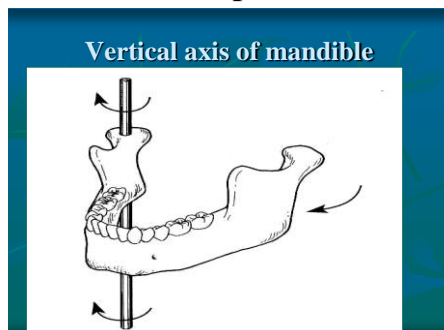
**2. Sagittal axis of the mandible :**

An imaginary anteroposterior line around which the mandible may rotate when view in the frontal plane.



**3. Vertical axis of the mandible:**

An imaginary line around which the mandible may rotate through the horizontal plane.



## **Mandibular Movements:**

Movement of the condyle occur along the posterior slop of the articular eminence and extend as far forward as its crest. In some instances, movements may involve part of the anterior slope.

\*Mandibular movements are related to three planes of the skull--- the horizontal, frontal, and sagittal. The mandible rotates in each of the three planes of space. The point of intersection of the three axes is called the center of rotation.

Mandibular movements may be *divided* into two types either *basic* or *functional* movement.

**1. Basic movements:** This movements occurs at the level of TMJ it may be divided into two types:

### **a- Rotational movement:**

The rotational movement occurs between the condyle and the inferior surface of the articular disk, i.e. in the lower compartment of the TMJ. Centric relation which is called uppermost, rearmost, midmost or most posterior position is purely rotary movement about the transverse horizontal axis.

**b- Translatory or gliding movement:** It take place in the upper compartment of the TMJ, i.e. between the superior surface of the articular disk and the glenoid fossa.

These called mandibular border movement.

Mandibular movement, except the opening and closing in its most posterior position (posterior terminal hinge movement) are combination of rotation and translation, and referred to as functional movements.

**2- Functional movement:** All mandibular movements except the terminal hinge movement, are combination of rotational and transitional, are most frequently and are referred to as being functional movement. They are including:

- *Opening and closing movements*
- *Symmetrical forward and backward movements.*
- *Asymmetrical side wise movement or lateral movement.*
- The opening and closing movements are considered the most important mandibular movements and they are divided into.

- Habitual movement.
- Border movement.

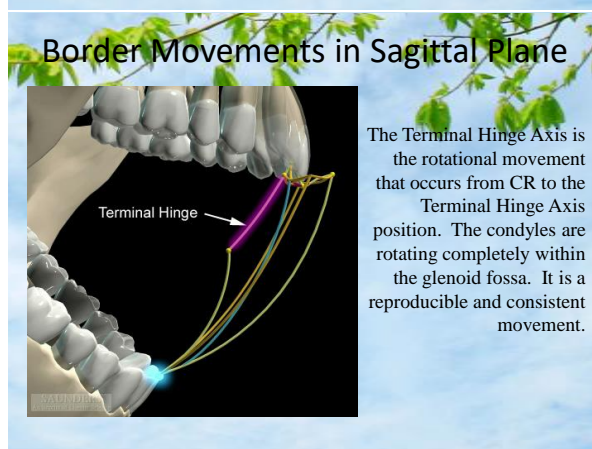
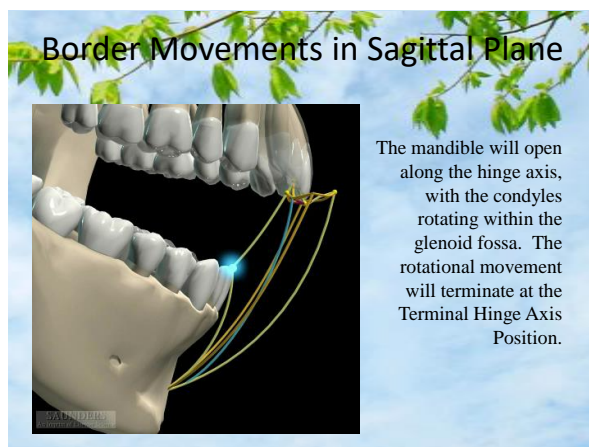
Tack place within three dimensional limits the mandible can move about (10 mm laterally), open about (50 to 60 mm), protrude approximately (9mm), and retrude about (1 mm). These limits describe by passelt in 1952 and which are known as border movements of the mandible. It's the most extreme positions to which the jaw is able to move in any direction.

The border positions are limits by nerves, bones, muscles, teeth when present and ligaments.

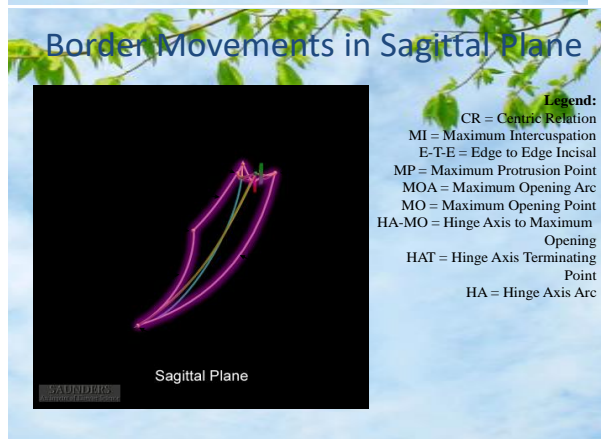
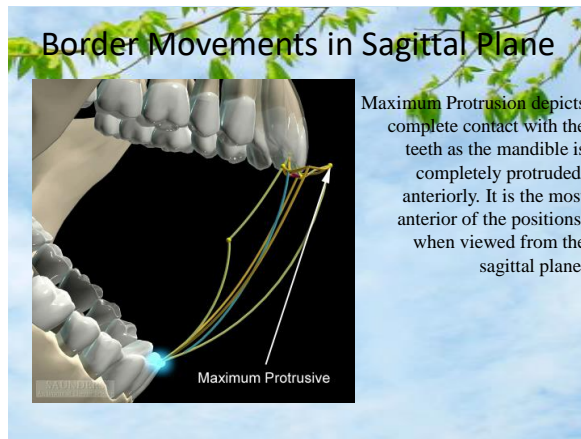
Border movements, subdivided into:

- Anterior border movement, appear as one arc in the sagittal plane, the condyles rotate and translate in this movement.
- Post border movement, appear as two arcs in the sagittal plane, the condyles rotate in the opening and closing up to the point of terminal hinge opening and translate to the point of maximal opening

### ***In the sagittal plane***







### **Sagittal plane movements:-**

A map of the boundary of the movements of mandible when viewed from one side of the head, it is tracing of the maximum vertical and anteroposterior movements of the mandibular central incisors. It includes

1- Maximum intercuspation or centric occlusion (CO) this border position is usually defined as that point where the teeth best interdigitate.

2- If the mandible is retruded farther to its posterior most superior, most terminal hinge position, the limits of movement and the border position are determined by structures of the T.M.J.

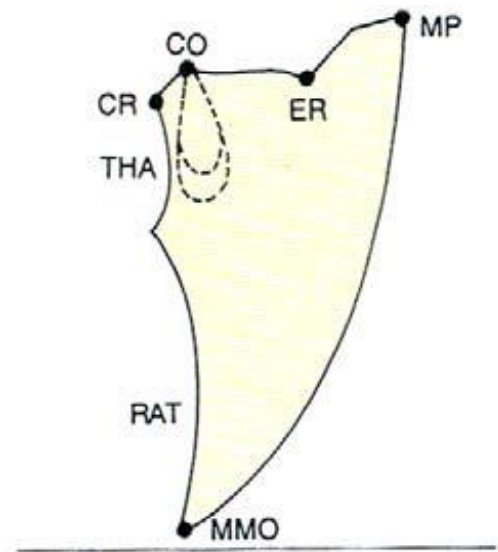
Some have also referred to this position as (Centric relation) CR. It has been defined in a number of different ways.

### **Extreme Movements in the Sagittal Plane**

A characteristic '*Beak tracing*' is formed while recording border movements in the sagittal plane. Here, the patient is instructed to move the mandible from centric relation (CR) to centric occlusion (CO), then to

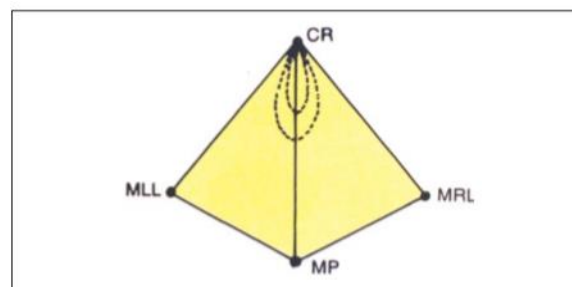
the edge to edge relationship (ER) guided by the incisal guidance, progress further forward to the maximum protrusive (MP) position and then arc downward to the maximum mouth opening (MMO) position.

Once this position is reached the operator should guide the mandible backward and close the mouth. While closing the mouth the mandible arcs upward (RAT-rotation after translation) around a transverse axis passing through the mandibular foramen. Consecutively the condyle translates back to the centric relation position where the mandible continues to arc upwards around the true hinge axis passing through the condyle (THA).



### Extreme Movements in the Horizontal Plane

Border movements recorded in the horizontal plane produced a characteristic '*Diamond tracing*'. While recording the tracing, the patient is instructed to move his mandible from the centric relation position (CR) to the maximum right lateral (MRL) position to the maximum protrusive (MP) position, to the maximum left lateral (MLL) position and return to centric. An arrow point tracing formed using Gothic arch tracers should and will coincide with this pattern.

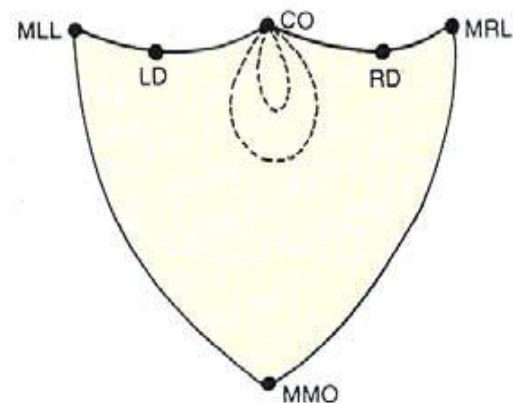


**Fig. 9.19:** Diamond tracing. Border movement recorded in the horizontal plane



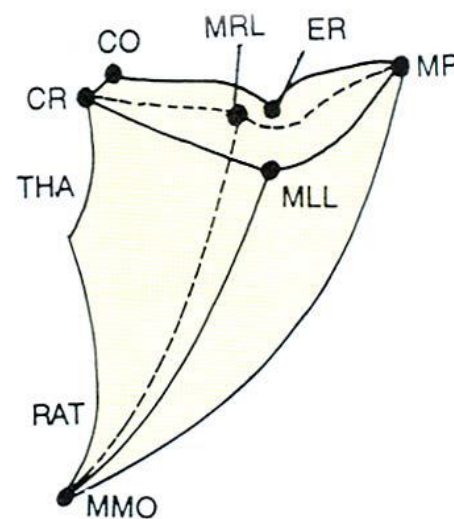
### Extreme Movements in the Coronal Plane

Border movements produced in this plane produce a characteristic 'shield tracing'. Here the patient is instructed to move his mandible from centric occlusion (CO) to canine-guided disocclusion on the right side (RD) and then to the maximum right lateral position (MRL) then arc downwards to the maximum mouth opening position (MMO). From this position, the patient is instructed to arc upward to the maximum left lateral position (MLL), return medially to canine guided disocclusion on the left side (LD) and then return to centric occlusion (CO).



### Envelope of Motion

When we combine the border movements of all the three planes, we get a three-dimensional space within which mandibular movement is possible. This three-dimensional limiting space is called the *envelope of motion*. It was first described by Posselt in 1952.



**Four movements of prime importance to complete denture service are:-**

- 1- The hinge like movement used in opening and closing the mouth for the introduction of food.
  - 2- A protrusive movement used in the grasping and incision of food.
  - 3- Right or left lateral movements for use in the reduction of fibrous as well as other types of food and
  - 4- Bennett movement – the bodily side shift of the mandible which when it occurs, may be recorded in the region of the advancing non-working side.
- Functional mandibular movements include all natural or characteristic movements occurring during mastication, swallowing, speech and yawning.
- Parafunctional movements: - movements that occur in the clenching, tapping or grinding of the teeth.

**Jaw Registration of Condylar Movements**

**What is it and why do we record it?**

It is a recording of the paths/positions of the condyles during border movements that are recorded in order to program the articulator to simulate the patient's condylar movements

**How is it recorded?**

1. Pantographic tracing to program a fully-adjustable articulator
2. Interocclusal records to program a semi-adjustable articulator

Face bow record

CR record

Protrusive record

Lateral record

**Articulator:** Mechanical Systems used to Replicate Mandibular Movement.

**Types of articulators:**

**Class I-** a simple holding instrument capable of accepting a single static registration; vertical motion is possible (e.g. .non-adjustable).

**Class II-**an instrument that permits horizontal as well as vertical motion, but does not orient the motion to the temporomandibular joints.

**Class III-**an instrument that simulates condylar pathways by using averages or mechanical equivalents for all or part of the motion; allow for

orientation of the casts relative to the joints and may be arcon or nonarcon instruments (e.g. semi-adjustable)

**Class IV**-an instrument that will accept three dimensional registrations; allow for orientation of the casts relative to the joints and simulation of mandibular movements (e.g. fully adjustable).

### **Third visit in complete denture construction (clinical step)**

Occlusal plane orientation, vertical dimension, face-bow transfer, centric relation.

#### Objectives of this visit

- Occlusal plane: - To determine the horizontal and vertical level of the teeth.
- Vertical dimension: - To determine the amount of space between the rims with jaws at rest and with the wax rims in occlusion.
- Face-bow transfer: - To record the position of the jaws as related to the opening axis of the mandible and transfer this position so that the casts on the articulator will have the same relationship to the opening axis of the patient.
- Centric relation: - To record the most posterior position of the mandible to the maxilla and transfer this position to the articulator.

**Face-bow transfer** :-A face-bow is a caliper- like device used to record the patient's maxillae/ hinge axis relationship and to transfer this relation to the articulator during mounting of the maxillary cast.

If the face-bow transfer procedure properly done, the arc of closure on the articulator should duplicate that exhibited by the patient.

#### **A face-bow transfer should be used when:-**

- Cusped posterior teeth are selected.
- Balanced occlusion in eccentric positions is desired.
- Interocclusal check records are used for verification of jaw relationships.
- The occlusal vertical dimension is subject to change.

Some authors reported that if cusp less teeth and a monoplane occlusion are selected, a face-bow transfer is unnecessary. Other recommend the use of face-bow, even for cusp less teeth to provide more accurate placement

of casts in the articulator than would be obtained by simply placing arbitrarily.

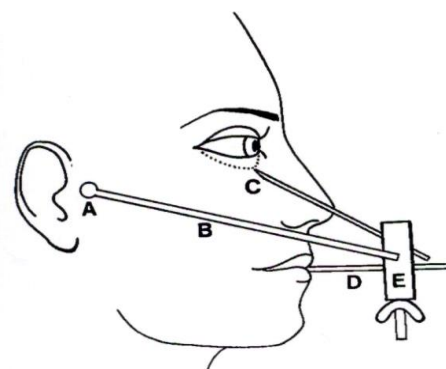
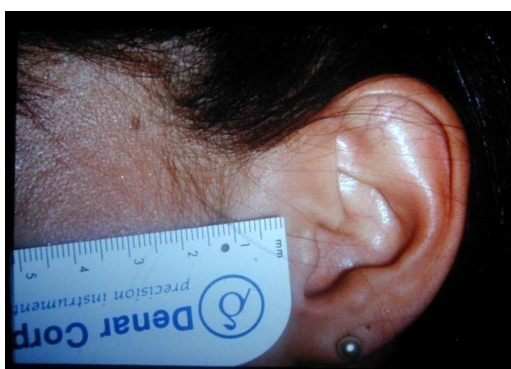There are two types of face-bow, the *kinematic and the arbitrary*.

The kinematic face-bow is initially used to accurately locate the hinge axis, it is attached to a clutch which in turn attaches to the mandibular teeth. As the mandible makes opening and closing movement, the condyle styli move in an arc. The kinematic face-bow generally not used for CD fabrication because the resiliency of the soft tissues make precise location of the rotational centers almost impossible.

Several varieties of arbitrary face-bows are available. All are based on an average location of the hinge axis. It were located over measured points on the face or by some type of earpiece. One average measurement places the rotational point 13mm anterior to the distal edge of the tragus of the ear, along a line from the superior-inferior center of the tragus to the outer canthus of the eye. The condyle styli of the face-bow are then placed directly over the dots. This technique is used with Hanau H-2 and Dentatus articulators.

### Facebow Registration

- On a fully adjustable articulator, the “true hinge axis” must be located
- On a semi-adjustable articulator, the “arbitrary hinge axis” is used, and this is determined by the manufacturer of the facebow and articulator system.



In order to understand the maxillomandibular relation and concepts of occlusion we have to study the mandibular movements.

Recording the mandibular movements affected by TMJ, muscular involvements, neuromuscular regulation of mandibular motion, and ligaments.

