



---

**DENTAL IMPLANT TREATMENT (PROSTHETIC PARTS)  
SECOND PART LEC:-**

---

ا.د. رغداء كريم جاسم

**COLLEGE OF DENTISTRY/5TH YEAR  
University of Baghdad**

## History and introduction

---

*Osseointegration* is a direct bone anchorage of an implant body, which can provide a foundation to support prosthesis. *Dr Per-Ingvar Branemark*, Sweden Professor developed the concept of osseointegration and coined the term. In his study, microcirculation, Prof. Branemark surgically inserted the titanium chamber into the tibia of a rabbit. The initial concept of Osseointegration stemmed from vital microscopic studies. Then studies that followed involved titanium implants placed into jaws of dogs.

**Oral Implantology (Implant Dentistry):** It is the science and discipline concerned with the diagnosis, design, insertion, restoration and/or management of alloplastic or autogenous oral structures to restore the loss of contour, comfort, function, esthetics, speech and/ or health of the partially or completely edentulous patient

**Implant Prosthodontics:** It is the branch of implant dentistry concerning the restorative phase following implant placement and the overall treatment plan component before the placement of dental implants.

It is the phase of prosthodontics concerning the replacement of missing teeth and/or associated structures by restorations that are attached to Dental Implants .

**Implant:-** Any object or material, such as an alloplastic substance or other tissue, which is partially or completely inserted or grafted into the body for therapeutic, diagnostic, prosthetic or experimental purposes .

**Implant Prosthesis:** Any prosthesis (fixed, removable or maxillofacial) that utilizes dental implants in part or whole for retention, support and stability.

**Implant System:** Dental implant components that are designed to mate together. An implant system can represent a specific concept, inventor, or patent.

It consists of the necessary parts and instruments to complete the implant body placement and abutment components.

**Osseointegration:** The apparent direct attachment or connection of osseous tissue to an inert, alloplastic material without intervening connective tissue

Direct bone anchorage to an implant body, which can provide a foundation to support prosthesis (Branemark, 1983).

A direct structural and functional connection between ordered living bone and the surface of a load carrying implant (Albrektsson et al., 1981).

### **Endosseous Implant/Endosteal Implant:**

A device placed into the alveolar and/basal bone of the mandible or maxilla and transacting only on cortical plate .

A device inserted into the jawbone (endosseous) to support a dental prosthesis. It is the 'tooth root' analogue and is often referred to as *fixture* (Richard Palmer).

## Implant classification

Dental implant can be classified depending on placement within tissue

- *Subperiosteal:* A CoCr casting custom made for an edentulous bony ridge and placed subperiosteally with integral trans-mucosal posts for denture retention.
- Transmandibular (transosseous) dental implants "staple boneplates":
  - The staple bone plate is used to rehabilitate the atrophic edentulous mandible.
  - It is a transosteal threaded posts which penetrate the full thickness of the mandible and pass into the oral cavity in the parasymphysial area

- *Submucosal implants*: A small “presstud- like” device within the soft tissue helping to retain a denture, usually maxillary
- *Transdental fixation*: A metal implant placed through a tooth and extended through the root canal into the periapical bone to stabilize the mobile Tooth sometimes referred to as endodontic implants This was first used by *Cuswell and Senia* in 1983
- *Endosseous—blade (plate), ramus frame, transosteal or staple, root form, or cylindrical*: These implants are anchored in bone and penetrate the oral mucosa to provide prosthetic anchorage.

### 1- Classification of endosseous implants according to their design:

- a- *Cylinders endosseous implants.*
- b- *Screws or spiral post endosseous implants.*
- c- *Blade form endosseous implants.*
- d- *Root form endosseous implants*

### 2- Classification of endosseous implants according to their material:

- a- **Pure titanium**: the titanium oxide surface was responsible for the formation of the direct bone- implant interface.
- b- **Titanium alloy**: the titanium alloys exist in three forms: alpha, beta and alpha beta phases and they all originate when pure titanium is heated and mixed with aluminium and vanadium.

### 3- Classification of endosseous implants according to surface characteristics:

- a- *Sand blasted surface.*
- b- **Titanium Plasma Sprayed surface (TPS)**, it has satisfactory results regarding the osseointegration and the clinical prognosis.
- c- **Titanium oxide surface coating** the implants to make the inert metal a bioactive one.
- d- *Hydroxyapatite coating*

### 4- Classification of endosseous implants according to the insertion technique:

- The insertion techniques of endosseous implants have been classified into either:
- a- **Press fit technique**, in this type of unthreaded implants, the implant site is drilled slightly smaller than the actual implant size, where the implant is pressed into the recipient site with slight friction.
  - b- **Self tapping technique**, in this type of threaded implants, the implant threads are used to tap its site during insertion.
  - c- **Pre-tapping technique**, in case of very dense bone, the implant sites are better to be previously tapped using the bone tap instrument before insertion of the threaded implant

### 5- Classification of endosseous implants according to surgical stages:

- a- **Single stage design (none submerged – transgingival)**: the body of the implant is inserted into the bone with its abutment portion penetrating through the mucoperiosteum during the healing period. Surgical placement of a dental implant, which is left, exposed to the oral cavity following insertion. This is the protocol used in non-submerged implant systems
- b- **Two stage design**: in this design the implant body is completely embedded in bone for complete osseointegration. The implant body is then exposed and the healing abutment is placed for soft tissue healing before the impression is made for prosthesis fabrication

### 6. Classification of endosseous implants according to the time of installation:

- a- **Immediate implants**, they are placed into a prepared extraction socket following tooth extraction.

**b- Immediate delayed implants**, they are placed within 6-12 weeks after the tooth loss.

**c- Delayed implants**, they are placed within 6-12 months after tooth extraction, when complete healing and bone remodeling occur

### **7. Classification of endosseous implants according to time of prosthetic loading:**

**a- Immediately loaded implants**, an acrylic resin prosthesis which is designed to be out of occlusion is placed immediately after implant placement, specially in anterior region for esthetic purposes.

**b- Delayed loading implant**, delayed loading is done in maxillary implants after 4-6 months and in mandibular implants after 3-4 months to allow for better osseointegration due to the difference of the investing bone composition

### **Factors affecting healing**

#### **1- Surgical technique**

All surgical procedures are traumatic. The level of trauma is a critical factor that determines whether healing will progress toward fibrous or osseous integration. Surgical preparation on hard tissue causes a necrotic zone of bone (interface) due to cutting of blood vessels, frictional heat, and vibrational trauma.

Excessive trauma leads to fibrous encapsulation of the implant.

Surgical trauma must be minimized during all aspects of implant surgery to optimize success rates. The temperature for impaired bone regeneration has shown to be as low as 44 C° to 47 C° for one minute.

#### **2- Premature loading**

Time should be allowed for healing of necrotic bone, formed due to surgery. Movement of the implant during this healing phase will result in fibrous encapsulation. For this reason it is recommended by many operators to keep the recently placed implants unloaded for a period of two to eight months depending on the *clinical situation, implant coating, location of the implant, and whether the implant is placed into bone grafts.*

#### **3- Surgical fit**

Even with the best technical precautions, bone contacts only portions of the implant and a perfect microscopic contact is not possible. A longer healing period will be required before loading implants then surgical fit less than optimal

#### **4- Bone quality and quantity**

The mandible has a denser cortex and a coarser thicker cancelli than the maxilla. When we go posterior, jaws tend to have a thinner, more porous cortex, and a finer cancelli. Bone regeneration is more likely to progress at a faster rate if the surrounding is denser. it is very frequent to find that bone amount is not enough for implant placement.

The following measures can be done to overcome this problem:

- The use of shot implants.
- Changing the implant angulations.
- Ridge augmentation.
- Trans positioning of the neurovascular bundle in the mandible.
- Subantral augmentation (sinus lift) in the maxilla.
- Bone synthesis (ossified tissue can be created in predetermined shapes and dimensions).

#### **5- Physical condition of the patient:**

Nutritional status, aging, diabetes mellitus, blood diseases, corticosteroids therapy and radiation treatment are among many factors which can affect healing.

### **Team approach**

- ✓ Some authors believe that the same operator should place and restore the implants. The rationale is that it is more efficient from a patient's point of view. It also allows the practitioner more freedom in changing the predetermined position of the implants at the time of surgery. Because the same individual is responsible for the prosthetic treatment, these changes can be incorporated into the treatment plan more readily.
- ✓ Others believe that a team approach is more appropriate to follow. A surgeon should place the implants, and a prosthetic dentist should complete the restoration. Because it allows for the utilization of expertise of the two individuals, there is a built-in second opinion in the approach. Additionally, there is shared responsibility and shared liability. Regardless of the philosophy followed, it is well to delineate the responsibilities at each stage of implant therapy, and it should be clear that dental implant is *a prosthetic technique with a surgical step*.

#### **The prosthodontic should:**

- 1- Perform the initial clinical evaluation.
- 2- Perform the initial radiographic evaluation.
- 3- Obtain the diagnostic casts.
- 4- Obtain the diagnostic wax-up.
- 5- Determine the location and number of implants and fabricate a surgical template.
- 6- Select the proper abutment following the implant exposure.
- 7- Design and fabricate the prosthesis.
- 8- Provide oral hygiene care and instructions.
- 9- Ensure recall of the patient to evaluate maintenance and provide care as required.

#### **The oral surgeon responsibilities include:**

- 1- Confirmation of the radiographic evaluation.
- 2- Confirmation of the physical evaluation.
- 3- Determination of the location and number of implants within limits set by the prosthetic dentist.
- 4- Placement of the implants (first stage surgery).
- 5- Uncovering of the implants (second stage surgery).
- 6- Confirmation of osseointegration of the implants.

### **COMPONENTS OF BRANEMARK IMPLANT SYSTEM as in figure -**

#### **I. Implant Fixture/Implant Body**

The portion of a dental implant that provides support for the abutment(s) through adaptation upon (eposteal), within (endosteal) or through (transosteal) the bone. The body is that portion of the implant designed to be surgically placed into the bone. It may extend slightly above the crest of the ridge.

#### **II. Healing/Cover Screw**

The component of an endosteal dental implant system used to seal, usually on an interim basis, the dental implant body during the healing phase after surgical placement. The purpose of the healing screw is to maintain patency of the internal threaded section for subsequent attachment of the abutment during the second stage surgery.

#### **III. Healing Abutment/Interim Endosteal Dental Implant Abutment**

Any dental implant abutment used for a limited time to assist in healing or modification of the adjacent tissues.



After a prescribed healing period that allows a supporting interface to develop, second stage surgery is performed to uncover or expose the implant and attach the transepithelial portion or abutment. This transepithelial portion is termed a second stage permucosal extension, because it extends the implant above the soft tissue and results in the development of a permucosal seal around the implant.

#### **IV. Implant Abutment**

The portion of a dental implant that serves to support and/or retain any prosthesis .

Three main categories of implant abutments are described according to the method by which the prosthesis or superstructure is retained to the abutment:

- (i) an abutment for screw uses a screw to retain the prosthesis or superstructure;
- (ii) an abutment for cement uses dental cement to retain the prosthesis or superstructure;
- (iii) an abutment for attachment uses an attachment device to retain the removable prosthesis.

Many manufacturers classify abutments as fixed whenever cement retains the prosthesis and removable when they are screw retained. Each of the three types of abutments is further classified into straight and angled abutments, describing the axial relationship between the implant body and abutment.

#### **V. Hygiene Screw**

It is placed over the abutment between prosthetic appointments to prevent debris and calculus from entering the internally threaded portion of the implant.

#### **VI. Transfer Coping/Impression Coping**

Any device that registers the position of the dental implant body or dental implant abutment relative to adjacent structures.

#### **VII. Implant Analog**

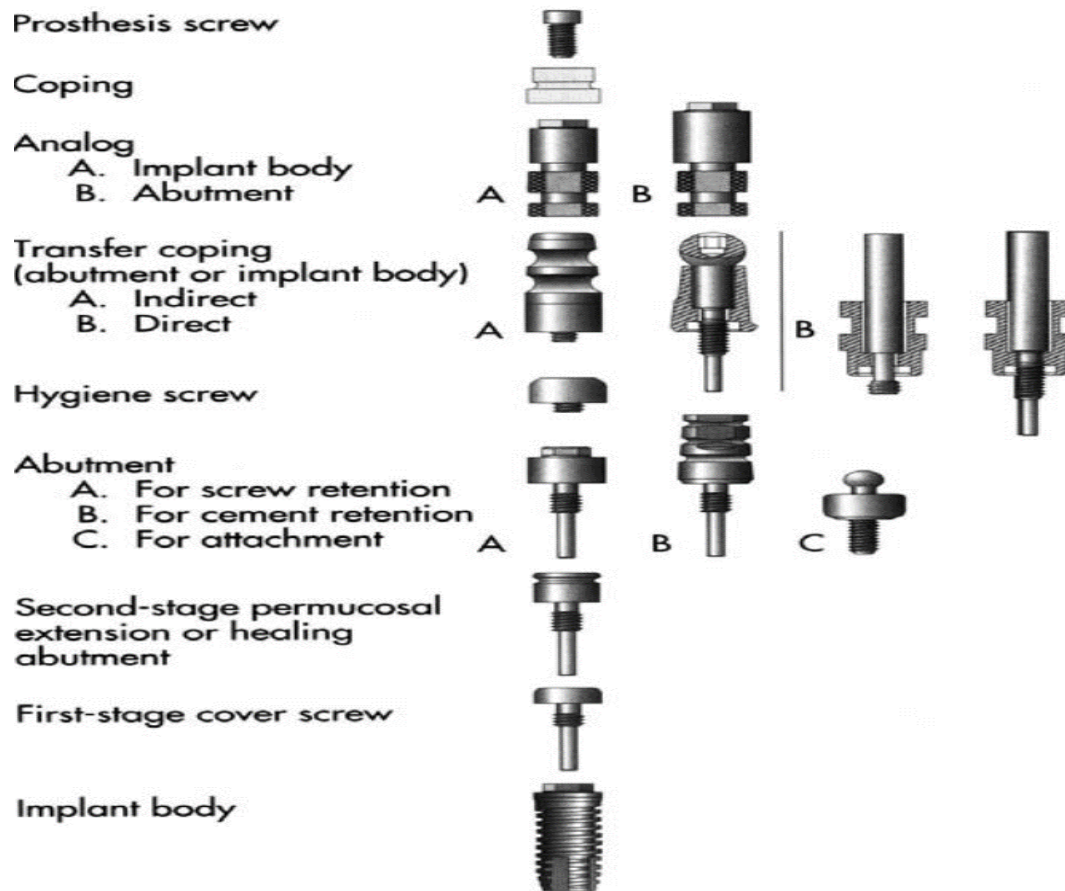
An analog is something that is analogous or similar to something else. Implant analog is used in the fabrication of the master cast to replicate the retentive portion of the implant body or abutment. After the master impression is secured the corresponding analog (implant body, abutment for screw or other portion) is attached to the transfer coping and the assembly is poured in stone to fabricate the master cast.

#### **VIII. Coping/Gold Cylinder**

It is a thin covering usually designed to fit the implant abutment and serve as the connection between the abutment and the prosthesis or superstructure. A prefabricated coping usually is a plastic pattern cast into the metal superstructure or prosthesis.

#### **IX. Coping Screw**

The screw retained prosthesis or superstructure is secured to the implant body or abutment with a coping screw.



**Figure -1 component of Branemark implant system**

**PROSTHETIC OPTIONS IN IMPLANT DENTISTRY**

- A. Implant supported single tooth
- B. Implant supported fixed bridge or partial denture
- C. Fully Bone Anchored Prosthesis, Implant supported full arch prosthesis screw retained
- D. implant supported over denture

**Fully Bone Anchored Prosthesis fig -2**

The fully bone anchored prosthesis is connected to supporting fixtures through the transmucosal components, the abutments either in the maxilla/mandible. To provide proper support for a fully bone anchored prosthesis a minimum of four to six fixtures are necessary.

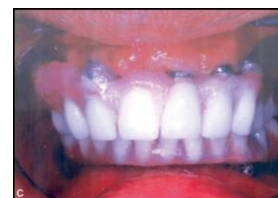Ideally a fifteen millimeter length/longer should be placed when there is adequate bone. If bone density and quality is poor, the number of fixtures should be increased.

Design

Fully bone anchored prosthesis does not obturate the space between the prosthesis and residual tissues.

Advantages

- Satisfies functional demands.
- Greater psychological acceptance.

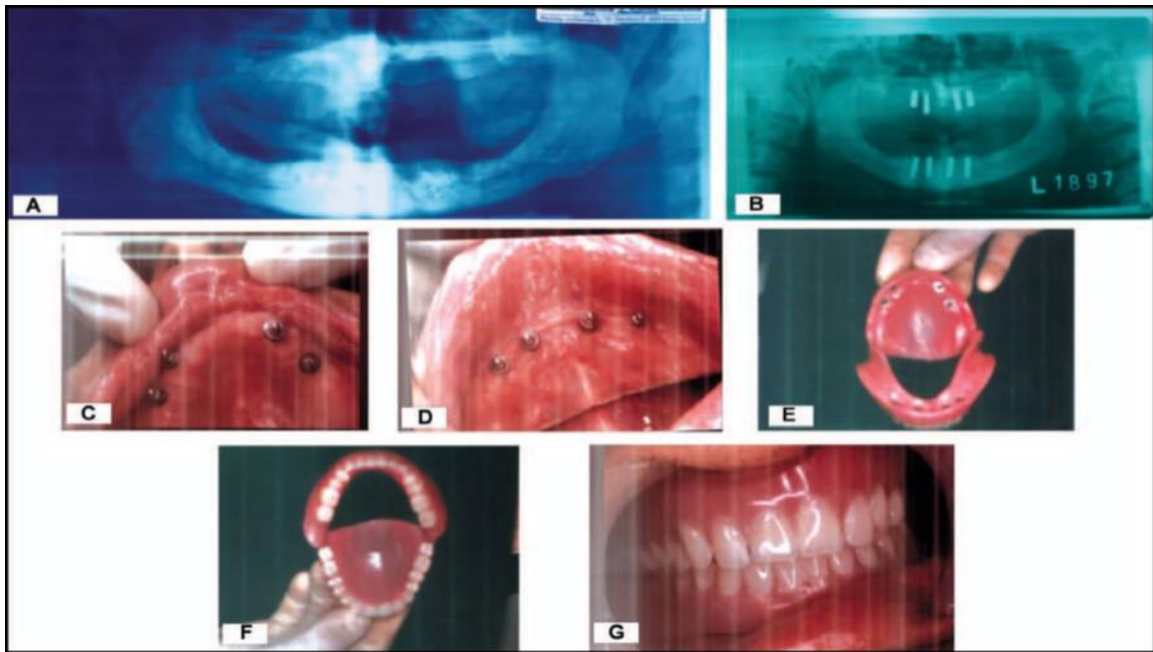


### Disadvantages

- Airflow pattern produced during speech is unimpeded, which may present problems for the patient if their occupation requires good speaking ability.

### **Overdenture(implant supported overdenture)**

Implant supported overdenture is a treatment of choice in case of soft/hard tissue defects, Esthetics can be improved by increasing or decreasing the amount of denture base material. This change in design can enhance lip and facial support. Overdenture is attached to supporting fixtures using various connectors or attachments, which usually do not alter esthetic results. Minimum of two fixtures are needed for support.



### **BASIC SEQUENCE OF PROCEDURES IN IMPLANTS TREATMENT**

#### **a.Chief Complaint:**

The practitioner must determine which is the most important for the patients, aesthetic, mastication or phonation. This requires careful listening and sufficient time

#### **b.Physical Evaluation:**

The medical history normally taken in the modern dental office often is enough for implant patient. It must be kept in mind that there are few contraindications to the use of dental implants. Proper evaluation should be made whether the patient can tolerate the planned procedures or not consultation with the surgeon at this point may be necessary to arrive at proper evaluation in- patients with complicated medical history.

The physical ability or limitations of the patient also play a part in the design of the prosthesis, the selection of the final restoration.

#### **c.Psychological Evaluation**

One must realize that. For many patients, the perception of what constitutes implant therapy has been formed from information provided by friends, publications, and other mass media. This is not necessarily all negative, because it results in the patient seeking implant therapy. Many times, however, the patient cannot properly evaluate the information, and limitations



of therapy are not clearly understood therefore, it is necessary to educate the patient concerning the necessity of specific procedures for the case.

#### **d.Dental Evaluation**

In addition to the usual dental evaluation,

- the prosthodontist must incorporate into this evaluation the possible effects of the conditions present in the oral cavity on implants placed in this environment.
- A history of bruxism, mal-aligned dentition and extruded teeth, which preclude the development of harmonious occlusion and a hygienic restoration should alert the operator to problems in this area. The patient's commitment to a life long- term maintenance program must be evaluated.

#### **e.Bone**

The age of the patient and the amount and type of bone available to support the implants must be determined through the following:

1. radiographs evaluation, The types of radiographs used depend on the number of implants to be placed, the location in the jaws, and the availability of the equipment.
2. Another method, which can be used in determining the amount of bone available, is palpation. This method is particularly useful in the mandible. It is often possible to encircle the mandible completely with forefinger and thumb and obtain an indication of the size and shape of the arch at a particular point.

#### **f.Soft tissue**

The soft tissue through which implants exist in the oral cavity is a critical area in terms of long- term success. This is the area that the patient must maintain to ensure gingival health and therefore must be capable of withstanding the hygiene manipulation (brushing and flossing). Fixed keratinized tissue is the preferred tissue in this area. This is the only type of tissue that has ability to form a tight collar around the implant necks. If soft tissue grafting is anticipated, it is probably best done before implant placement.

#### **h.Ridge relationships**

The relationship of the maxilla to the mandible plays an important role in determining the type of prosthesis that can be done and is a deciding factor in the type of occlusion that can often be determined by visual examination, the best observation of this relationship is achieved from mounted diagnostic casts.

#### **i.Radiographic evaluation**

radiological evaluation for determination of sufficient bone quantity and quality to support the implants must be done. The choice of radiological technique appropriate for a given patient depends on a number of factors, including the *type of restoration and implants to be used, the position of the remaining dentition, the extent to which bone quality or quantity is in question, the availability of the machine needed, and the coast.* The following radiological techniques are available:

- 1- Periapical radiographs.
- 2- Panoramic radiographs.
- 3- Lateral cephalometric radiographs
- 4- Conventional tomograms (CT).
- 5- Computed tomography.
- 6- Magnetic resonance imaging(MRI)

A marker of known size should be placed directly on the mucosa during the exposure, when a periapical or panoramic radiographs was selected as the preferable technique. The aim of

placing such marker (metal ball of known diameter) is the determination of actual ridge height because ordinary radiographs do not have one- to one correspondence with regard to size. For example, if the actual diameter of the marker is 5 mm. However, on the panoramic film they measure 6 mm., a 20% magnification occurred. Therefore, if the bone measure above the inferior dental canal is measured 22 mm on the film only 18.3 mm is actually available.

**A. Radiographic Stent**

A diagnostic template incorporating stainless steel balls is used for treatment planning of the implant position. The actual diameter and position of the stainless steel balls in the template relative to the diameter and the position measured on the radiograph help determine distortion of size and position as seen on the radiographs.

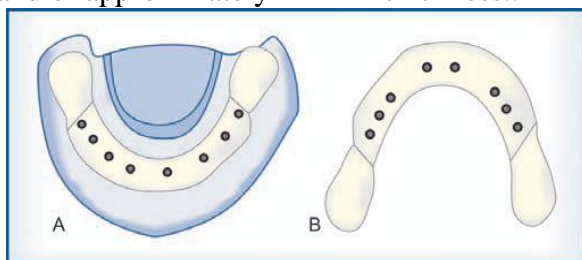
In the maxilla the vertical bone between the floor of maxillary sinus-alveolar crest and nasal floor-alveolar crest is evaluated. In mandible distance from inferior dental canal or mental foramen is evaluated.

**Surgical Template** As mentioned in radiographic splint, surgical template can be fabricated by duplicating the existing denture or a newly fabricated prosthesis. Once the position of the implants is determined by palpation clinical, radiographic and diagnostic cast examination, the surgical stent is fabricated.

There are two main functions for the stent,

- 1) guide the operator to the selected places for implant placement
- 2) to direct the operator drill to a proper direction through which he should drill in bone

The surgical stent can be fabricated using a clear heatcured or autopolymerized acrylic resin and of approximately 4mm in thickness..

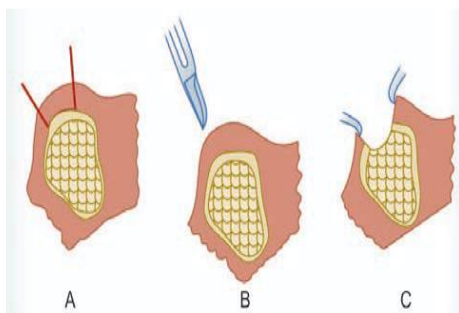


**Fig 2: A. radiographic splint**

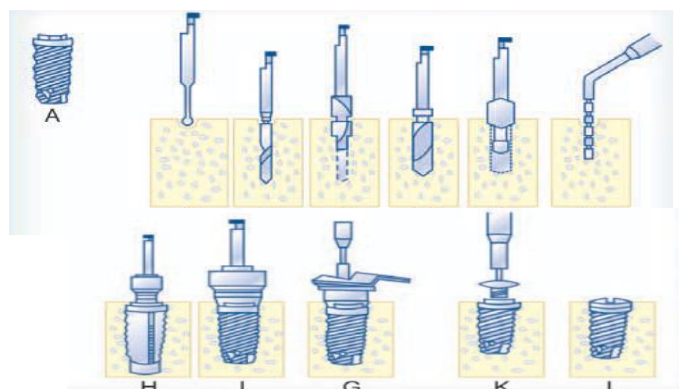
**B. Surgical stent**

**First Stage Surgery** The following case demonstrates the placement of Branemark implant

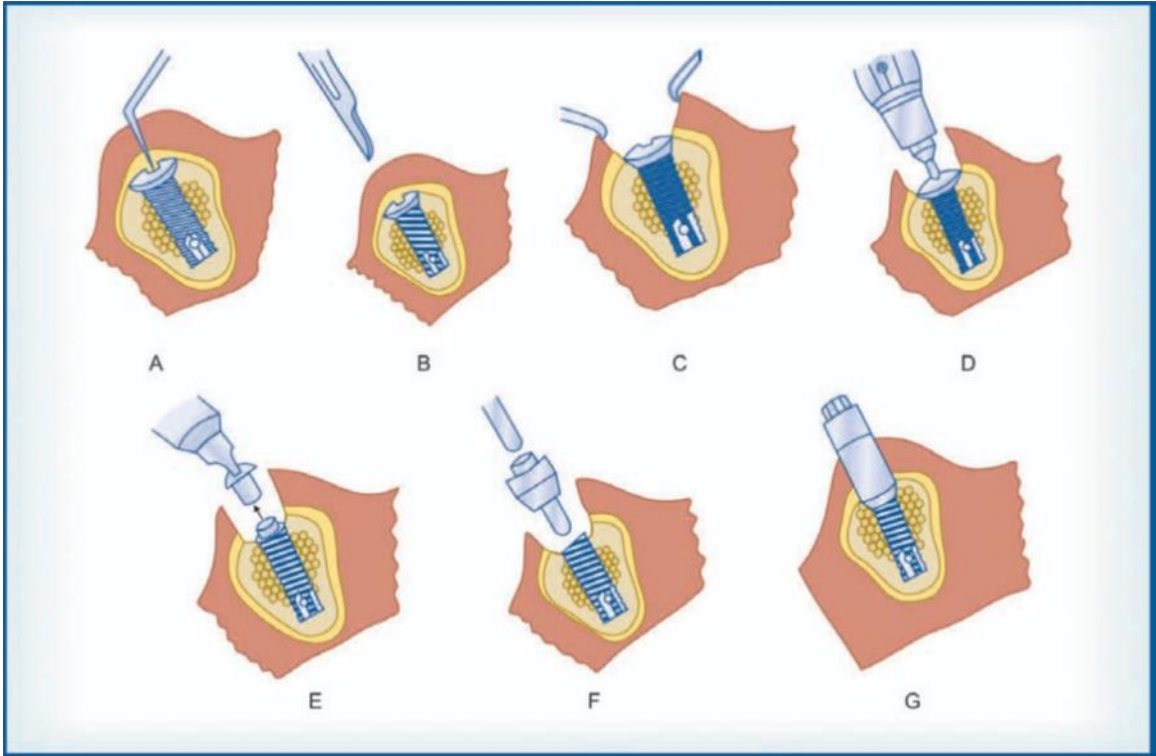
**Second Stage Surgery** The uncovering of the implant is carried out after a healing phase of at least 4 months. The gingival former is screwed onto the implant and the flap sutured around



The bone is exposed by an incision and reflection of mucosal membrane and periosteum (full thickness flap)



Procedure for implant placement



Second stage surgery

---

## DENTAL IMPLANT TREATMENT (PROSTHETIC PARTS)

### SECOND PART LEC:-

---

اد رغاء كريم جاسم

#### D.Imression

**After complete healing of gum about 2weeks ,next step impression making.**

Occlusion rims are used to establish maxilla mandibular relations followed by trial of the waxed up then denture and final denture insertion.

**Classification of impression techniques according to the level of impression into:-**

- a. Implant level impression techniques(open and closed impression techniques)
- b. Abutment level impression techniques

**Two basic techniques are used to make a master impression, and each use a different transfer coping based on the transfer technique performed in the mouth or on a master cast (implant level).**

1. An indirect transfer coping (closed tray impression techniques) utilizes an impression material requiring elastic properties. The indirect transfer coping is screwed into the abutment or implant body and remains in place when the set impression is removed from the mouth. The indirect transfer coping is parallel sided or slightly tapered to allow ease in removal of the impression and often has flat sides or smooth undercuts to facilitate reorientation into the impression.
2. A direct transfer coping (open tray techniques) usually consists of a hollow transfer component, often square and a long screw to secure it to the abutment or implant body. After the impression material is set the direct transfer coping screw is unthreaded to allow removal of the impression from the mouth.  
The direct transfer coping takes advantage of impression materials having rigid properties or eliminates the error of permanent deformation because it remains within the impression on its removal.

E . Base plate/modeling wax are used to fabricate the occlusion rim in the usual fashion.  
Wax

#### **Implant success and survival**

success criteria as follows:

- The individual implant should be *clinically immobile*.
- There should be *no radiographic radiolucency*.
- There should be an *absence of persistent pain, infections, neuropathies, and paresthesia*.
- There should be *85% implant survival at the end of a 5-year period* of observation and *80% at the end of a 10-year* observation period.
- There should be *less than 0.2 mm of bone loss annually* following the implant's first year of loading.

Roos et al. (1997) proposed an update to these criteria to reflect that, as implant design evolved, early bone loss could be further minimized.

The new criteria suggested a figure of <1.8 mm bone loss for the first 5 years.

- Less than 1.0 mm bone loss in the first year
- Less than 0.2 mm bone loss annually after the first year
- Functional survival of 90% after 5 years and 85% after 10 years

## **INDICATIONS OF IMPLANT DENTURE**

1. Edentulous patient with history of difficulty in wearing removable dentures.
2. When there is severe change in complete denture bearing tissues.
3. Poor oral muscular coordination.
4. Para-functional habits that compromise prosthesis stability.
5. Unrealistic patient expectations for complete dentures.
6. Hyperactive gag reflex.
7. Low tissue tolerance of supporting mucosa.

## **CONTRADICTIONS OF IMPLANT DENTURE**

1. High dose irradiated patients.
2. Patient with psychiatric problems such as psychosis, dysthorphobia.
3. Hematological systemic disorders.
4. Pathology of hard and soft tissues.
5. Patient with drug, alcohol or tobacco chewing abuse.

## **CHARACTERISTICS OF THE OSSEOINTEGRATED IMPLANT**

- The most important characteristic of this osseointegrated implant is that the direct bone anchorage can support a freestanding fixed prosthesis.
- Occlusal forces generated by patients with fully bone anchored prosthesis are said to approximate the forces recorded in patients with natural dentitions.
- The patient with fully bone-anchored prosthesis has masticatory functions similar to natural dentition.
- This kind of implant can be retrieved in case of failure and another fixture placed at a later time.

## **BASIC GUIDING FACTORS OF OSSEOINTEGRATION**

### **1. Biocompatibility of Implant Material**

Materials used for fabrication of dental implants can be categorized in two different ways. From a fundamental chemical point of view, dental implants fall into one of the following three primary groups: (a) *Metal* (b) *Ceramics* (c) *Polymers*.

In addition biomaterials can be classified based on the type of biologic response they elicit when implanted and the long-term interaction that develops with the host tissue. Three major types of biodynamic activity are (a) *Biotolerant* (b) *Bioinert* (c) *Bioactive*. The different levels of biocompatibility emphasize the fact that no material is completely accepted by the biologic environment. To optimize biologic performance, artificial structures should be selected to minimize the negative biologic response while ensuring adequate function.

Metals for implants have been selected based on a number of factors: their biomechanical properties, previous experience with processing, treating, machining, finishing and suitability for common sterilization procedures. Titanium (Ti) and its alloys (mainly Ti-6Al- 4V) have become the metals of choice for endosseous parts of currently available implants. Implants made of *commercially pure titanium CpTi*

### **2. Implant Design**

Implant design refers to the 3-dimensional structure of the implant, with all the elements and characteristics that compose it. Endosseous dental implants exist in a wide variety of



designs with the main objective in every instance being the long-term success of osseointegrated interface and uncomplicated function of the prosthetic replacement. It has great influence on initial stability and subsequent function.

The main design parameters are:

➤ *Implant Length*

Implants are generally available in lengths from about 6 mm to as much as 20 mm. The most common lengths employed are between 8 and 15 mm, which correspond quite closely to normal root length.

➤ *Implant Diameter*

A minimum diameter of 3.25 mm is required to ensure adequate implant strength. Implant diameter is more important than implant length in the distribution of load to the surrounding bone.

➤ *Implant Shape*

Hollow cylinders, solid cylinders, hollow screws or solid screws are commonly employed shapes, which are designed to maximize the potential area for osseointegration and provide good initial stability. Screw shaped implants also offer good load distribution characteristics in function.

Dental implants are also categorized into

- ✓ *Threaded screw implants* are threaded into a bone site and have obvious macroscopic retentive elements for initial bone fixation. The fixture with threaded surface has :-
  - a. Larger surface area and the threads also help to balance the force distribution into the surrounding bone tissue.
  - b. The threads created in the bone site play an important role in initial implant fixation.
- ✓ *non-threaded, cylindrical or press fit.* The press fit implants depend on microscopic retention and or bonding to the bone, and usually are pushed or tapped into a prepared bone site

Precision fit of the fixture called primary stability is an essential element for osseointegration, the failure of which leads to soft tissue proliferation between the fixture and bone rather than direct bone interface

➤ *Surface Characteristics*

The quality of the implant surface influences wound healing at the implantation site and subsequently effect osseointegration.

*Smooth surface:* Wennerberg and Coworkers suggested that smooth be used to describe abutments, whereas the terms minimally rough (0.5 to 1  $\mu\text{m}$ ), intermediately rough (1 to 2  $\mu\text{m}$ ) and rough (2 to 3  $\mu\text{m}$ ) be used for implant surfaces.

*Rough surface:* Plasma spray coating is one of the most common methods for surface modification.

- *Plasma spraying*
- *blasting with particles.* In this approach, the implant surface is bombarded with particles of aluminium oxide ( $\text{Al}_2\text{O}_3$ ) or titanium oxide ( $\text{TiO}_2$ ) and by abrasion; a rough surface is produced with irregular pits and depressions. Roughness depends on particle size, time of blasting, pressure and distance from the source of particles to the implant surface.

- ***Chemical etching*** is another process by which surface roughness can be increased. The metallic implant is immersed into an acidic solution, which erodes its surface, creating pits of specific dimensions and shape.

Concentration of the acidic solution, time and temperature are factors determining the result of chemical attack and microstructure of the surface.

- ***Porous***: Porous sintered surfaces are produced when spherical powders of metallic or ceramic material become a coherent mass with the metallic core of the implant body. Lack of sharp edges is what distinguishes these from rough surfaces.


Porous surfaces are characterized by *pore size, pore shape, pore volume and pore depth*, which is affected by the size of spherical particles, temperature and pressure conditions of the sintering chamber.

- ***Prosthetic Interface*** It is the *level at which the superstructure or the abutment connects to the implant body*. It can be either

- *external*. The most common external connection is the *hexagonal (“hex”) type*. The 0.7 mm high, 2.7 mm wide, straight external hex on a 4.1 mm diameter platform is considered the industry’s standard. Due to its strength and stability limitations, however, variations in the hex and platform have evolved. The standard external hex allows 4.0° to 6.7° of rotational wobble with 3°-5° of tipping depending on the type of hex. Full seating of abutment over fixture can only be verified by taking additional radiographs. Without intimate contact between the walls of the mating hexes, cyclic loading transmits forces directly to the fixation screw, which may cause it to repeatedly loosen.
- An *internal hex* in the implant is designed to prevent rotation of the abutments. Compared to an external hex, an internal hex allows a better protection against rotation of abutments and against gap formation at the implant abutment interface.
- *External spline* by Calcitek acknowledges that its 0.4 mm spline connection allows 3° tipping thereby transferring forces to the abutment screw under lateral loading. However the butt joint shoulder of the spline connection can also trap soft tissue during abutment seating. Furthermore the 1.0 mm height of the spline connection can interfere with occlusal clearance and hinder establishment of anatomical contours on angled abutments.
- *Non-hexed conical connection* is an ITI implant design which has a conical opening to an internally threaded shaft. Tightening an abutment with a matching conical surface provides lateral stability. It provides no interdigitation to resist rotation, which is of some significance in single tooth restorations. In order to assure contact with the mating conical surface, the abutment cannot be designed to seat on the top surface or ‘shoulder’ of the implant. This limitation prevents the use of abutments wider than the diameter of the conical opening and leaves the shoulder exposed to support the restoration. Without flush fitting abutments, there is no opportunity to prepare the margins to follow the natural contour of the tissue.
- *Non-hexed morse taper connection* .
  - a. A 1°-2° tapered abutment post frictionally fits into the non-threaded shaft of the implant, which has a matching taper.
  - b. The body of implant is designed with a series of fins for a press fit insertion procedure.

- c. The connection also dictates how abutments are attached and stabilized and the type of emergence profile they can provide. However there are several potential esthetic and hygienic limitations with this connection.

Fig 2 (A) Standard external hex  
 (B) Internal hex  
 (C) External spline  
 (D) Non-hexed conical connection  
 (E) Non-hexed morse taper repeated as easily as tightening a screw with a torque wrench, and will not work if the abutment hits the bone crest before the taper interlocks.



○ **Bone Factor**

The stability of the implant at the time of placement is very important and is dependent upon bone quantity, quality as well as implants design. Bone, which is predominantly cortical, may offer good initial stability at implant placement but is more easily damaged by overheating during the drilling process, especially with sites more than 10 mm in depth. Success is highly dependent upon a surgical technique, which avoids heating the bone. Bone should not be heated beyond 43°C, since alkaline phosphate begins to breakdown. Gentle surgical technique with the speed of drilling equipment not to exceed 2000 rpm and copious amount of sterile irrigation with internally irrigated drills should be used.

Factors that compromise bone quality are infection, irradiation and heavy smoking. Their effects results in diminution of the vascular supply to the bone which compromises healing response, a feature that has been well described in the healing of fractures.

○ **Loading Conditions**

Following installation of an implant it is important that it is not loaded during the early healing phase. Movement of the implant within the bone at this stage results in fibrous tissue encapsulation rather than osseointegration.

This has been compared to the healing of a fracture where stabilization prevents non-union. The Branemark system emphasizes on maintaining the fixtures unloaded for six months in the maxilla and three to four months in the mandible, mainly because of differences in bone quality.

*No loading while healing* is the basic guide to osseointegration.

The surgical procedures are divided into two stages.

- 1) The first stage is the installation of the fixtures into bone, allowing a 3 to 6 month healing period. The mucosa supported interim denture should not be worn for 1 to 2 weeks, which also helps to prevent breakdown of the soft tissue wound. Bone healing begins within first week after insertion of the fixture and reaches a peak at the third or fourth weeks. The initial healing tissues gradually become bony tissue after six to eight weeks. If fixtures are displaced or loaded during this interim healing period, fibrous tissue formation will occur.
- 2) The second stage is the connection of abutments to fixture. the two stage surgical procedures are very important for successful osseointegration. Following the recommended healing period (3-6 months) abutments are connected to the implant to allow construction of prosthesis.

**Occlusion in implant-supported prostheses**

There are a few innate differences between natural teeth and implants, which need to be considered when restoring implants.

Natural teeth are associated with high occlusal awareness (proprioception) of about 20  $\mu$ m besides the proprioception, the presence of periodontal ligament as a shock absorber in a natural tooth brings about an apical intrusion.

Occlusal no proprioception in implants. The lack of proprioception and the absence of periodontal shock absorption are often associated with increased impact force with an implant-supported prosthesis than with a tooth-supported prosthesis

In case of occlusal trauma, mobility can develop in a tooth as well as in an implant. However, upon removal of the trauma, mobility can be reduced or controlled with a natural tooth, while no such response can be noted in an implant.

In general the diameter of natural teeth is larger than the diameter of implants.

Also, the cross-section of implants is rounded and the diameter is selected primarily according to bone available, not according to the load that it is anticipated to be subjected to.

*The issue of such differences between natural teeth and implants lead to the establishment of implant-protected occlusion (IPO) It is also called medially positioned lingualized occlusion, and it stems from the change in relation of the edentulous maxillary ridge to the mandibular ridge due to resorption of edentulous ridges in a medial direction. As a result, a few unique concepts are associated with implant-supported prosthesis and these constitute the guidelines for IPO*

#### **Occlusal form and scheme**

*-Where a single implant is to be restored, or a small implant bridge provided, the occlusal scheme should be confirmative. Group function is to be preferred to canine guidance,*

*-Where a full arch construction is utilized then 'balanced articulation' should be provided in order to minimize local loading and maximize stability of the prosthesis.*

There is some evidence that a degree of horizontal freedom of movement is helpful, shallow cusp angles may be associated with reduced horizontal loading of an implant during mastication.