

Classification of malocclusion

Angle classification

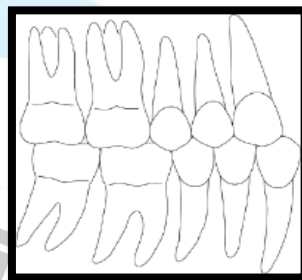
A classification of malocclusion introduced by E. H. Angle, based on the anteroposterior relationship of the maxillary and mandibular first permanent molars. Angle's assumption when formulating this classification was that the maxillary first permanent molar always is in the physiologically correct position and the variability comes from the mandible.

Angle's classification, which is still widely popular, only can serve as a framework, as it does not take into account many other important relationships in the anteroposterior (e.g. overjet, canine relationship), transverse (e.g. buccolingual crossbites), or vertical (e.g. overbite) planes of space. It also does not identify intra-arch problems, such as crowding, spacing, rotations, missing or impacted teeth.

Angle's classification subdivided into:

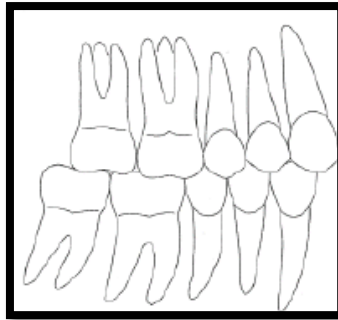
• Class I malocclusion (Neutroclusion)

A malocclusion in which the buccal groove of the mandibular first permanent molar occludes with the mesiobuccal cusp of the maxillary first permanent molar. The term "Class I" is sometimes used incorrectly as a synonym for normal occlusion, although in reality, it only signifies a normal relationship of maxillary and mandibular first molars in the sagittal plane.



• Class II malocclusion (Distocclusion, Postnormal occlusion):

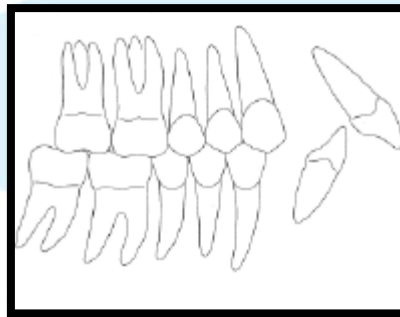
A malocclusion in which the buccal groove of the mandibular first permanent molar occludes posterior (distal by at least half cusp) to the mesiobuccal cusp of the maxillary first permanent molar. The severity of the deviation from the Class I molar relationship usually is indicated in fractions (or multiples) of the mesiodistal width of a premolar crown ("cusp" or "unit").



Subdivided into:

• **Class II malocclusion, Division 1:**

A Class II malocclusion with proclined maxillary incisors, resulting in an increased overjet with normal or mostly deepbite.



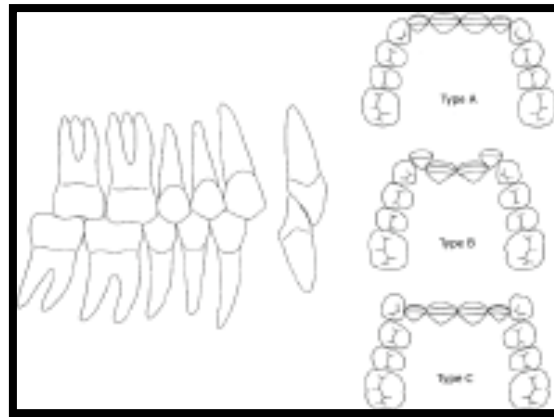
• **Class II malocclusion, Division 2:**

A Class II malocclusion typically with the maxillary central incisors tipped palatally, a short anterior lower face height, an excessive overbite and normal or decreasing overjet. Three types of Class II Division 2 malocclusion can be distinguished, based on differences in the spatial conditions in the maxillary dental arch:

Type A: The four maxillary permanent incisors are tipped palatally, without the occurrence of crowding.

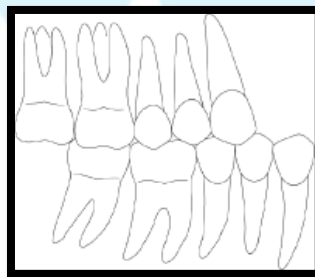
Type B: The maxillary central incisors are tipped palatally and the maxillary laterals are tipped labially.

Type C: The four maxillary permanent incisors are tipped palatally, with the canines labially positioned.



• **Class III malocclusion (Mesioclusion, Prenormal occlusion):**

A malocclusion in which the buccal groove of the mandibular first permanent molar occludes anterior (mesial by at least half cusp) to the mesiobuccal cusp of the maxillary first permanent molar. The same conventions as described before are used to indicate the severity of deviation from a Class I molar relationship.



Important notes:

- 1-Usually when we talk about angles classification we talk about first permanent molar relation (and some time we notice that this relation not symmetrical in both side).
- 2- When there is missing of the first permanent molar or there is drifting as a result of an early loss of deciduous molars so we shift to another classification which is canine classification ,and if there is no canine or impacted canine or severely malposed canine so we shift to another classification which is incisor classification.

Canine classification:

Class I: It is a normal canine relation, when the tip of the upper canines located in the embrasure area between lower canine and first premolar (or the mesial slope of the upper canine coincide with the distal slop of lower canine) in occlusion.

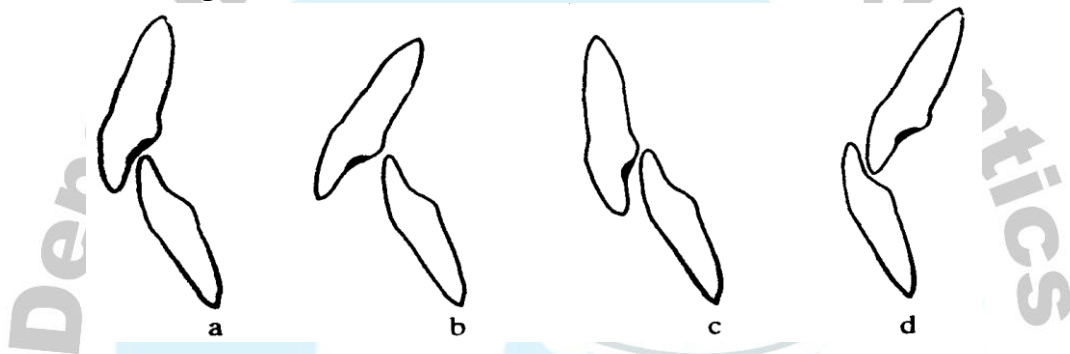
Class II: Abnormal canine relation in which the lower canine will be more backward from normal canine relation in occlusion.

Class III: Abnormal canine relation, when the lower canine will be more forward than from normal canine relation.

Incisor classification

The incisor relationship does not always match the buccal segment relationship. Since much of orthodontic treatment is focused on the correction of incisor malrelationships, it is helpful to have a classification of incisor relationships. The terms used are the same but this is not Angle's classification, although it is a derivation.

In clinical practice the incisor classification is usually found to be more useful than Angle's classification.



Incisor classification: (a) Class 1: (b) Class II Division 1: (c) Class II Division 2; (d) Class III.

Class I. The lower incisor edges occlude with or lie immediately below the cingulum plateau (middle part of the palatal surface) of the upper central incisors (a).

Class II. The lower incisor edges lie posterior to the cingulum plateau of the upper incisors.

There are two divisions to Class II malocclusion:

Division 1. The upper central incisors are proclined or of average inclination, with an increased overjet (b).

Division 2. The upper central incisors are retroclined (less than 105° to the maxillary plane). The overjet is usually of an average amount but may be increased (c), o.b mostly increased (deep bite)

Class III. The lower incisor edges lie anterior to the cingulum plateau of the upper incisors (d). The overjet may be either reduced or reversed.

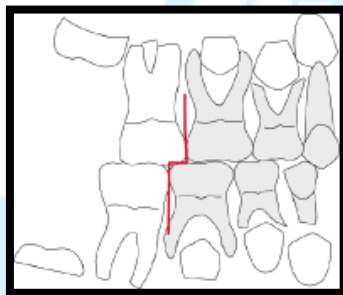
Classification of deciduous teeth: Depend on the relation between terminal plane present in the maxillary and mandibular deciduous posterior teeth.

Terminal plane:

The distal proximal surface of the maxillary and mandibular second deciduous molars (being the distal terminal plane of the deciduous dentition). The relationship between the maxillary and mandibular terminal planes in the early mixed dentition is thought to determine, to a degree, the eventual relationship between the (at the time still unerupted) maxillary and mandibular first permanent molars.

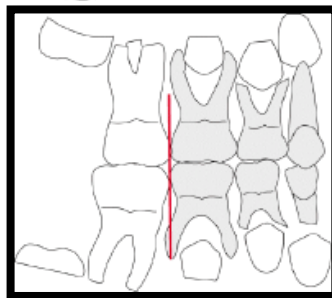
Distal step:

A situation in which the terminal plane of the mandibular second deciduous molar is situated posteriorly to that of the maxillary second deciduous molar. This situation is thought to be predisposing to, but not necessarily predictive of, a Class II relationship of the (at the time, still unerupted) first permanent molars.



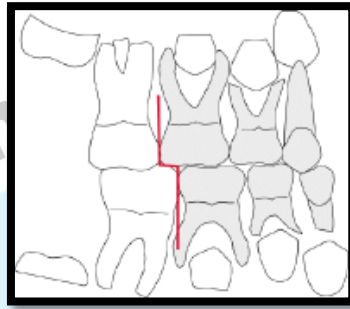
• **Flush terminal plane**

An end-to-end relationship between the distal proximal surfaces of the maxillary and mandibular second deciduous molars, usually leading to a Class I or Class II relationship between the (at the time, still unerupted) maxillary and mandibular first permanent molars.



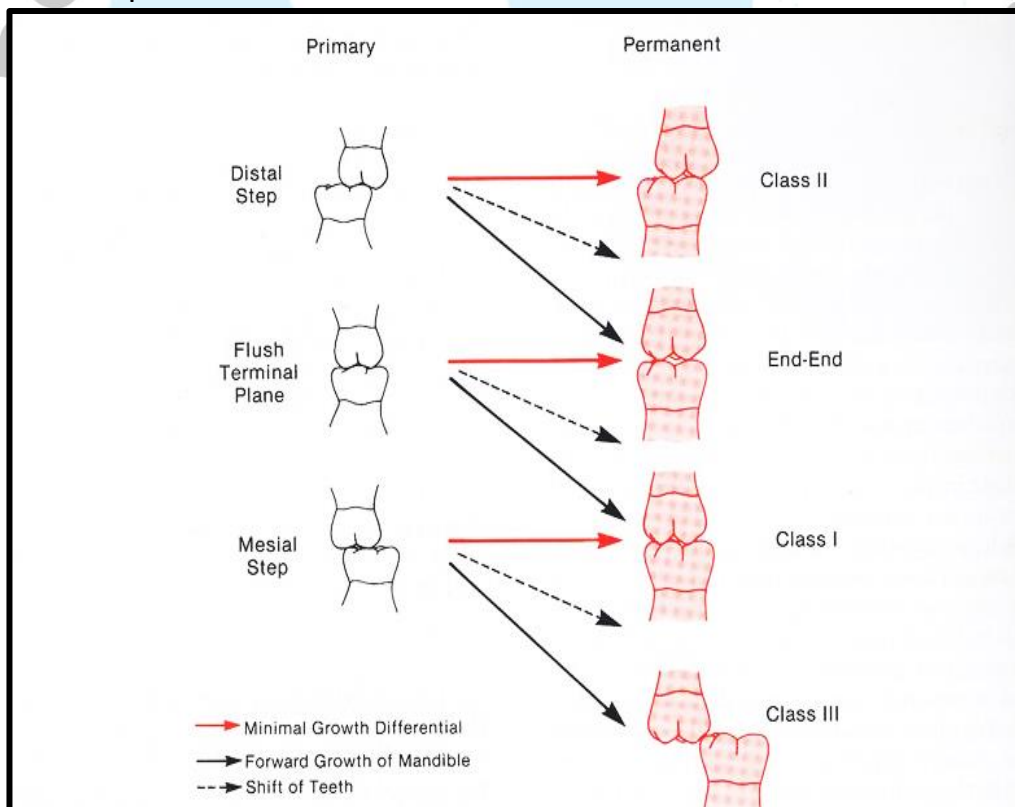
• **Mesial step:**

A situation in which the terminal plane of the mandibular second deciduous molar is situated anteriorly to that of the maxillary second deciduous molar. Depending on the severity of the mesial step, this relationship is thought to predispose to (but is, strictly speaking, not predictive of) either a Class I or a Class III relationship of the (at the time, still unerupted) maxillary and mandibular first permanent molars.



Clinical implications and variations:

The first permanent molars may erupt into one of the following occlusal relationships



Acknowledgement: I would like to thank the Head Department Prof. Dr. Dhiaa J. Nasir Al- Dabagh, for giving me the opportunity of giving and presenting his lectures.