

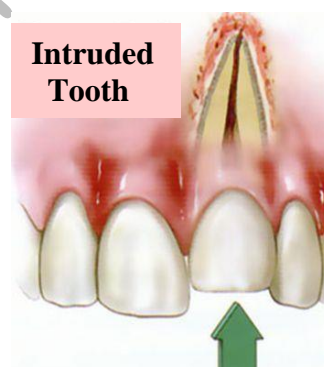
Assist. Prof. Dr. Aseel Haidar

## Displacement of Primary and Permanent Anterior Teeth (LUXATION)

The displacement of anterior primary and permanent teeth presents a challenge in diagnosis and treatment for the dentist.

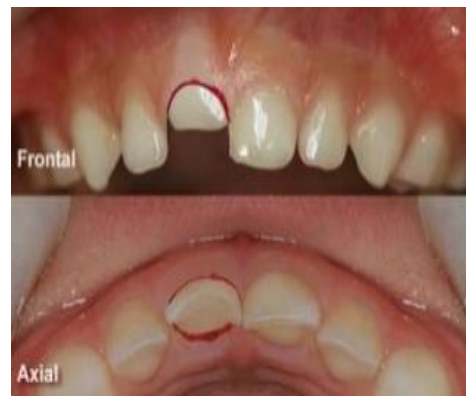### INTRUSION AND EXTRUSION OF TEETH

**INTRUSION:** It is the most severe form of luxation injury because it causes severe damage to the periodontal ligament resulting in a greater incidence of external root resorption. The tooth may be completely or partially intruded into its socket. Clinically crown appears shorter. The best approach is to "wait and watch for the tooth to re-erupt on its own.



### PRIMARY TEETH

Intrusion by forceful impaction of maxillary anterior primary teeth is a common occurrence in children during the first 3 years of life, *why?* Frequent falls and striking of the teeth on hard objects may force the teeth into the alveolar process to the extent that the entire clinical crown becomes buried in bone and soft tissue. Although there is a difference of opinion regarding treatment of injuries of this type, it is generally agreed that immediate attention should be given to soft tissue damage. Intruded primary teeth should be observed; with few exceptions, no attempt should be made to reposition them after the accident. Most injuries of this type occur at an age when it would be difficult to construct a splint or a retaining appliance to stabilize the repositioned teeth.



Normally, the developing permanent incisor tooth buds lie lingual to the roots of the primary central incisors. Therefore when an intrusive displacement occurs, the primary tooth usually remains labial to the developing permanent tooth. If the intruded primary tooth is found to be in a lingual or encroaching relationship to the developing permanent tooth, it should be removed. Such a relationship may be confirmed from a lateral

radiograph of the anterior segment. The examination should be carried out as previously described, and radiographs should be made to detect evidence of root fracture, fracture of the alveolar bone, and damage to permanent teeth. However, predicting whether the permanent successors will show evidence of interrupted growth and development is impossible unless actual encroachment of their space can be seen radiographically.

Primary anterior teeth intruded as a result of a blow may often re-erupt within 3 to 4 weeks after the injury. These teeth may even retain their vitality and later undergo normal resorption and be replaced on schedule by their permanent successors. During the first 6 months after the injury, however, the dentist often observes one or more of the reactions of the pulp and supporting tissues, the most common of which is pulpal necrosis. Even after reeruption, a necrotic pulp can be treated if the tooth is sound in the alveolus and no pathologic root resorption is evident.

Primary teeth that are displaced but not intruded should be repositioned by the dentist or parent as soon as possible after the accident, to prevent interference with occlusion. **The prognosis for severely loosened primary teeth is poor.** Frequently the teeth remain mobile and undergo rapid root resorption.

The immediate and future prognosis for the pulp is more favorable if root formation is still incomplete at the time of the accident. Teeth with complete root formation seemed to undergo resorption more frequently than those with incomplete root formation. However, when resorption did occur, it was more extensive and progressed more rapidly in teeth with incomplete root development.

## **PERMANENT TEETH**

Intruded permanent teeth apparently have a poorer prognosis than similarly injured primary teeth. The tendency for the injury to be followed by rapid root resorption, pulpal necrosis, or ankylosis is greater.

### **The treatment:**

1) For a permanent tooth with a closed root end,

**A)** Intruded less than 3 mm, is to allow the tooth to erupt without intervention. If no movement is evident after 2 to 4 weeks, the tooth may be repositioned either orthodontically or surgically before ankylosis can take place.

**B)** If the tooth is intruded 7 mm or more, the tooth is repositioned surgically and stabilized for 4 to 8 weeks by means of a flexible splint.

In most instances the pulp will become necrotic with intrusive injuries in teeth with complete root formation. Root canal treatment should be initiated, with calcium hydroxide as a temporary canal filling material, 2 to 3 weeks after stabilization.

2) The treatment for an intruded permanent tooth with incomplete root formation is:

**A)** To allow it to erupt spontaneously. If no movement is seen within a few weeks, orthodontic repositioning should begin.

**B)** If the tooth is intruded 7 mm or more, the tooth can be repositioned surgically and stabilized by means of a flexible splint. Endodontic therapy is often required, however, and the tooth should be monitored closely while a decision on endodontic therapy is pending.

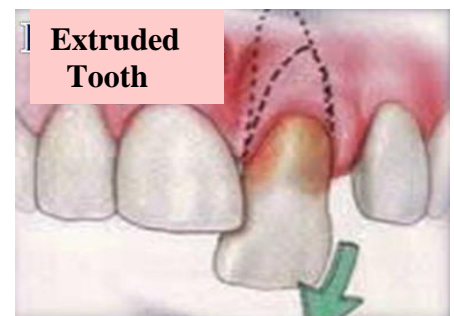
**It appears that spontaneous eruption results in the fewest complications in immature teeth, regardless of the degree of intrusion.**

The frequency of pulpal necrosis in teeth with complete root development is higher than in those with incomplete root development. Teeth with uncomplicated crown fractures with luxation and crown-fractured teeth with intrusion had a higher incidence of pulpal necrosis than any other types of concurrent luxation. **A concurrent luxation injury and complete root development are important risk factors of pulpal necrosis with uncomplicated crown fractures.**

It seems that both treatment approaches to the treatment of severely intruded permanent teeth (early repositioning or waiting for spontaneous re-eruption) have demonstrated reasonably successful results. However, the affected teeth seem to benefit by early calcium hydroxide endodontic therapy with either treatment approach. The decision to reposition mechanically or hope for spontaneous re-eruption of intruded permanent teeth remains a matter of clinical judgment that may be based on several conditions associated with the particular case.

**Extrusion:** It is also called peripheral displacement or partial avulsion. It is partial displacement of tooth out of its socket (**it appear longer**). The extrusive luxation of a permanent tooth usually results in pulpal necrosis. The immediate treatment involves the careful repositioning of the tooth and stabilization.

If mature repositioned teeth do not respond to pulp vitality tests within 2 to 3 weeks after being repositioned, endodontic treatment should be undertaken before there is evidence of root resorption, which often occurs after severe injuries of this type. The need for endodontic intervention is virtually certain in cases of significant extrusion (more than 2 mm) of mature teeth. With extruded immature teeth, the clinician should monitor the situation frequently and be prepared to intervene with endodontic therapy, as described later, if conditions warrant.



**Lateral Luxation:** Displacement of tooth in any direction other than axial.

*Clinical Features*

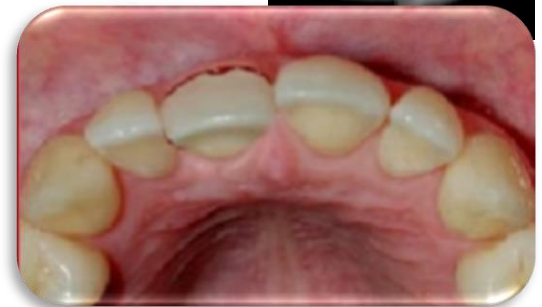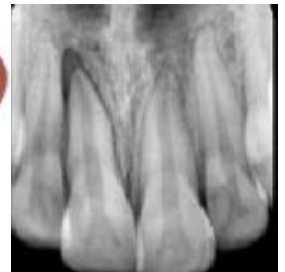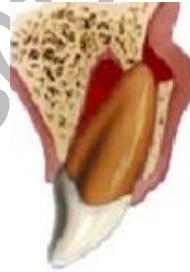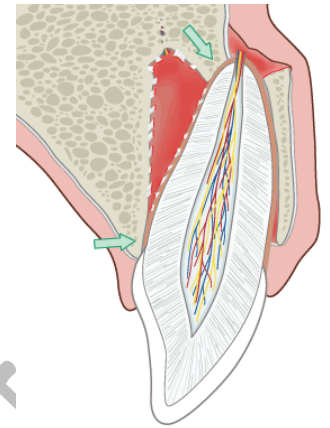
- 1) Tooth is mobile and displaced.
- 2) Bleeding from gingival crevice.
- 3) Tooth is tender to percussion and masticatory forces.

*Radiographic Features*

Widening of PDL space on one side and crushing of lamina dura on other side.

*Treatment*

- 1) Administer local anesthesia if forceful positioning is anticipated.
- 2) Reposition the tooth in normal position using digital pressure.
- 3) Splint the tooth for 2 weeks and if there is a marginal bone breakdown then splint for 6-8 weeks.
- 4) Advice soft diet.
- 5) Follow up period of 1 year.

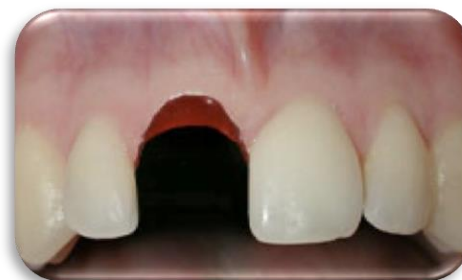
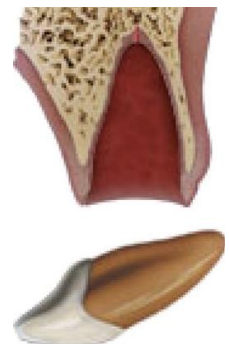
**AVULSION AND REPLANTATION**

Term used to describe complete displacement of tooth from its alveolus. It is also called as exarticulation. Maxillary teeth are most commonly involved.

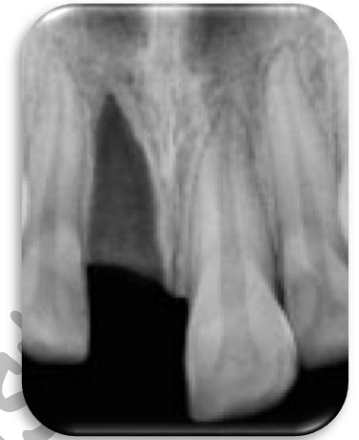*Clinical Features*

Bleeding socket with missing tooth.



**Radiographic Features:**

- 1) Empty socket.
- 2) Associated bone fractures.
- 3) If the wound is recent then lamina dura is visible otherwise it is obliterated.

**Treatment**

1. Replantation.
2. If apical foramen is not closed-endodontic therapy is delayed till first signs of apical closure are seen.
3. If apical foramen is closed -endodontic therapy is done after 1-2 weeks depending on type of reimplantation.

Replantation is the technique in which a tooth, usually one in the anterior region, is reinserted into the alveolus after its loss or displacement by accidental means. Replantation of permanent teeth continues to be practiced and recommended, however, because prolonged retention is also achieved in many cases, especially when replantation occurs soon after the accident.

**Importance of reimplantation:**

- 1) The replanted tooth serves as a space maintainer and often guides adjacent teeth into their proper position in the arch, a function that is important during the transitional dentition period.
- 2) The replantation procedure also has psychological value. It gives the unfortunate child and parents hope for success; even though they are told of the possibility of eventual loss of the tooth, the early result often appears favorable and softens the emotional blow of the accident.

**The success of the replantation procedure depend on:**

- 1) It is undoubtedly related to the length of time that elapses between the loss of the tooth and its replacement in the socket.
- 2) The condition of the tooth and particularly the condition of the periodontal ligament tissue remaining on the root surface are also important factors that influence the success of replantation.

**Notes:**

- ♣ Many reports indicated that immediate replacement of a permanent tooth occasionally results in the maintenance of vitality and indefinite retention. However, replantation should generally be viewed as a temporary measure. Under favorable conditions, many replanted teeth are retained for 5 or 10 years and a few for a lifetime. Others, however, fail soon after replantation.
- ♣ The tooth most commonly avulsed in both the primary and the permanent dentition is a maxillary central incisor. Most often, an avulsion injury involves only a single tooth. \*\*Avulsion injuries are three times more frequent in boys than in girls and occur most commonly in children from 7 to 9 years of age, when permanent incisors are erupting. \*\*Loosely structured periodontal ligament surrounding the erupting teeth favors complete avulsion.
- ♣ The sooner a tooth can be replanted in its socket after avulsion, the better the prognosis will be for retention without root resorption. The prognosis is therefore more favorable. Also, if the apical end of the tooth is incompletely developed at the time of the injury, there is a greater chance of regaining pulp vitality after replantation. If the apex is closed, the dentist should proceed with a pulpectomy a few days after the replantation, even if the extraoral time for the tooth was brief.


If a parent calls to report that a tooth has been avulsed, and it can be determined that the injury is without other oral, neurologic, or higher-priority physical complications, the dentist may instruct the parent to do the following (**primary teeth should not be replanted**):

1. Keep the patient calm.
2. Find the tooth and pick it up by the crown (the white part). Avoid touching the root.
3. If the tooth is dirty, wash it briefly (10 seconds) under cold running water and reposition it. Try to encourage the patient/parent to replant the tooth. Bite on a handkerchief to hold the tooth in position.
4. If repositioning is not possible, place the tooth in a suitable storage medium.
5. Seek emergency dental treatment immediately, unless the patient was knocked unconscious. If the child was unconscious for a period of time, first seek emergency medical evaluation for a concussion.

**Notes:**

- ♣ Hank's balanced salt solution (HBSS): Considered as best transport medium.

- ♣ Milk: Excellent medium, has a favorable pH and osmolality. Few virulent microorganisms owing to Pasteurization. Maintains vitality of periodontal cells for about 3hours'
- ♣ Saliva: Allows storage for 2 hours but it is hypotonic.
- ♣ Saline: Has physiologic pH and is isotonic
- ♣ Tap water: Considered as bad as dry storage, its hypotonicity causes cell lysis. It should be used only if any of the above is not readily available



If the parent cannot or will not replant it, the tooth must be kept moist during the trip to the dental office. Allowing the avulsed tooth to dehydrate before replantation is damaging to a favorable prognosis. Hanks' buffered saline, isotonic saline, and pasteurized bovine milk may be the most favorable known storage media. Although tap water has been a commonly recommended storage solution (and its use would be preferable to dehydration of the tooth), it is hypotonic, and its use leads to rapid cell lysis and increased inflammation on replantation. The patient should receive immediate attention after arriving at the dental office. If the tooth has not already been replanted, the dentist should make every effort to minimize the additional time that the tooth is out of the socket.

The patient's general status should be quickly assessed to confirm that there are no higher-priority injuries. If an evaluation of the socket area shows no evidence of alveolar fracture or severe soft-tissue injury, the tooth is intact, and only a few minutes have elapsed since the injury, the dentist should replant the tooth immediately.

Under the conditions just described, every effort should be directed toward preserving a viable periodontal ligament. That treatment should be directed at avoiding or minimizing the resultant inflammation that occurs as a direct result of the two main consequences of tooth avulsion attachment damage and pulpal infection.

If the tooth was cleanly avulsed, it can probably be replanted without local anesthetic, and obtaining the initial radiograph can also be delayed until the tooth is replaced in the socket and held with finger pressure. The minutes saved may contribute to a more successful replantation. If a clot is present in the socket, it will be displaced as the tooth is repositioned; the socket walls should not be scraped with an instrument. If the tooth does not slip back into position with relative ease when finger pressure is used, local anesthesia and a radiographic evaluation are indicated. Local anesthetic should also be administered when fractured and displaced alveolar bone must be repositioned before the tooth is replanted. Soft-tissue suturing may be delayed until the tooth has been replaced in

the socket; however, the suturing should be performed to control hemorrhage before the tooth is stabilized with a bonded splint. The root canals were hermetically sealed with gutta-percha, and the teeth were splinted for 1 month. Subsequent microscopic examination under fluorescent and incandescent light revealed deposition of secondary cementum and new alveolar bone, which entrapped the periodontal fibers.

The preservation of an intact and viable periodontal ligament is the most important factor in achieving healing without root resorption. Delicate handling of the tooth, storage in an appropriate moist environment, quick replantation, and appropriate stabilization are all important in preserving the periodontal ligament. Undesirable periodontal ligament reactions may result in replacement resorption (ankylosis) or inflammatory resorption of the root. Either reaction may cause eventual loss of the tooth unless the resorption can be controlled. Use of an enamel matrix derivative (Emdogain) has been shown to increase the incidence of healed periodontal ligament when this gel is applied to the root surface of the avulsed tooth and/or inserted directly into the alveolar socket before implantation. It appears to aid in preventing or retarding resorption and ankylosis.

### *Stabilization of Replanted Teeth*

After replantation of a tooth that has been avulsed, a splint is required to stabilize it during at least the first week of healing. Acceptable splint should meet the following criteria:

1. It should be easy to fabricate directly in the mouth, without lengthy laboratory procedures.
2. It should be able to be placed passively without causing forces on the teeth.
3. It should not touch the gingival tissues, causing gingival irritation.
4. It should not interfere with normal occlusion.
5. It should be easily cleaned and allow for proper oral hygiene.
6. It should not traumatize the teeth or gingiva during application.
7. It should allow an approach for endodontic therapy.
8. It should be easy to remove.

The splint should also allow mobility of the replanted tooth that is comparable with the normal mobility of a tooth. Rigid stabilization seems to stimulate replacement resorption of the root. Rigid stabilization of a replanted tooth is detrimental to proper healing of the periodontal ligament. The bonded resin and wire splint satisfies all the criteria just described. It can be used in most situations requiring the stabilization of one or more teeth if sufficient sound teeth remain for anchorage. Rectangular or round orthodontic wire is bent to approximate the arch configuration along the midportion of the



labial surfaces of the teeth to be incorporated into the splint. At least one sound tooth on each side of the tooth to be stabilized is included. The size of the wire is not too critical, but rectangular wire should be at least  $0.016 \times 0.022$  inch and round wire at least 0.018 inch. If three or four teeth must be stabilized, a stiffer wire (e.g., 0.028-inch round wire) is required. If round wire is used, a right-angle bend should be made near each end of the wire to prevent rotation of the wire in the resin. A 20- to 30-pound-test monofilament nylon line is an acceptable substitute for wire in the splint. If the labial enamel surfaces to be etched are not plaque free, they should be cleaned with a pumice slurry, rinsed, thoroughly dried, and isolated with cotton rolls. The enamel surfaces are etched with a phosphoric acid etchant; the gel form is convenient. The enamel surfaces are thoroughly washed and dried again. The wire is then attached to the abutment teeth by the placement of increments of the resin material over the wire and onto the etched enamel. The resin should completely surround a segment of the wire, but it should not encroach on the proximal contacts or embrasures. The replanted tooth is then held in position while resin is used to bond it to the wire. The resin may be lightly finished if necessary after polymerization. The splint is easily removed (usually 7 to 10 days later) by cutting through the resin with a bur to uncover the wire. The remaining resin may then be removed with conventional finishing instruments. If the splint is used to stabilize lower teeth, it may be necessary to affix the wire to the lingual surfaces if placing it on the labial surfaces will interfere with natural occlusion. Because lingual surfaces are more likely to be contaminated with saliva during the procedure, however, labial placement is preferred whenever possible. Direct-bonded orthodontic brackets may also be placed on the teeth, and a light labial archwire bent to conform accurately to the natural curvature of the arch is then ligated to the brackets. The brackets are properly aligned on the archwire and bonded to the abutment teeth first. The avulsed tooth is then ideally positioned, and additional bonding material is placed, if necessary, to fill any remaining small space between the tooth and the bracket before being bonded to the splint. If performed properly, this technique results in an excellent splint. However, it requires much more accurate and precise wire bending than the bonded resin and wire technique (without brackets) to achieve a passive appliance.

If the patient has mental disabilities or immature behavior and does not tolerate foreign objects in the mouth well, or if there are insufficient abutment teeth available for the bonded resin and wire splint, the suture and bonded resin splint advocated that may be an acceptable alternative. The titanium trauma splint has been developed to ease the application and removal of the splint and to increase comfort for the patient.

In general, stabilization for replanted teeth without other complications is required for 7 to 14 days. The periodontal ligament fibers should have healed sufficiently after the first week to allow the splint to be removed. However, the patient should be advised not to bite directly on the replanted tooth for 3 to 4 weeks after the injury and then gradually to begin to return to normal use of the tooth. During this time, food may be cut

into bite-size pieces and chewed carefully with unaffected teeth. The patient should maintain good oral hygiene by brushing and flossing normally and using chlorhexidine mouth rinses. Systemic antibiotic therapy is recommended to begin immediately and continue for at least a week following replantation. If the apex is closed, extending the antibiotic therapy until the pulp is extirpated seems to be a good way to determine the duration of antibiotic coverage.

Antibiotic therapy is effective in preventing the development of external inflammatory root resorption of replanted teeth in which the pulps were not extirpated. This finding suggests that antibiotic therapy may also be helpful in those cases in which the pulps of immature replanted teeth are allowed to remain while revitalization remains a possibility. Additional studies in this area are indicated.

The recommendations for replanting a tooth based on its status as judged by the clinician's determination of the physiologic condition of the root periodontal ligament cells, the development of the root apex, and the length of extraoral time. The dentist should confirm at the time of replantation that the patient is adequately immunized against tetanus.

## *Endodontic Management of Replanted Teeth*

All replanted permanent teeth with **complete apical root** development should undergo a **pulpectomy** soon after **replantation regardless of the length of time the tooth was out of the mouth**. Even though a few reports of revitalization exist, the chances for revitalization are remote at best. Moreover, adverse reactions are virtually certain if degenerating pulp tissue is allowed to remain in the canals for more than a few days. The risk-benefit ratio for the patient favors pulpal extirpation. Because replantation should be done as soon as possible after the injury, the dentist should not take time to extirpate the pulp before replantation. The pulp should be extirpated before the splint is removed, however, and preferably within 1 week after the injury. A sterile, dry cotton pellet or one dampened with CMCP and blotted on sterile gauze may be sealed in the pulp chamber after debridement and irrigation. The canal should be filled approximately 2 weeks after the injury. When the canal is filled, calcium hydroxide paste is the material of choice.

### *Notes:*

1) There was a study suggested that the pulp contents be removed at the emergency visit and a tetracycline-corticosteroid combination (Ledermix) be placed in the root canal.

2) This combination decreases the inflammatory response after replantation to allow for more favorable healing than in those teeth that do not receive the medicament.

3) Root canal treatment should be initiated 7 to 10 days after replantation.

4) Early extirpation of the pulp may help to control the early onset of inflammatory root resorption.

5) Filling the root canal with calcium hydroxide also controls and may even arrest external inflammatory root resorption. If the calcium hydroxide is placed in the canal too soon (before adequate healing of the periodontal ligament), however, it may stimulate replacement root resorption.

6) 2 weeks after replantation is the ideal time to fill the canal with calcium hydroxide.

If the avulsed permanent tooth has immature root formation with an open apex, the chances of pulpal revitalization after replantation improve considerably, especially if replantation occurs within 30 minutes after avulsion. If the avulsed tooth has been cared for properly, there is a small chance for revitalization even if the tooth is replanted within 1 hour after the injury. However, many teeth do not revitalize. Those that do respond favorably may still require root canal treatment several months later. During the time beyond 1 week that the pulp tissue is allowed to remain, evaluation of the tooth is recommended at weekly intervals until favorable signs of healing without pulpal pathosis are conclusive (vitality tests are unreliable) or until a decision is made to extirpate the pulp. The pulp should be extirpated when the first signs of degeneration appear. Rubber dam isolation is always desirable when pulp therapy is performed. It can usually be used even during the pulp extirpation procedure, while several teeth are splinted together. Instead of separate holes in the rubber dam for each tooth, a slit is made so that the rubber can be placed over all teeth in the splinted segment. This does not afford ideal isolation, but it is generally better than the use of cotton rolls. In addition, the rubber dam helps prevent the swallowing or aspiration of foreign objects during treatment. If small endodontic instruments are used without rubber dam protection, they should be secured with a length of dental floss to facilitate retrieval in the unlikely event that they are dropped in the patient's mouth.

The calcium hydroxide material used to fill the root canal should be replaced every 3 to 6 months until a decision is made to fill the canal with gutta-percha. The optimum duration of the calcium hydroxide treatment is unknown, but generally calcium hydroxide should be kept in the canal for at least 6 months or until root end closure (apical plug) occurs beyond 1 year. In cases in which an adjacent tooth is still unerupted, calcium hydroxide treatment is recommended until eruption of the adjacent tooth. It is

believed that eruption may stimulate or accelerate the resorptive process in a nearby replanted root.

