

Assist. Prof. Dr. Aseel Haidar

Reaction of the Tooth to Trauma

1) Pulpal Hyperemia

It may be occurred even with minor trauma. Congestion of blood within the pulp chamber a short time after the injury can often be detected in the clinical examination and that is by directing a strong light to the labial surface of the injured tooth and the lingual surface is viewed in a mirror, the coronal portion of the tooth will often appear reddish compared with the adjacent teeth. The color change may be evident for several weeks after the accident and often indicates a poor prognosis. **Since collateral circulation is absent in the pulp, hyperemic conditions may lead to infarction and pulpal necrosis. The tooth appears reddish and is often indicative of a poor prognosis.**

2) Internal hemorrhage

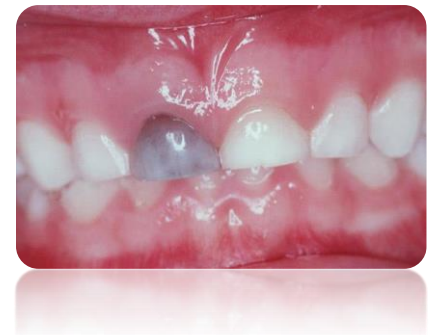Hyperemia and increased pressure may cause rupture of capillaries and the escape of RBC with subsequent breakdown and pigment formation. These may be reabsorbed before gaining access to dentinal tubules if bleeding is minute (in which case little if any color change will be noticeable and what does appear will be temporary). In severe cases there is deposition of these pigments in the dentinal tubules. The change in color is evident within 2-3 weeks after injury and though is reversible, the crown may retain some amount of discoloration for an indefinite period. In cases of this type, there is some chance that the pulp will retain its vitality, although the likelihood of vitality is apparently low in primary teeth with dark-gray discoloration.



Note:

**Gray-black discoloration → necrotic pulp, so that dark-gray coronal discoloration as the primary diagnostic sign before pulpectomy.

**Discoloration that becomes evident for the first time months or years after an accident, however, is evidence of a necrotic pulp.



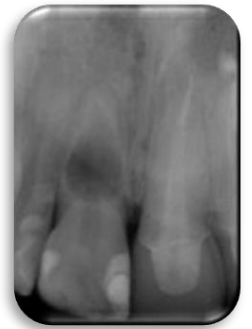3) Calcific metamorphosis of dental pulp

(Progressive Canal Calcification or Dystrophic Calcification)

There may be partial or complete obliteration of the pulp chamber or canal and although the radiograph may give the illusion of complete obliteration, an extremely fine root canal and remnants of the pulp will persist. The crowns of teeth that have undergone this reaction may have a yellowish, opaque color. Primary teeth demonstrating calcific metamorphosis will usually undergo normal root resorption. While the permanent tooth that showing signs of calcific changes as a result of trauma should be regarded as a potential focus of infection and must be kept under observation or treated endodontically if possible. A small percentage of such teeth demonstrate pathologic change many years after the injury.

4. Internal resorption

It is a destructive process generally believed to be caused by odontoclastic action. Appears as a pink tooth. It is observed radiographically in the pulp chamber or canal within a few weeks or months after injury. The destructive process may progress slowly or rapidly. If the progression is rapid it may cause perforation of the crown or roots within a few weeks. Such teeth should be treated endodontically as soon as diagnosed.

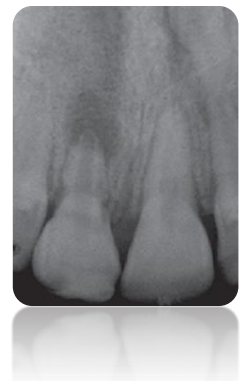

This condition can be described as “pink spot” because when the crown is affected, the vascular tissue of the pulp shines through the remaining thin shell of the tooth. The occurrence referred of a perforation as “perforating hyperplasia of the pulp.” If evidence of internal resorption is detected early, before it becomes extensive with resulting perforation, the tooth may possibly be retained when endodontic procedures are instituted.

5. Peripheral (External) root resorption

It usually results due to the damage to the periodontal structures and the pulp may not be involved. This condition can be seen in severe trauma in which there has been some degree of displacement of the tooth.

This reaction starts from without, and the pulp may not become involved. Usually the resorption continues unabated until gross areas of the root have been destroyed. In exceptional cases the resorption may become arrested, and the tooth may be retained.



6. Pulpal necrosis

Little relationship exists between the type of injury to the tooth and the reaction of the pulp and supporting tissues. Any type of injury especially the displacement type may cause severance of the apical vessels. This lead to loss of vascular supply to the pulp leading to autolysis and necrosis. Injured teeth with subsequent pulpal necrosis are commonly asymptomatic and the radiograph is essentially normal. The acute symptoms and clinical evidence of infection will inevitably develop at a later date. Bacteriological status of the pulp tissue of root canal of intact but traumatized teeth reveals microorganisms, including anaerobic forms in the pulp canal of traumatized teeth. The source of microorganisms is through gingival sulcus or blood stream or both.

In a less severe type of injury, the hyperemia and slowing of blood flow through the pulpal tissue may cause eventual necrosis of the pulp. In some cases the necrosis may not occur until several months after the injury. The tooth with a necrotic pulp should therefore be extracted or treated with endodontic procedures, whichever is indicated.

A tooth receiving an injury that causes coronal fracture may have a better pulpal prognosis than a tooth that sustains a severe blow without fracturing the crown. Part of the energy of the blow dissipates as the crown fractures, rather than all of the energy's being absorbed by the tooth's supporting tissues. Thus the periodontium and the pulp of the injured tooth sustain fewer traumas when the crown fractures. The prognosis for long-term retention of the tooth and for maintenance of pulp vitality may then improve. However, because some teeth do not recover from traumatic blows that seem relatively minor, all injured teeth should be closely monitored.

A necrotic pulp in an anterior primary tooth may be successfully treated if no extensive root resorption or bone loss has occurred. The treatment technique is essentially the same as that for permanent teeth. However, trauma to the periapical tissues during canal instrumentation must be carefully avoided.



Note:

Risk of pulp necrosis (from the lowest)

Concussion, Subluxation, Extrusion, Lateral luxation, Intrusive luxation –
100% chances of pulp necrosis and external root resorption

7. Ankylosis

It is caused by injury to the periodontal membrane and subsequent inflammation which is associated with invasion by osteoclastic cells resulting in irregularly resorbed areas on the peripheral root surface. In histologic sections, repair

can be seen that may cause a mechanical lock or fusion between alveolar bone and the root surface. Radiograph shows an interruption in the periodontal membrane of the ankylosed tooth and often the dentin may appear to be continuous with alveolar bone and clinically appears submerged (Clinical evidence of ankylosis is seen as a difference in the incisal plane of the ankylosed tooth and adjacent teeth. The adjacent teeth continue to erupt, whereas the ankylosed tooth remains fixed in relation to surrounding structures).

So: Ankylosed anterior primary tooth must be removed to allow eruption of the permanent tooth (The ankylosed anterior primary tooth should be removed if there is evidence of its causing delayed or ectopic eruption of the permanent successor).

If **ankylosis of a permanent** tooth occurs during active eruption, eventually a discrepancy between the position of this tooth and its adjacent ones will be obvious. The uninjured teeth will continue to erupt and may drift mesially, with a loss of arch length. **Therefore either surgical repositioning or the removal of a permanent tooth** that becomes ankylosed is often necessary, especially if the ankylosis occurs during the preteen or early teen years.

Restoration of Fractured Teeth

To aid in the recovery of the pulp after the trauma, the restoration of a fractured tooth is as important as the emergency treatment designed. Several restorations have been advocated, and although the dentist has a wide choice of techniques and types of restorations, the following factors may affect the type of the restoration:

- 1) The circumstances surrounding the case often dictate the type of restoration for a given patient.
- 2) The prognosis of pulp healing,
- 3) The amount of tooth structure remaining,
- 4) The stage of eruption of the tooth and adjacent teeth,
- 5) The size of the dental pulp and degree of root closure,
- 6) The normalcy of the occlusion,
- 7) The wishes of the patient

All of these factors must be considered in the selection of a temporary restoration, an intermediate restoration, or the permanent restoration. In the young patient, although it is often desirable to wait for continued eruption of the tooth or to determine the outcome of a vital pulp procedure, a delay of even a few weeks is often sufficient to allow the tipping of adjacent teeth, overeruption of opposing teeth, or other undesirable changes in the occlusion.

Notes:

- ♣ Permanent filling in young children should not be done from the beginning, because:
 - 1) The dentinal tubules are widely open. So any cut in the crown or cementation for the crown might affect the pulp because it produces irritation to the pulp.
 - 2) The full length of the clinical crown is not yet established.
 - 3) The pulp chamber of newly erupted tooth is wide and any cutting might get pulp exposure.
 - 4) The root of the tooth continue to develop 3-4 years after eruption.

- ♣ Treatment of traumatized teeth usually divided into 3 stages:
 - 1) Emergency treatment
 - 2) Intermediate or semi-permanent treatment
 - 3) Permanent treatment

- ♣ Types of semi-permanent restorations:
 - 1) Colloid crown
 - 2) Chrom steel crown with window labeling
 - 3) Pin with filling material
 - 4) Cold cure acrylic temporary crown (good esthetic, keep it 4-6 weeks in the month)

- ♣ In case of Class III fracture where fracture line below the level of root, try to extend the root orthodontically and do R.C and make post and core.

Reaction of Permanent Tooth Buds to Injury

The dentist who provides emergency care for a child after an injury to the anterior primary teeth must be aware of the possibility of damage to the underlying developing permanent teeth. The close anatomic relationship between the apices of primary teeth and their developing permanent successors explains why injuries to primary teeth may involve the permanent dentition. The dentist and the physician should also be aware of the possibility of trauma to permanent tooth buds from other unusual injuries so that parents may be informed of the possibility of defective permanent tooth development. Some injuries to the face and jaws may not appear to

have caused any dental injuries initially, but the problem may be noticed several months or years later. The reaction could be hypocalcification, reparative dentine or dilacerations.

1) Hypocalcification and Hypoplasia

Gross malformed crown, small pigmented hypoplastic areas referred as (Turner tooth). Small hypoplastic defects may be restored by the resin-bonding technique.



Note:

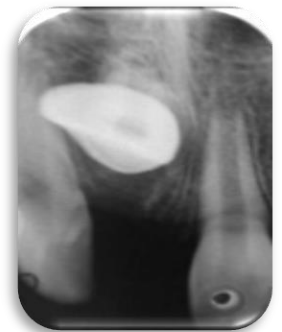A disturbance in enamel matrix formation produces enamel hypoplasia which is characterized by irregular thickness of enamel and presence of pits and grove in the enamel surface. Any defect in mineralization process the enamel thickness is normal but poorly mineralized. It can be found in both primary and permanent dentition.

2) Reparative Dentine Production

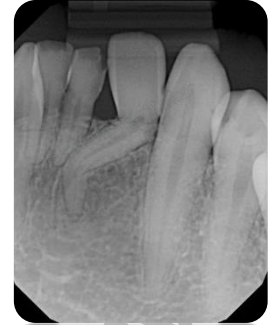
This condition may occur in cases in which the injury to the developing permanent tooth is severe enough to remove the thin covering of developing enamel or cause destruction of the ameloblasts, the subjacent odontoblasts have been observed to produce a reparative type of dentin. The irregular dentin bridges the gap where there is no enamel covering to aid in protecting the pulp from further injury.

3) Dilaceration

Tooth with sharp bend in crown or root is known as dilacerated tooth. Dilacerations is most commonly seen in maxillary permanent central incisors. Most common cause of dilacerations is trauma to the deciduous teeth (Occasionally occurs after the intrusion or displacement of an anterior primary tooth. The developed portion of the tooth is twisted or bent on itself, and in this new position growth of the tooth progresses. Germination may appear in the part of the tooth formed after the injury). Dilacerated tooth usually fails to erupt but may sometimes erupt into an abnormal position and can cause displacement of adjacent teeth.



**Crown of a permanent tooth or a portion of it develops at an acute angle to the remainder of the tooth →



Treatment

1. Unerupted dilacerated tooth usually require surgical extraction.
2. Erupted teeth with root dilacerations should be extracted, if they are in abnormal position. Since, it is difficult to move by orthodontic force.
3. Following extraction, extracted space should be maintained by prosthesis or closed by orthodontic treatment.

Baghdad College of Dentistry