

## IMMEDIATE DENTURE

### Introduction:

There are different treatment options for a patient facing loss his or her remaining natural teeth, immediate denture is one of these options that fulfill an important role in today's treatment modalities by providing the patients with esthetics, function, and psychological support after extractions and during the healing phase.

### Definition:

An immediate denture is "any complete or partial removable dental prosthesis fabricated for placement immediately following the removal of natural teeth".

It may be either single immediate dentures or upper and lower immediate dentures in the same patient. The latter should be made together to ensure optimal esthetics and occlusal relationships.

### Indications:

1. **Educated patient** with daily social activity (doctors, lawyers and teachers).
2. **Hopeless remaining teeth** (caries, periodontal diseases or malocclusion)
3. patient with **stable health condition.**
4. Patient don't mind **some additional visits or cost.**

The best patient for immediate dentures is the philosophical type. Their motivation for denture is the maintenance of health and appearance, and they accept replacement of natural teeth that can't be saved as normal procedure.

### Contraindications:

1. Patients who are in **poor general health** (systemic diseases).
2. Patients who are identified as **uncooperative, indifferent** and **unappreciative**.
3. Patient at risk from **bacteremia**.
4. Patient with recurrent history of **post extraction hemorrhage**.
5. The presence of **acute periapical** or **periodontal** diseases and extensive **bone loss**.
6. Patient don't **mind being edentulous** for a period of time till complete healing.

### Advantages:

1. **Maintenance** of a patient's **appearance** because there is no edentulous period.
2. Circumoral support, muscle tone, vertical dimension of occlusion, jaw relationship, and face height can be maintained. The tongue will not spread out as a result of tooth loss.
3. Less postoperative **pain** is likely to be encountered because the extraction sites are protected. Some authors have discussed whether immediate dentures reduce residual ridge resorption.
4. It is **easier to duplicate** (if desired) the natural tooth shape and position, plus arch form and width.
5. The patient is likely to **adapt** more easily to dentures at the same time that recovery from surgery is progressing. Speech and mastication are rarely compromised, and nutrition can be maintained.
6. Overall, the **patient's psychological** and **social well-being** is preserved. The most compelling reasons for the immediate denture prescription are that a patient does not have to go without teeth and that there is no interruption of a normal lifestyle of smiling, talking, eating, and socializing.

## **Disadvantages:**

Immediate dentures are a more challenging modality than complete dentures because the presence of teeth makes impressions and maxillomandibular positions more difficult to record.

Specific disadvantages include the following:

- 1.** The anterior ridge undercut (often severe) that is caused by the presence of the remaining teeth may interfere with the impression procedures and therefore preclude also accurately capturing a posteriorly located undercut, which is important for retention.
- 2.** The presence of different numbers of remaining teeth in various locations (anteriorly, posteriorly, or both) frequently leads to recording incorrectly the centric relation position or planning improperly the appropriate vertical dimension of occlusion. An occlusal adjustment, or even selective pre-treatment extractions, may be needed to make accurate records at the proper vertical dimension of occlusion.
- 3.** The inability to accomplish a denture tooth try-in in advance on extractions precludes knowing what the denture will actually look like on the day of insertion
- 4.** Because this is a more difficult and demanding procedure, more chair time, additional appointments, and therefore increased costs are unavoidable.
- 5.** Functional activities such as speech and mastication are likely to be impaired however this is a temporary inconvenience.

## **Types of immediate dentures:**

According to the case and type of treatment plan, immediate denture may planned to be:

### 1. Conventional (or classic) immediate denture (CID):

After this immediate denture is placed and after healing is completed, the denture is refitted or relined to serve as the long-term prosthesis.

### 2. Interim (or transitional or non-traditional) immediate denture (IID):

After this immediate denture is made and after healing is completed, a second, new complete denture is fabricated as the long-term prosthesis. The interim prosthesis designed to enhance esthetics, stabilization and/or function for a limited period of time, after which it is replaced by a definitive prosthesis. It is temporary treatment, must be followed by the definite treatment.

<b>CID</b>	<b>IID</b>
<b>Definitive</b>	<b>Transitional</b>
Intended as the final or long term prosthesis	Intended for short term use only
After healing, it is relined with acrylic resin	After healing, a second denture is made
Indicated when two extraction visits are feasible	Indicated when only one surgical visit is preferable to maximize insurance benefits
The esthetics of the denture cannot be changed	The second denture procedure allows an alteration of esthetics, and all other factors, if indicated
At the end of treatment, the patient has one denture	At the end of treatment, the patient has a spare denture to use in case of extenuating circumstances
If all posterior teeth are initially removed, vertical dimension of occlusion is not preserved. (however, opposing bicuspid can be maintained)	Since posterior teeth need not be removed, vertical dimension of occlusion may be preserved

Contraindication for patients who will need complicated treatment plans involving both arches, such as periodontal therapy, crowns and fixed ,partial dentures and dentures opposing removable partial dentures	Often indicated when the patient will become edentulous in one arch and partially edentulous in the opposing arch for the first time. An interim complete denture can be made. Then any periodontal procedures, crowns and fixed ,partial dentures, can then be done during the initial healing stage
---	---

### Immediate denture can be classified according to type of restoration into:

1. Immediate complete denture.
2. Immediate partial denture.
3. Immediate over denture.

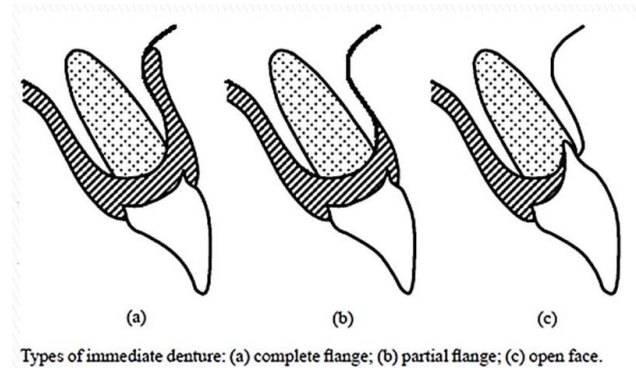
However immediate denture are probably better described by the more appropriate term of transitional dentures. This term is more appropriate because the day that the last teeth are removed and the dentures placed is the beginning or transition from natural teeth to denture teeth.

The transitional denture has three or **four phases.**" The **first phase** is preparatory extractions of all posterior teeth in the arch to receive the denture. All molars and bicuspid are removed and the bone and overlying gums are allowed to heal. Sometimes Upper and lower first bicuspid are left to keep the bite dimension from changing as well as provide a broader smile during healing. The healing period varies but is usually six to eight weeks. Some patients will have transitional removable partial dentures made to replace the back teeth. , These partial dentures are used only during the healing of the posterior areas phase. They can be placed the same day the back teeth are removed and will require some adjustments for fit and function during healing. Use of transitional removable partial dentures is not always possible so each case must be determined on an individual basis.

### According to flange design:

#### 1. flanged type .

- A. complete flange.
- B. partial flange.



#### 2. Open-faced flangeless type (open face or close fit).

### Comparisons of flanged and open faced denture:

1. Appearance of flanged denture does not altered after fitting where the appearance of open – face denture (although good initially) can deteriorate rapidly as resorption create a gap between the necks of the teeth and ridge.
2. The flanged denture allows freedom in the positioning of teeth ,where, in open face denture teeth have to be positioned in the sockets of the natural teeth

So on case of malpositioned teeth we can do good alignment in flanged denture while we cannot in open face type.

#### 3. in upper denture:

A flange on an upper denture create a more effective borders seal, therefore, better retention than is achieved with an open face denture.

#### 4. in lower denture:

Open face denture is not usually constructed because of poor stability of lower denture during function, so flange denture is commonly used. So flange denture is better from the point of stability.

5. The presence of labial flange produces a stronger denture, labial flange will make the denture stiffer so the midline fatigue fracture caused by

repeated flexing across the midline is reduced. so from the point of strength the flange denture is better.

6. As the bone resorbed following extraction the denture become loose and a reline is required, so the presence of labial flange make it easier to add either a short-term soft lining materials or a cold curing relining materials as a chair side procedure, as the color of some reline materials is not always ideal they may be visible when used with open face denture.
7. The flange denture cover the clot completely and protect them more effectively, the flange denture exerts pressure on both lingual and labial gingiva reducing post extraction hemorrhage.
8. The consequence wearing of ill-fitting denture can lead to:
  - a. If it is open face, will produce a scalloped ridge in the region of the socketed teeth
  - b. In flange denture, distribution the functional loads more favorably to the underlying ridge, thus minimizing bone resorption.
9. When patient have got used to an open face immediate denture there is difficulty to accept a denture with labial flange in future and patient will complain from the fullness of the lip .  
If flange denture had worn from the beginning this problem does not occur.
10. When the ridge morphology produce deeply undercut area it may not be possible to fit a full labial flange unless there is surgical reduction, In this case the using of partially flange denture or open face denture is preferable when surgical procedure is contraindication.

### **Explanation to the Patient Concerning Immediate Dentures:**

1. They do not fit as well as complete dentures. They may need temporary linings with tissue conditioners and may require the use of denture adhesives.

2. They will cause discomfort. The pain of the extractions, in addition to the sore spots caused by the immediate denture, will make the first week or two after insertion difficult.
3. The esthetics may be unpredictable. Without an anterior try-in, the appearance of the immediate denture may be different from what you expected.
4. Many other denture factors are unpredictable such as the gagging tendency, increased salivation, different chewing sounds, and facial contour.
5. Immediate dentures must be worn for the first 24 hours without being removed by the patient. If they are removed, they may not be able to be reinserted for 3 to 4 days. The dentist will remove them at the 24-hour visit.
6. Because supporting tissue changes are unpredictable, immediate dentures may loosen up during the first 1-2 years, or 4-6 months depending on the no. of teeth and their location.

### **Diagnostic steps:**

- Good oral hygiene is essential before starting any prosthodontic treatment.
- Patient's systemic condition, it is very important to check the general health of the patient because multiple extraction may not be tolerated by all the patients, that's why patients with uncontrolled systemic diseases should not be included in this type of treatment. Patients under medical control and do not interfere with the steps of denture construction including several teeth extraction with or without some surgical corrections can be included, medical consultation is advisable.
- Full dental history must be recorded in the case sheet.



- Periodontal condition of the remaining teeth must be assessed, this must include teeth mobility, measurement of the pockets; because this might affect surgical step of the treatment course. Severe case of periodontal disease may suggest some surgical correction after extraction to have well contoured residual ridge covered with firmly attached mucosal tissue. Periodontal condition may give a primitive assessment about the bone remodeling subsequent to the surgical phase.
- Full teeth charting, teeth may help in retention as a partial denture or overdenture abutments must be determined, any soft or hard tissue correction as frenal release or bone reduction must be included after good evaluation.
- **Radiographic examination**  
Which is essential for immediate denture patients. Periapical radiograph may be useful for localized area; OPG view give general view for both jaws in single image.
- Teeth mold and shade must be recorded, proper communication with the patient about his teeth shade and form is essential, furthermore teeth alignment and any individual variations as diastema, spacing, rotation of the teeth if the patient like to preserve same appearance or improvement could be suggested by dentist for better appearance. BUT it is very important to remove any premature contacts because these may interfere with correct jaw relation record, essential changes to improve occlusal plane, midline, overjet and overbite and any other corrections that help in esthetic and functional requirements.
- **Occlusal plane adjustment**  
is necessary because the factors that necessitate tooth extraction are often associated with occlusal discrepancies. These also interfere with centric relation record as well as with the proper determination of occlusal vertical relation. Proper location of low and high lip lines must be determined to determine the required changes in teeth position or angulations.

- Presence of any infection or inflammation in the soft and hard tissues. Periapical abscess, granuloma and cysts may make the estimated tissue changes at the time of extraction and healing and remodeling process unpredictable, this may increase of the risk of unfitted immediate denture.
- Previous prosthesis, **(if present)** must be checked as an additive reference for the jaw relations or teeth selection. It also may help the dentist to explain some of treatment or correct some errors.
- In many cases of immediate denture construction, a diagnostic casts are essential. These casts could serve a lot in the treatment plan and communication with the patient. the casts also can be used as a pre-extraction record.
- All immediate denture patients must have good oral prophylaxis, proper scaling and good oral hygiene, this will reduce postoperative edema and infection. Other treatments as restoration crown and bridges or even RPD all must be one coincidence with immediate denture planning.

In the diagnosis step; with all the collected information you have to decide type of surgical procedure, **immediate denture can be constructed with one of the surgical procedure:**

1. Extraction of teeth only.
2. Extraction of teeth with alveoloplasty.

In some case simple corrections may be needed at the sight of extracted teeth to improve the shape of the alveolar process in order to facilitate and improve denture objectives. In these cases surgical splint construction is important. This splint usually constructed on the master cast after teeth trimming. Cases with excessive bone correction may be end up with rapid bone resorption and unfitted denture, therefore bone removal must be conservative. Consultation with the surgeon is essential in some cases.

## Impression:

Successful primary impression is governed by proper stock tray selection, proper material selection and manipulation (usually irreversible hydrocolloid material is used) and well trained dentist to handle and make the impression in a proper technique.

- Stock tray metal or plastic must extended to cover the intended denture bearing area able to record the vestibule extension, it must cover the retromolar area in the lower arch and extended posteriorly to include tuberosity and hamular notch in the upper arch. Enough space between the tray and the oral tissue to have enough and uniform thickness of the impression material; this does not mean to use oversized tray because it distort the tissue and recording procedure. Wax sheet may be used to complete minor under extension. The impression must be free of voids fully extended according to the planned prosthesis design.
- In some cases when the remaining teeth are very loose, there is a risk of teeth extraction during impression making, **so try to fix these tooth either by.**
  1. applying a lubricant medium to the teeth .
  2. in case of adjacent teeth to each other's applying molding soft wax into sub-contact point spaces and around the necks of teeth so that the impression material is prevented from locking into the undercuts .
  3. in case of solitary tooth placing a loose fitting copper band over the tooth before taking impression.
  4. placing holes in the tray and using an amalgam condenser to release the tray over the loose tooth.

## The primary impression:

May be useful as a final impression in case of immediate single tooth replacement with or without short span partially edentulous arch.

- ✓ Primary cast is delivered by pouring the primary impression with any of the gypsum products.
- ✓ This cast helps as a study cast to plan the sequences of the treatment as well as used to construct special tray.
- ✓ surveying, undercuts block out and relief must be done on the cast.

### **The Final impression:**

Different tray design and impression techniques were described to deliver final impression, these techniques may range from simple to more complicated depend on tray design and material used.

### **Selection of a suitable technique depending on:**

- a. Case difficulty.
- b. Number and location of teeth included in the immediate denture treatment.
- c. Teeth and tissue undercut.
- d. Type of the planned surgical operation, impression material.
- e. Dentist skill and experience.

The imperative technique is that record the tissues and denture bearing area in a maximum accuracy that minimize the insertion, post-extraction denture adjustment and maintenance phases as possible.

Special tray is constructed on the primary cast, cold cure resin is a suitable material.

### **Final impression may be taken by:**

#### **Single full arch custom tray:**

- ☒ This technique can be used for conventional immediate denture and the only tray used for interim immediate denture.

- ☒ Also, it is used when the patient have anterior teeth only or anterior and posterior remaining teeth.
- ✓ Technically; first of all, on the primary cast outline the tray extension to be shorter than the vestibular depth by 2 mm and include the posterior limit.
- ✓ The remaining teeth must be covered with single layer of sheet wax; then second layer is used to cover all the area needed to be recorded by the impression and covered with the denture; this technique usually used in conventional immediate denture while in interim immediate denture all the teeth and denture foundation area are blocked using two layers of wax. Tissue undercut must be blocked properly to facilitate tray removal.
- ✓ A stops effect is provided by making 4-5 regular holes through the wax, symmetrically distributed anteriorly and posteriorly.
- ✓ Finally adapt the cold cured acrylic resin dough layer to fabricate the special tray; ensure proper extension and stops holes are filled with acrylic. The handle can be placed on the anterior area as usual or you may place it in the mid of the palate to prevent over lengthening of the tray in the anterior area might interfere with impression making.
- ✓ Allow the resin to set; then remove the tray and reduce excess material, finish and smooth the borders and surfaces. Proper perforations must be done symmetrically -as possible- or using adhesive depending on used impression material.
- ✓ This technique can be used when the anterior teeth are remaining only or when anterior and posterior teeth are present.
- ✓ Now check the tray in the patient's mouth and do border molding by using tracing compound; in the same manner as in conventional complete denture and continue to do final impression.
- ✓ You may use irreversible hydrocolloid or polyvinyl silicone or polysulfide rubber base or polyether as a final impression material. More expert dentist may use 2 impression material in one tray for maximum accuracy.

### Sectional impression tray OR split impression tray technique

- ❖ Use two trays or sectional custom tray.
- ❖ This technique is used in conventional immediate denture only; and cannot be used in interim immediate denture.
- ❖ It involves construction of two trays on the same cast one for the posterior region made as in complete denture and the 2nd is constructed for the anterior region backless tray indices or references must be made in the tray.

#### **Procedure:**

- ✓ Outline the tray extension in the same manner as in 1st technique.
- ✓ Block all tissue undercuts and interdental spaces.
- ✓ Use proper separating medium then adapt the cold cured resin mix to the posterior edentulous area and extend it to cover the lingual surface of the anterior teeth beyond the incisal edge then put the handle.
- ✓ **For the anterior region; you may use:**
  - construct a custom tray to cover this area only. Alternatively, the impression material may be carried to the mouth in a second sectional tray that is indexed to the primary tray. In either case, the anterior section impression will capture the facial anatomy of the teeth, the vestibular anatomy, and indices on the primary impression/tray. Upon removal of the anterior and posterior sections separately, the two sections are reassembled outside the mouth (using the indices) and prepared for casting.
  - you may adapt and cut a plastic stock tray to fit the anterior section.
  - expert dentist prefer not to use a tray but they use a heavy mix of elastomeric impression material in the mouth.
- ✓ The anterior section of the impression must record the labial aspect of the teeth as well as the vestibular area.
- ✓ To make the impression, the posterior sectional tray (must be tried for proper extension, border molding is made with tracing compound) as in conventional complete denture, then final impression for edentulous area is made by using zinc oxide eugenol impression material or polyvinyl

silicon or polysulfide or polyether, you can use non-elastomeric impression material here.

- ✓ The most important thing in sectional impression tray is the accuracy and proper seating of the trays and reassembling both. Care must be taken not to distort this assembly during tray removal from the mouth or during pouring therefore it's advisable to bead and box the impression before pouring.
- ✓ Modification of the above technique can be made as to make a full tray covering the denture bearing area with a hole opposite to the teeth area, again we do border molding and impression then a proper stock tray over the custom one can be used to capture the teeth area with alginate material.
- ✓ Finally when you remove the impression from patient's mouth it will record the whole denture bearing area made by two different materials.
- ✓ This technique is used mainly when the posterior area is edentulous and only anterior teeth are remain and need to be replaced with immediate denture.

**Note:** the projections on the external tray surface serve as indices.

- ✓ It is also possible to use special tray instead of stock tray but it is essential to put the indices or references to ensure reassembling.
- ✓ The final impression must be poured with stone to get the master cast; this cast is used to prepare the record base and the occlusion rim.

### **Beading and boxing:**

All the impression must be beaded before pouring. Wax may not stick to the alginate impression material, therefore care must be taken to insure proper beading. Once you fix beading wax, boxing wax sheets can be easily stick to the impression. In the sectional impression, be careful to seat the sections properly on the indices. Pour the impression and remove the tray as in the conventional manner.

**Record base and occlusion rim:**

Bite rim usually constructed to record jaw relations

- If the patient have enough number of remaining anterior and posterior teeth no need for record base or bite rim as in most of interim immediate denture.
- while if there isn't enough number of remaining teeth as in all of conventional immediate denture and some of the interim immediate denture cases; bite rim must be constructed.
- Before constructing the record base, all teeth and tissue undercuts must be blocked by wax, then cold cure acrylic dough is applied on the edentulous area of the cast. When the material set, record base must be finished and polished; final evaluation must show a stable properly extended record base.
- Wax occlusion rim is added to the corresponded edentulous area on the base. Leveling of the wax must depend on some anatomical landmarks as the retromolar area and you may use the remaining teeth but not always.
- Record base extension and wax rim height must be evaluated clinically. Lip lines; high and low must be determined and marked on the cast, in this way any correction or modifications can be done or marked on the cast to be considered in the teeth setting.

**Jaw relations record:**

Include vertical and horizontal relations, these usually made as in the conventional denture construction.

- If we have vertical stops between two opposing posterior teeth, these relation are maintained unless further corrections are needed to improve esthetic or function.
- Evaluation of the existed vertical dimension of occlusion must be accomplished and dentist must decide if this going to be restored or modified.



- Uneven tooth loss, teeth wear, loosening of the remaining teeth drifting and extrusion all may indicate correction of vertical relation.
- The occlusion rim and sometimes remaining teeth must be adjusted for correct occlusal vertical dimension.
- In the immediate complete denture; leave first premolars bilaterally to maintain vertical and horizontal relations and facilitate recording of the jaw relations.
- In this visit dentist must record the midline, canine lines, ala-tragus line, smiling and high lip line, anterior occlusal plane In relation to the remaining teeth.
- Face bow transfer and centric Jaw relation must be recorded.
- Once you record vertical and horizontal relations you are ready to mount the cast on a suitable articulator.
- Selection of artificial teeth, acrylic teeth are the recommended type.
- Consider all parameters in teeth selection, in the anterior and posterior segment. Shade, Size, form, an occlusal form of posterior teeth must be selected to fit each case specifically.
- Arrangement of posterior teeth done in the same way as in the conventional complete denture, maintain proper occlusal plane.

### Try-in

- In this way you set the posterior or anterior missing teeth to try it in the patient's mouth check and verify occlusal plan and jaw relations in the try-in step.
- Try in step is not possible in every immediate denture case but even so mounting of the master casts must be confirmed in patient's visit.
- In most of conventional immediate denture cases posterior teeth are missed so you can set the posterior teeth as in conventional complete denture construction following the rules of teeth arrangement in the centric occlusion.

- The trial denture now must be tried in the patient's mouth and verify the vertical and centric relations.
- If errors can be detected in the centric relation, lower cast must be remounted after a new record and teeth must be reset.
- Confirm all the landmarks recorded in the diagnostic step to set the patient's desire as:
  - The midline whether it is the same or verified but it is very important to inform the patient if you decide any change prepare yourself to explain the reasons for the patient.
  - The anterior plane of occlusion; teeth may be extruded-or over erupted so correct plane of occlusion must be recorded on the casts. Use some of the anatomical landmarks interpupillary line and parallelism with the ala-tragus line.
  - High lip line must be determined and marked on the cast. Discussion must be made with the patient about the amount of display of the teeth and gingiva.
  - Localized alveoloplasty or some changes in the teeth alignment may be suggested to improve appearance. Make sure that the patient sees and approves this.
  - Diastema , rotated teeth, overjet and overbite and other natural variations must be discussed with the patient because some patient may ask for a perfect looking even if they never had, others may like their natural variations( in this way nobody can notice the denture). Dentist may share his experience, knowledge and opinion for best results especially when the patient ask for changes or variations interfere with function and esthetic principles. The patient must be actively involved in the decisions of esthetics.
  - Always reevaluate final result after every changes.
- All the required change must be recorded on the cast as well as on the case sheet.

- In this visit further information about the following must be given, Surgical procedures, tissue changes as edematous and discoloration few days after insertion, local sense of lip puffiness even when the edema dissolved due to the flange extension.
- Answer all the questions asked by the patient directly and very clear.
- At the end of the try in visit you have to check all what is related to the present teeth and mark all what you have to change- teeth and tissues.

### **Cast trimming:**

- The remaining teeth now must be trimmed to be replaced with artificial teeth.
- Trimming of the cast must be done carefully to estimate as possible the shape of the residual ridge after teeth extraction.
- Final cast ridge must be similar to the contour of the foundation area after teeth extraction.
- More than one method may be use to trim and set the teeth in immediate denture cases,

### **It depends on:**

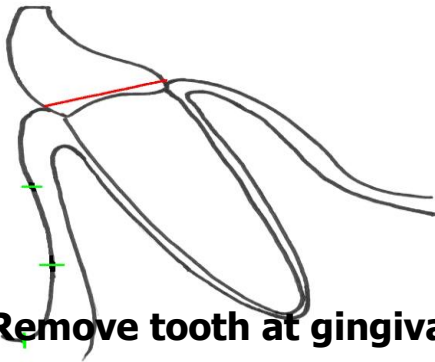
1. If you decide to duplicate same teeth alignment or not.
2. Esthetic and functional requirement.
3. Amount of changes expected during surgery.

Usually teeth are trimmed by using a saw or disc bur sharp knife or wax knife may help.

Scribe guidelines on the cast recording the position, angulations and incisal level of the natural teeth (In this step it must follow the rule of third to guide cast trimming).

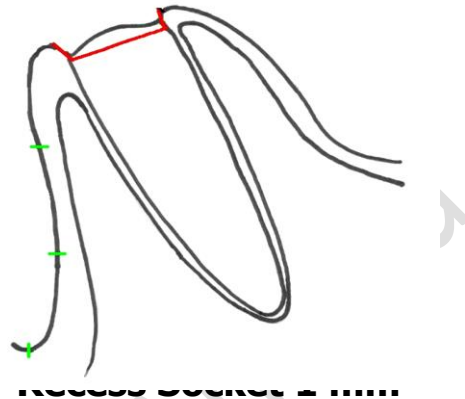
Steps of trimming are:

**Step 1**

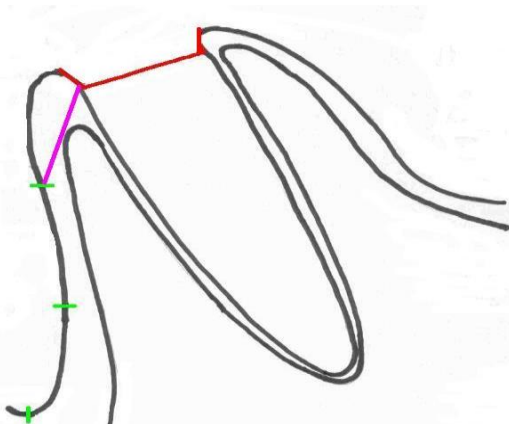


**Remove tooth at gingival level**

**Step 2**

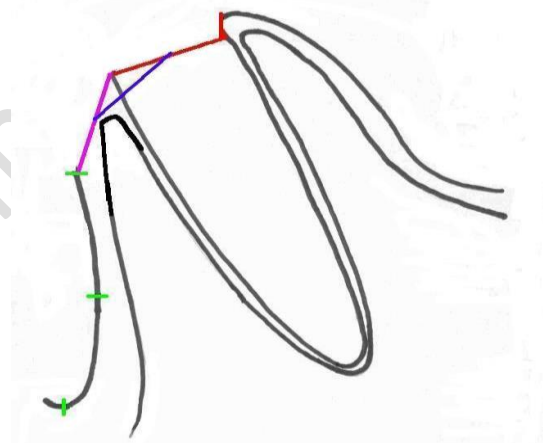


**Step 3**



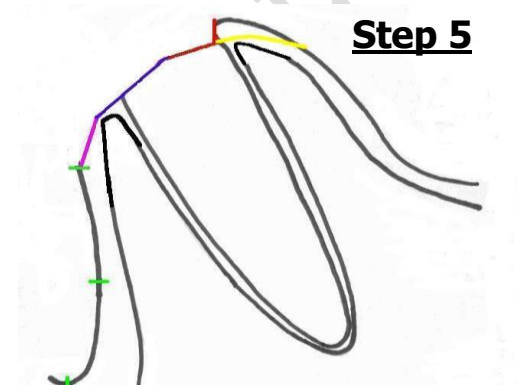
**Labial edge recess to incisal third mark**

**Step 4**



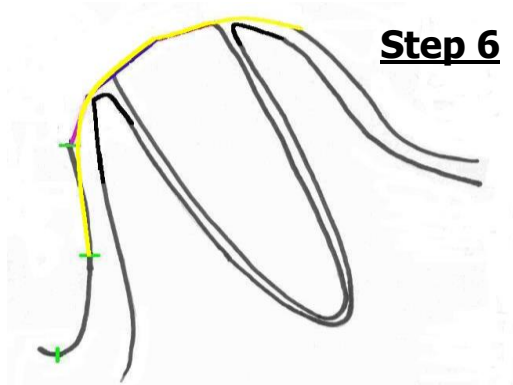
**Mid-point recess to mid-width labial cut**

**Step 5**



**Round over lingual aspect of socket**

**Step 6**



**Round off labial to middle third, sand smooth**

- Note that the amount of grinding is very minimal on the palatal side, this is because the remodeling after extraction is usually minimal in this side.
- Final ridge form must be round and continuous from the buccal and lingual surfaces.
- Cast trimming may be done at same time of teeth arrangement.
- Do not change or trim the essential landmarks as incisive papilla or any frenum.

### Waxing and flasking :

- Generally immediate denture is thinner than the conventional CD especially in the anterior, but be careful at time of insertion and in the presence of undercut the acrylic must be thick enough to be adjusted.
- In this step you have to custom any selected personalization criteria must be carved.

### Surgical splints:

- After complete cast trimming, surgical splint must be constructed
- It is a thin transparent form of tissue surface of the immediate denture, it is used to guide the surgical shaping of the alveolar process.
- It is essential when there is a need to do some alveolar corrections after teeth extraction or ridge recontouring or correction of the inter septal bone or in multiple teeth extraction.
- ✓ Make alginate impression on the cast after trimming.
- ✓ Pour the impression (cast duplication).
- ✓ Make the clear template processed either by heat or light ,vacuum form and sprinkle-on method can be Used also.
- **Advantage:** Splints also help to remove any expected pressure area at the sight of extraction thus minimize insertion time and adjustment at the insertion time.

## Setting of anterior teeth:

Arrangement of anterior teeth can be made in different ways, we have to decide:

1. If the teeth are need to be changed in location or alignment to improve the aesthetic.
2. The teeth are well aligned, aesthetically and functionally acceptable; then we can reproduce same alignment in the denture.

### ■ First way:

Produce a labial index of the natural teeth before they are cut off the cast.

The index can be produced quite simply by molding silicone putty against the labial surface of the teeth and ridge on the cast, wait till the material set, trim the cast, then the artificial teeth can be set into the index while its held against the cast preserving same teeth location.

In this technique same teeth morphology and location is duplicated, thus consultation with the patient about own teeth alignment and morphology must be made at the time or diagnosis.

### ■ Second way:

Remove one tooth from the cast and immediately wax an artificial tooth into position so that the adjacent teeth serve as a guide to the positioning of the artificial replacement. Repeat this procedure alternatively, this is called the alternative or every other method; you can use every tooth as an index to arrange same tooth but in the other side OR trim all the teeth on one side and use the other side as a reference.

## Processing and finishing

- It is same as in the conventional complete denture.
- Do not remove posterior undercut and try to modify the path of insertion.
- Keep both the denture and the splint template in the disinfectant to delivery.

**Insertion:****At the day of surgery and insertion:**

- ✓ Examine the patient intraorally to check for any changes.
- ✓ Extraction of the marked teeth; preserve the labial plate and be conservative, no bone trimming is done without guiding; use suture if necessary.
- ✓ Use the surgical template to guide any alveolar corrections. Seat the template: blanch areas seen through the template indicates pressure, then need correction.
- ✓ Insert the denture; remove all the detected over extended especially heals areas and correct any pressure areas. Check the frenum relief.
- ✓ Check for firm bilateral occlusion with no gross occlusal interference quickly correct.
- ✓ In some cases the denture is not retentive and loose this is mostly occurs in the improper diagnosis and preparations or unexpected surgical problems.
- ✓ Usually we use the tissue conditioner to retain the denture BUT do not allow the material to extend in the socket areas otherwise normal socket healing will be compromised.
- ✓ At the day of insertion try to reduce the numbers on insertion and removing of the denture to avoid trauma and edema.

**Post-operative care and instructions:****First 24 hour:**

- ✓ Avoid removing the immediate denture.
- ✓ Put gentle biting pressure on your denture during the first four hours.
- ✓ Avoid hard food and eat soft healthy food, avoid drinking hot fluids.
- ✓ Using ice pack in the first 24h (20 min on followed by 20 min off) may control inflammation and swelling.
- ✓ Patient should be reminded that the pain from extraction will not reduce by removal the denture.
- ✓ Analgesic, antibiotic, must be prescribed to patient depending on the case.

- ✓ There may be some oozing of blood. The denture acts as a bandage to protect the extraction sites and helps to control bleeding and swelling.

### **1st Adjustment must be seen after 24 hours:**

- ✓ The denture should be kept out of patient mouth only for short time, therefore quickly checking the tissue sore spots, over extension and any gross occlusal discrepancy.
- ✓ On removal the denture may be painful; inform the patient and adjust sore area which appears as deep red areas mostly undercuts as canine eminence, tuberosity, and retro mylohyoid ridge.
- ✓ Adjust occlusion.
- ✓ Assess retention and use tissue conditioner if needed.

### **1st week after extraction and denture insertion:**

1. Instruct your patient to wear the denture day and night for first 7 days after extraction or until swelling reduction.
2. Remove the denture 4 or 5 times a day after the first day, and rinse the mouth with warm salt water. Do this for the first week.
3. The denture must be cleaned and rinsed after meal as early as possible and when removal and insertion of the denture is with little or tolerable pain.

### **Further follow up care:**

1. 2nd week is the next call, this is depend 0 the case. Then the patient should be seen one month later, 4-6 months intervals.
2. A denture adhesive will be necessary to help hold the denture in place.
3. Relining may be necessary to achieve esthetic and occlusion corrections.
4. Frequent or periodic recall mainly for changing temporary liner, this is depend on the rate and amount of bone resorption and ability of patient to keep the liner clean