

Development of occlusion

The development of dentition is an important part of craniofacial growth as the formation, eruption, exfoliation and exchange of teeth take place during this period.

According to Angle occlusion is "The normal relation of the occlusal inclined planes of the teeth when the jaws are closed"

According to Ash and Ramfjord occlusion is the " The contact relationship of the teeth in function and parafunction"

Periods of Occlusal development can be divided into the following development periods:

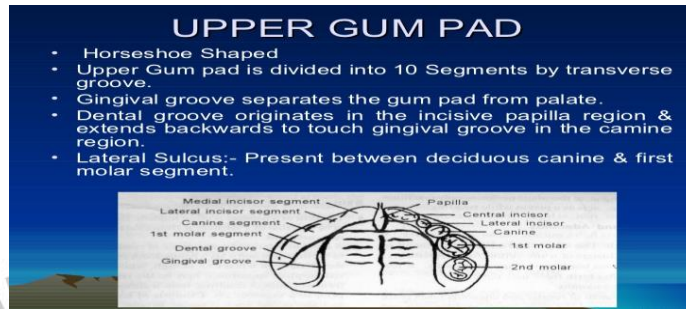
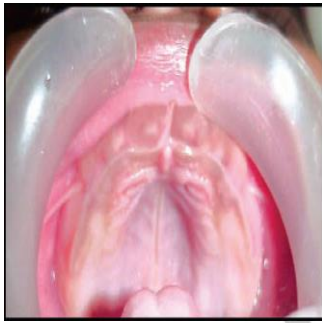- 1-Neo-natal period (at birth).
- 2- Primary dentition period.
- 3- Mixed dentition period.
- 4- Permanent dentition period

Neonatal period

Alveolar processes at the time of birth known as gum pads. Which is Pink in color, firm and are covered by a dense layer of fibrous periosteum , the pads get divided into 'labio- buccal' & 'lingual portion', by a dental groove, and gum pad soon gets segmented into 10 segment by a groove called transverse groove, & each segment is a developing tooth site. The groove between the canine and the 1st molar region is called the lateral sulcus which helps to judge the inter-arch relationship.

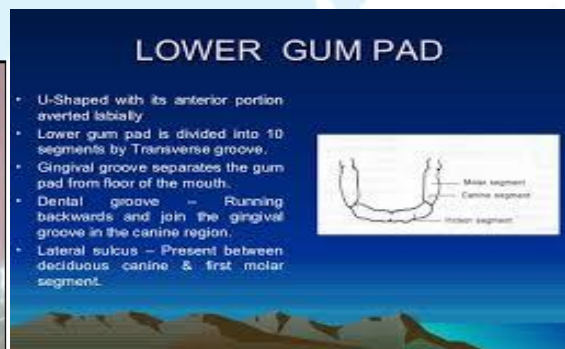
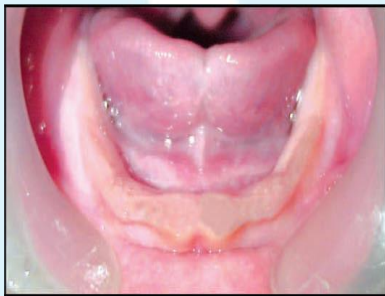The upper gum pad is horse shoe shaped, **shows**

- Gingival groove separates gum pad from the palate
- Dental groove starts at the incisive papilla, extends backward to touch the gingival groove in the canine region & then moves laterally to end in the molar region
- Lateral sulcus.



The lower gum pad U shaped , characterized by

- Gingival groove lingual extension of the gum pads
- dental groove
- Lateral sulcus.



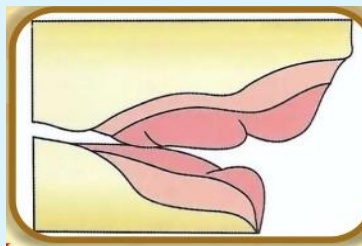
Relationship of Gum Pads

- ❖ Anterior open bite is seen at rest with contact only at the molar region.
 - ❖ Upper gum pad being more wider and longer than lower gum pads thus when approximated a complete over jet present all around.
 - ❖ Class II pattern with the maxillary gum pad being more prominent Mandible is distal to the maxilla and usually the upper jaw overlap the lower jaw in anterior posterior and transverse direction.
 - ❖ Mandibular lateral sulci posterior to maxillary lateral sulci
- The anterior opening of the mouth will facilitate the feeding process without discomfort to the mother, at this stage the labial frenum is usually attached to the incisive papillary region and after the eruption of the deciduous teeth it will migrate in upward direction and gives the incisive papillary attachment is due to alveolar bone formation in association with the development of deciduous teeth ,the upper lip at this

stage is usually short, and the anterior oral seal of the mouth occurs due to the contact between lower lip and the tongue.

Neonatal Jaw Relationships

Mandibular functional movements are mainly vertical and to a little extent anteroposterior. Lateral movements are absent, precise bite or jaw relationship is not yet seen, therefore neonatal jaw relationship can not be used as a diagnostic criterion for reliable prediction of subsequent occlusion in primary dentition.



The newly born child's mouth is usually without teeth, sometimes natal teeth that are present above the gumline (have already erupted) at birth.

Neonatal teeth or Early Infansive teeth that erupt during the 1st month of life. These teeth look like the deciduous teeth.

Pre-erupted teeth erupt during the second or third month.

They are contained enamel, dentine and pulpal tissue and usually without roots or there is a very short root with them. No intervention is usually recommended unless they are causing difficulty to the infant or mother.

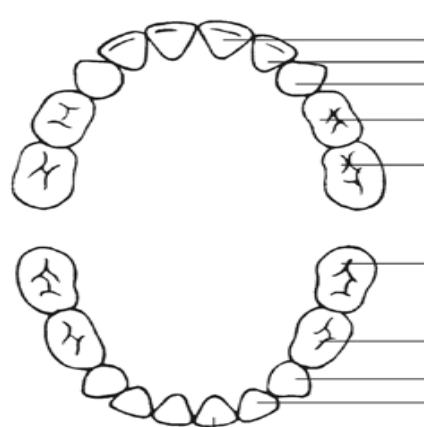
The incidence of natal and neonatal teeth is estimated to be 1:1000 and 1:30000 respectively. These teeth are almost always mandibular incisors, which frequently display enamel hypoplasia. There are familial tendencies for such teeth. They should not be removed if normal but removed if supernumerary or mobile.



Deciduous Dentition

Deciduous teeth or **primary teeth**, are the first set of teeth in the growth development of humans. They develop during the embryonic stage of development starts at the sixth week of tooth development as the dental lamina, there are ten buds on the upper and lower arches that will eventually become the primary (deciduous) dentition. These teeth will continue to form until they erupt and become visible in the mouth during infancy, there are a total of twenty teeth that is made up of central incisors, lateral incisors, canines, first molars, and secondary molars; there is one in each quadrant, making a total of four of each tooth: five per quadrant and ten per arch. The eruption of these teeth (teething) starts from the eruption of the first deciduous tooth, usually the deciduous mandibular central incisors and ends with the eruption of the first permanent molar, i.e. from 6 months to 6 years of postnatal life. By 2½ years of age, deciduous dentition is usually complete and in full function. Root formation of all deciduous teeth is complete by 3 years of age.

The sequence of eruption and shedding of deciduous teeth



Upper Teeth	Erupt	Shed
Central incisor	8-12 mos.	6-7 yrs.
Lateral incisor	9-13 mos.	7-8 yrs.
Canine (cuspid)	16-22 mos.	10-12 yrs.
First molar	13-19 mos.	9-11 yrs.
Second molar	25-33 mos.	10-12 yrs.
Lower Teeth	Erupt	Shed
Second molar	23-31 mos.	10-12 yrs.
First molar	14-18 mos.	9-11 yrs.
Canine (cuspid)	17-23 mos.	9-12 yrs.
Lateral incisor	10-16 mos.	7-8 yrs.
Central incisor	6-10 mos.	6-7 yrs.

Normal Signs of Primary Dentition

- 1-Ovoid arch form
- 2- Straight or vertical inclination of the incisors

3- Deep bite are present this could be due to vertical inclination of primary incisors over a period of time these deep bite reduced due to eruption of primary molars ,rapid attrition of incisors and forward movement of the mandible due to growth , and which change to edge to edge relationship

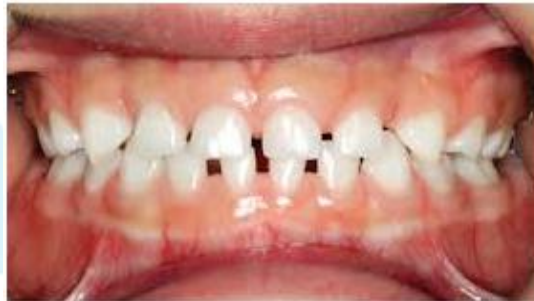4-Minimal overjet and absence of crowding.

Two types of primary dentitions seen

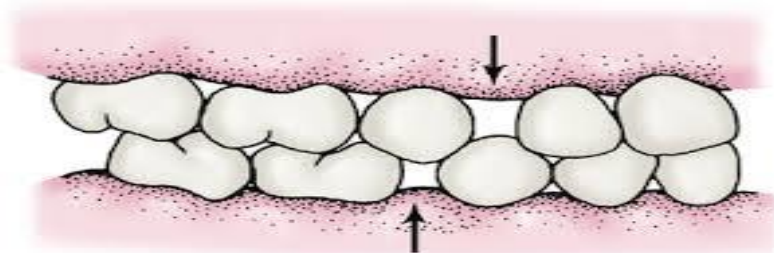
A- **Closed primary dentition:** absence of spaces is an indication that crowding of teeth may occur when the larger permanent teeth erupt.

B- **Spaced or opened primary dentition:** in which interdental spaces are present called spaced dentition there are 2 types of spacing.

1- **Physiologic or generalized spaces:** usually seen in the deciduous dentition to accommodate the larger permanent teeth in the jaws, More prominent in the anterior region.



2- **Primate spaces or anthropoid spaces:** naturally occurring spacing between the teeth of the primary dentition. In the maxillary arch, it is located between the lateral incisors and canines, whereas in the mandibular arch the space is between the canines and first molars, This space is used for early mesial shift.

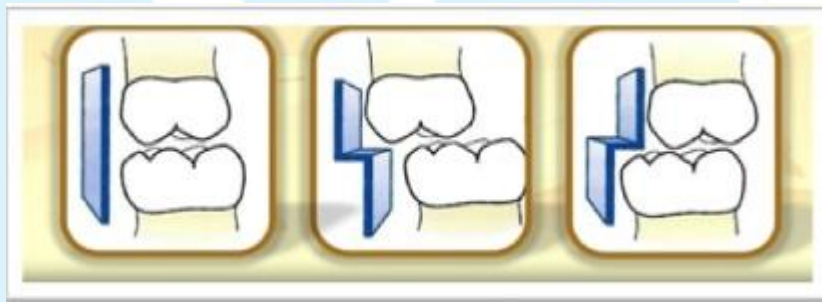

molar relation in primary dentition described in terms of terminal plans, terminal planes are the distal surfaces of the 2nd primary molars, these two planes can be related in **3** ways:

1-Flush terminal plane: both maxillary and mandibular planes are at the same level anteroposteriorly, normal molar relationship in the primary dentition, because the mesiodistal width of the mandibular molar is greater than the mesiodistal width of the maxillary molar.

2-Mesial terminal plane: maxillary terminal plane is relatively more posterior than the mandibular terminal plane forming a mesial step.

3-Distal terminal plane: the maxillary terminal plane is relatively more anterior to the mandibular.



All of primary teeth are gradually replaced with a permanent, but in the absence of permanent replacements, they can remain functional for many years. The replacement of primary teeth begins around age six, when the permanent teeth start to appear in the mouth, resulting in mixed dentition. The erupting permanent teeth cause root resorption, where the permanent teeth push on the roots of the primary teeth, causing the roots to be dissolved by odontoclasts (as well as surrounding alveolar bone by osteoclasts) and become absorbed by the forming permanent teeth. The process of shedding primary teeth and their replacement by permanent teeth is called **exfoliation**. This may last from age six to age thirteen. By age twelve there usually are only permanent teeth remaining. However, it is not extremely rare for one or more primary teeth to be retained beyond this age, sometimes well into adulthood, often because the permanent tooth fails to develop.

The spaces of the deciduous teeth try to increase with age due to growth of the jaws in anteroposterior, vertical, and transverse

direction, and due to attrition, and these teeth subjected to large amount of attrition due to wear at the incisal edge, and proximal surfaces since the deciduous teeth mostly converted to edge to edge relationship at late stages, the occlusal forces with root resorption will increase the mobility of the deciduous teeth and if the closed case (no spacing) this will produce attrition at the proximal surfaces due to friction produced by movement during mastication, so the mobility progress the spaces to increased and this will facilitated the normal shedding of the incisors.

Mixed Dentition period

(Around 6 years- 13 years) Most malocclusions make their appearance during this stage The mixed dentition period can be divided into:

1. First transitional period.
- 2- Inter-transitional period.
- 3- Second transitional period.

First Transitional Period

Emergence of the first permanent molars and transition of incisors
The following events take place during this period.

Eruption of Permanent First Molars

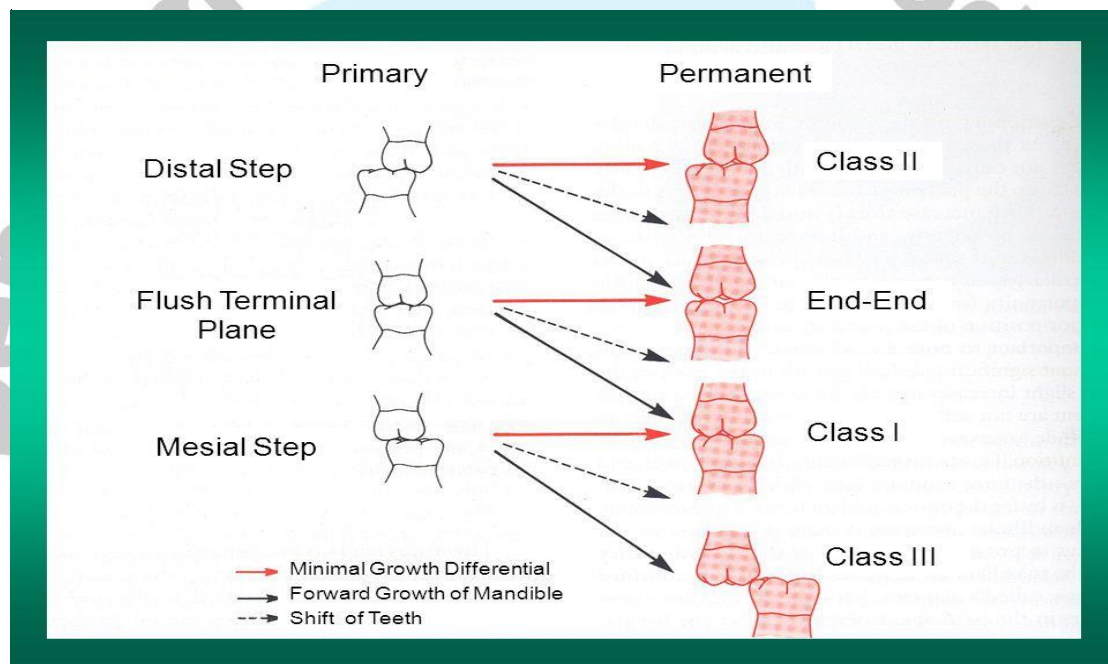
The first permanent molars erupt at 6 years. They play an important role in the establishing and in the functioning of occlusion, in the permanent dentition.

Anteroposterior positioning of the permanent molars is influenced by:

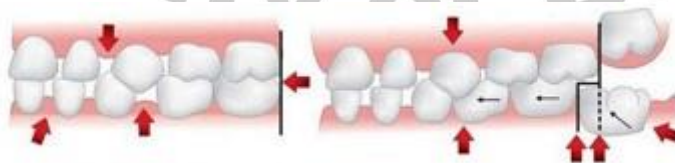
Terminal plane relationship the distal surface of the upper & lower 2nd deciduous molar. When the deciduous second molars are in a flush terminal plane, the permanent first molar erupts initially into a cusp-to-cusp relationship, which later transforms into a Class I molar relation using the primate spaces. Later, cusp-to-cusp relationship of the permanent first molar can be converted to a Class I relationship by the mesial shift of the permanent first molar following exfoliation of the primary molar and thus making use of the Leeway space (late mesial shift)

Distal Step: When the deciduous second molars are in a distal step, the permanent first molar will erupt into a class II relation. This molar configuration is not self correcting and will cause a class II malocclusion despite Leeway space and differential growth.

Mesial Step: Primary second molars in mesial step relationship lead to a class I molar relation in mixed dentition. This may remain or progress to a half or full cusp class III with continued mandibular growth

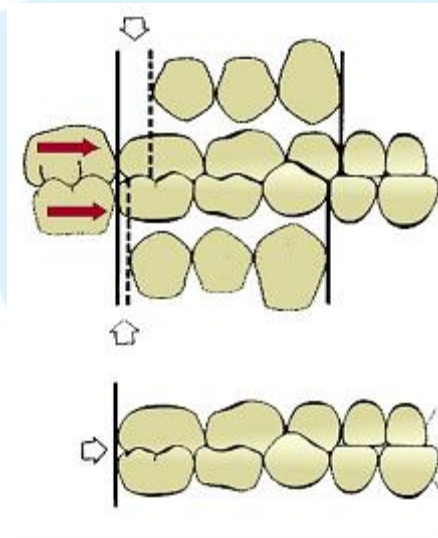


Early mesial Shift: Early shift occurs during the early mixed dentition period. Since this occurs early in the mixed dentition, it is called early shift, the eruptive force of first permanent molar push the deciduous 1st & 2nd deciduous molar to close the primate space. In a spaced arch, eruptive force of the permanent molars causes closing of any spaces between the primary molars or primate spaces, thus allowing molars to shift mesially



Late mesial Shift: This occurs in the late mixed dentition period when the second deciduous molar exfoliate the first permanent molar drift

mesialy & use leeway space and is thus called late shift. When the primary second molar are lost there is an adjustment in the occlusion of the first molar teeth, There is a decrease in arch length in both maxillary and mandibular arches as the first molar shift mesially this shift is more in mandible which accounts for the establishment of full cusp molar class I relation from flash terminal plane relationship in deciduous dentition this shift is called late mesial shift of molars.

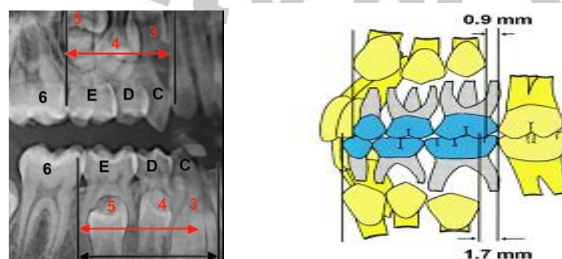


Leeway Space of Nance

Described by Nance in 1947 (the combined mesiodistal width of the permanent canines and premolars 3,4 and 5 is usually less than of the deciduous canines and molars CD&E).

Maxilla: 0.9 mm/segment = 1.8 mm arch .

Mandible: 1.7 mm/segment = 3.4mm arch



Exchange of Incisors:

Transition of Incisors Permanent incisors develop lingual to the primary incisors. For incisors to erupt in normal alignment, there is an obligate space requirement in the anterior part of both the arches which is termed as the incisal liability (permanent incisors is larger than deciduous incisors the difference between the amount of space needed for the incisors and the amount available for them) is overcome by the following factors:

- 1- Interdental physiological spacing in the primary incisor region. (4 mm in maxillary arch & 3 mm in mandibular arch)
- 2-Increase in inter-canine arch width: Significant amount of growth occurs with the eruption of incisors and canines
- 3-Increase in anterior length of the dental arches: Permanent incisors erupt labial to the primary incisors to obtain an added space of around 2-3 mm, change in inclination of permanent incisors, Primary teeth are upright but permanent teeth incline to the labial surface This increases the arch parameter .

Change in inclination of permanent incisors:

Primary teeth are upright but permanent teeth incline to the labial surface thus decreasing the inter-incisal angle from about 150° in the deciduous dentition to 123° in the permanent dentition This increases the arch perimeter

