

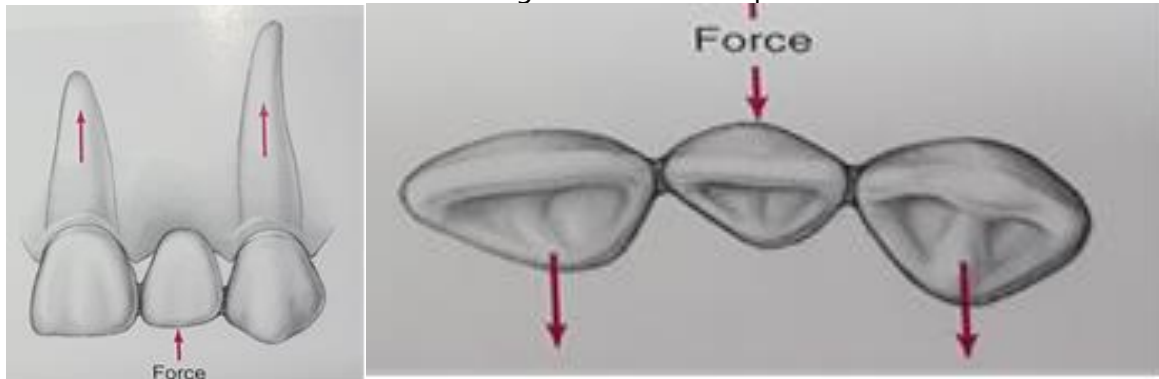
Crown and bridge Prosthodontics

Lecture: 3

Prof. Adel Farhan Ibraheem

Evaluation Abutment tooth:

Abutment in fixed prosthodontic terminology is a tooth or portion of a tooth that used for the support and/or retain of a fixed bridge or part of the bridge, to which retainer is connected (cemented). All the forces that would normally be absorbed by the missing tooth are transmitted, through the pontic, connectors, & retainers to abutment teeth. Abutment teeth must withstand forces normally directed to the missing teeth, in addition to those usually applied to the abutments, therefore, **the choice of abutment is important** because it has to withstand both the forces acting on it and on the pontic.



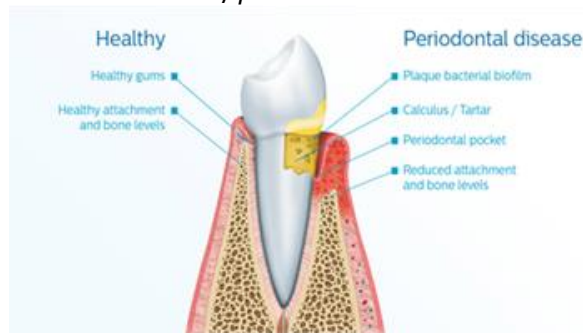So the clinician have to evaluate the abutment teeth carefully

EVALUATION AIDS

- CLINICAL EXAMINATION USING EXAM.TOOLS
- VITALITY TEST
- RADIOGRAPHS
- DIAGNOSTIC CASTS
- PERIODONTAL PROBE

Requirements;

- 1) *Abutment must withstand the forces normally directed to the missing teeth; whenever possible the abutment should be vital tooth.*
- 2) *A tooth that has been endodontically treated & symptomatic with radiographic evidence of good seal & complete obturation of the canal can serve as abutment (Post & core for retention & strength).*
- 3) *The supporting tissue surrounding the abutment teeth must be healthy & free of inflammation.*
- 4) *The abutment teeth should not exhibit any mobility, since they will be carrying an extra load. Sever uncorrectable, periodontal disease is contraindicated For F.P.D*



Abutment evaluation (selection):

FACTORS RELATED TO TOOTH (ABUTMENT)

1. Health of abutment (caries or pulpal):

- *A sound abutment tooth permits ideal type of preparation. Caries tooth may be used as abutment provide that caries is removed the pulp protected (lining) and the tooth is restored to its original form by suitable filling material.*
- *If the caries far away from margin and small and the retainer design will extend beyond the caries area, cement or resin can't be used in state of metal.*
- *Extensive caries need extraordinary filling technique and preparation to conserve and support remaining tooth structure.*
- *Pulpless teeth can be used only after endodontic treatment.*

2. SHAPE;

Some teeth have conical, peg, bulbous or tapered crown form that interferes with the preparation parallelism, necessitating full coverage crowns to improve aesthetics and retention. • Examples:

- *Peg laterals*
- *Anterior teeth with poorly developed cingula and short proximal walls*
- *Mandibular premolars with poorly developed lingual cusps and short proximal surface*
- *Thin incisors.*

3. CROWN LENGTH

- *The abutment teeth must have adequate occlusocervical crown length to achieve sufficient retention.*
- *Full coverage restorations and crown lengthening are considered with short clinical crowns to ensure adequate retention.*

3. Size of the crown:

- ***It determines the type of retainer to be used. For example: short, thin, conical, tapered teeth are poor indication for partial veneer crown.***
- ***The height of the clinical crown is closely related to retention.***

4. Axial relationship:

- a) *Rotation, tilting, over lapping, mal-position might lead to decision of precluding of such a tooth to be used as abutment (because rotation or torque can damage supporting structure or cause retainer to become loose).*
- b) *Also it may indicate the use of specific retainer (over reduction lead to weaken the tooth & endanger pulp health).*
- c) *Rotation lead to either increase or decrease of space available for pontic (size of pontic planned).*

FACTORS RELATED TO ROOT & GINGIVO PERIODONTAL COMPLEX

5. Condition of supporting tissue;

- *The supporting tissue surrounding the abutment teeth must be healthy & free of inflammation ,the abutment teeth should not exhibit any mobility, since they will be carrying an extra load. Intra oral radiograph should be used to evaluate bone architecture*
- *The alveolar bone support is one of most important factors that aid to evaluate an abutment*
- *The supporting alveolar bone should be healthy*

- It should have good trabecular architecture and show no sign of bone defect or bone loss

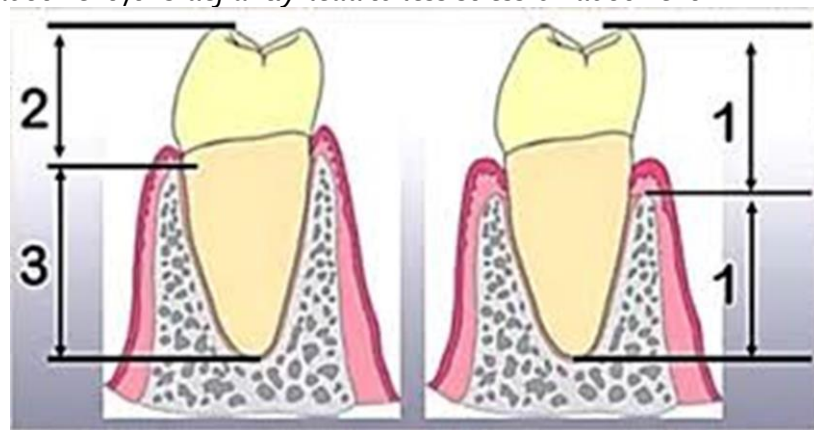
The roots & supporting tissue should be evaluated for the following:

- CROWN - ROOT RATIO
- ROOT CONFIGURATION
- PERIODONTAL AREA

A. Crown –root ratio:

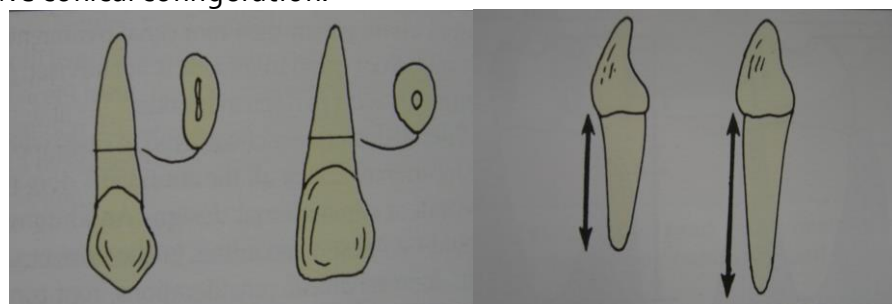
It is a linear measurement of the length of the crown (tooth) occlusal to the crest of alveolar bone.

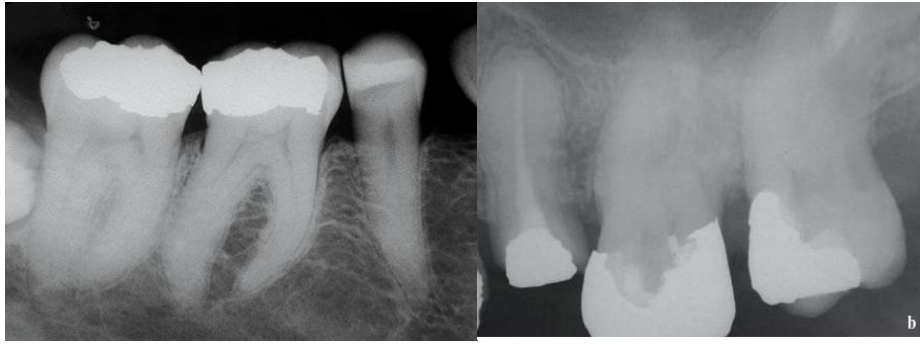- $2/3$ crown/root ratio is the optimum for a tooth to be used as abutment for F.P.D.
- Minimum acceptable ratio is 1:1 crown/root ratio
- Greater than 1:1 might considered adequate in some cases such as periodontally involved mobile teeth (opposing) or if the opposing occlusion is composed of artificial teeth, which reduce occlusal forces that acting on abutment ,this defiantly lead to less stress on abutment .



B. Root configuration; (Root shape , angulation& length)

- Roots that are broad labio-lingually than they are mesio-distally are preferable roots that have round or circular in cross section.
- Tooth with conical root can be used as abutment for short span bridge. A single rooted tooth with irregular configuration or with some curvature in the apical third of the root is preferable to the tooth that have perfect taper.
- Multirooted teeth generally provide greater stability than single-rooted teeth .
- A multi rooted posterior teeth with widely separated (diveragent) roots will offer better periodontal support than root that coverage, fuse, or have conical configuration.





C. Surface area of the roots:

- The area of periodontal ligament attachment of the root to the bone.
- It can be used as a measurement scale to determine the potency of abutment
- Tylman stated that ,two abutment teeth could support two pontics.
- Johnston et al improvised Tylman statement and proposed the famous Antes law

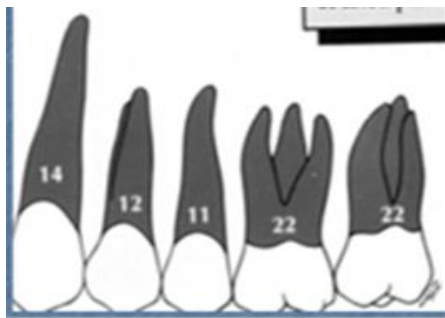


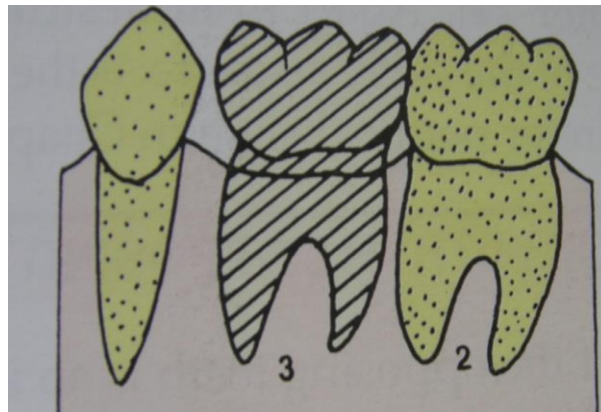
Table 3-1 ROOT SURFACE AREA OF ABUTMENT

	Root Surface Area (mm ²)	Percentage Root Surface Area in Quadrant
MAXILLARY		
Central	204	10
Lateral	179	9
Canine	271	14
First premolar	214	12
Second premolar	220	11
First molar	433	22
Second molar	431	22
MANDIBULAR		
Central	154	8
Lateral	168	9
Canine	268	15
First premolar	180	10
Second premolar	207	11
First molar	431	24
Second molar	426	23

Data from Jensen A: Root surface measurement and a method for a rapid determination of root surface area. Acta Odontol Scand 23:35, 1965.

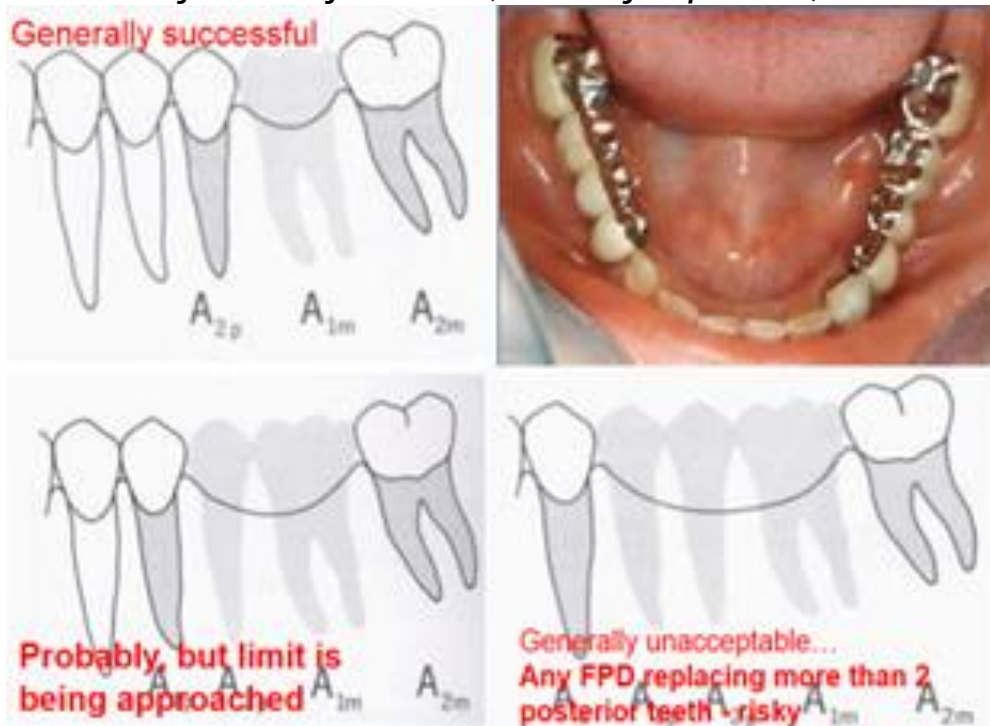
ANTE'S LAW:

The root surface area of the abutment teeth (*embedded in bone*) (*periodontal ligament area/pericemental area*) must be equal or more than root surface area of teeth being replaced.



Example:

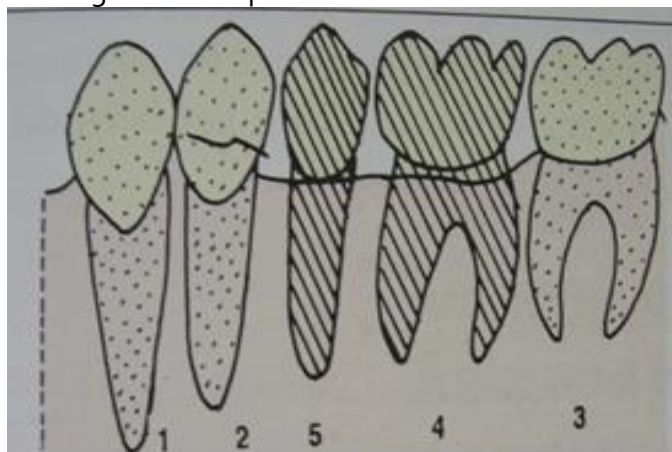
missing first molar alone or with second premolar, the root surface areas of both are equal to the root surface area of abutment (second & first premolar).



according to this premise :

One missing tooth can be successfully replaced if abutment teeth are healthy .

If two teeth are missing, a FPD can probably replace the missing teeth but the limit is being approached. In selected case and in order to increase the capability of the bridge to withstand the loading force first premolar can be used as a secondary abutment



If three missing posterior teeth (first molar and the two premolars) OR When the root surface area of the teeth to be replaced by pontics surpass that of the abutment teeth, then a high risk or an unacceptable situation for FPD exists.

BIOMECHANICAL CONSIDERATIONS OF FIXED PARTIAL DENTURE

SPAN LENGTH

Distance between abutments affects the feasibility of placing fixed prosthesis

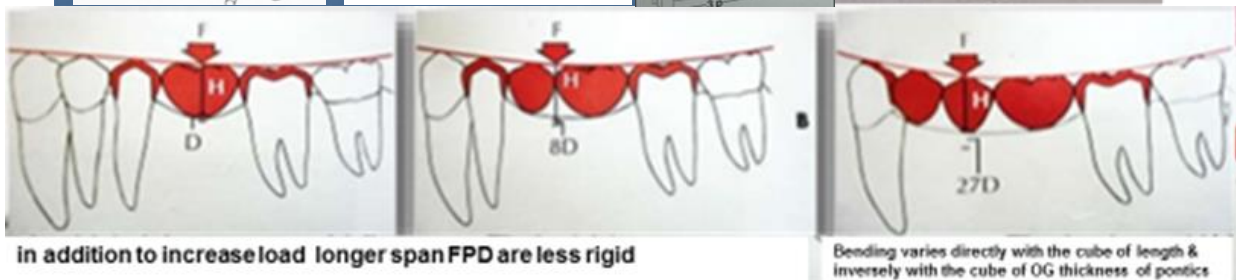
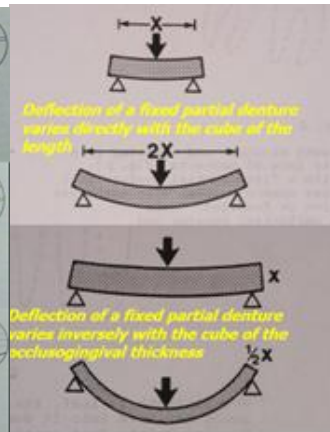
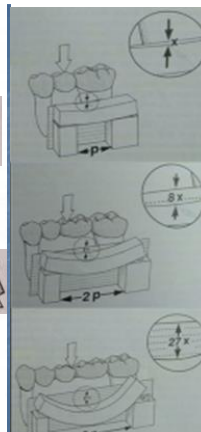
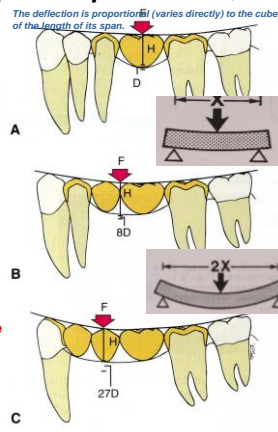
- Ideal for one missing teeth
- loss of 2-3 adjacent teeth requires careful evaluation of other factors (crown-root ratio, root length and form, periodontal health, mobility, occlusal force and biomechanical factor)

Biomechanical Considerations include the role of the edentulous span dimension, pontic characteristics, the connectors or joints of the f.p.d., abutment tooth and the acting force (masticatory) on the success of the constructed bridge. The dimension of the span (MD length and OG height) were found to influence the number of the selected abutments, the type of retainers and the material from which the bridge will be constructed. In addition to the increased load placed on FPD by long span restoration, longer span are less rigid,

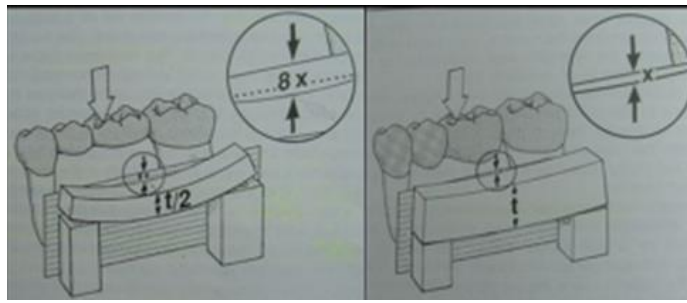
All F.P.D. flex slightly when subjected to a load, the longer the span, the greater the flexing. **It is not linear relationship but varies with the cube of the length of the span.** Thus if other factors being equal, if **a span of single pontic** is deflected in a certain amount, **a span of two** similar pontics will have **eight times** as much, **three pontics** may move **27 times** as much, **this mean replacing three missing posterior teeth with F.P.D. rarely has favorable prognosis, especially in the mandibular arch (Treatment with R.P.D. or implant supported prosthesis).**

Thus if other factors being equal, if a span of single pontic is deflected in a certain amount, a span of two similar pontics will have eight times as much, three pontics may move 27 times as much, this mean replacing three missing posterior teeth with F.P.D. rarely has unfavorable prognosis, especially in the mandibular arch (Treatment with R.P.D. or Implant supported prosthesis).

- Occlusal forces contact in a M-D direction on an FPD.
- Forces at an oblique angle or outside the center of the restoration cause F-L displacement.



Also the thickness of FPD play important role on amount of flexing, unlike the length, Deflection of a fixed partial denture **varies inversely with the cube of the occlusogingival thickness**, this mean that a pontic with a given occluso-gingival dimension will bend 8 times as much if the pontic thickness is halved.



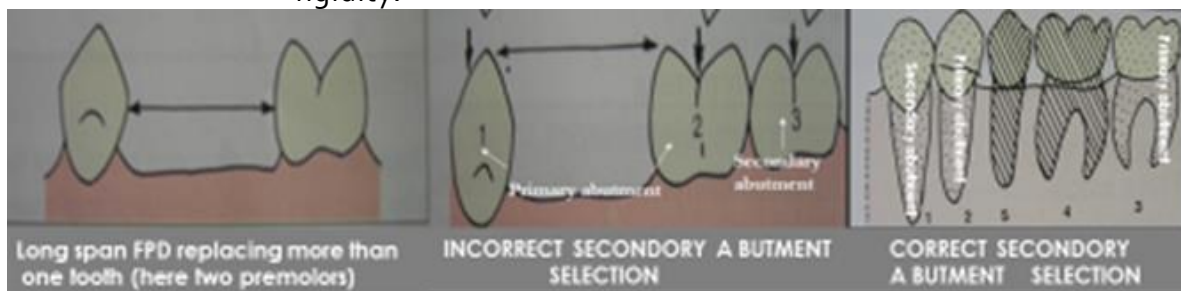
- **Excessive flexing under occlusal loads may cause failure of a long span F.P.D., It can tend to:**

- 1) Fracture of porcelain veneer
- 2) Connector breakage
- 3) Retainer loosening and caries
- 4) Unfavorable tooth or tissue response.

All these render prosthesis failure.

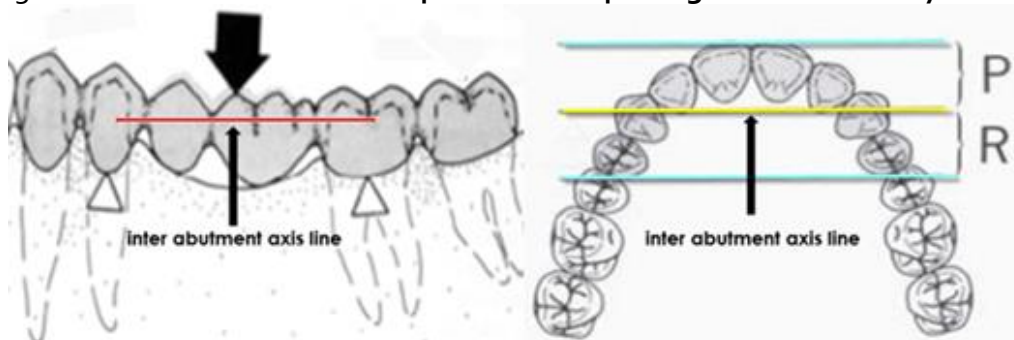
- **When long span F.P.D. fabricated:**

- 1) Using double abutments to enhance retention and support for long span FPD (anterior & posterior abutments should have nearly the same retention and resistance).
- 2) Pontics & connectors should be made as bulk as possible to ensure optimum rigidity without jeopardizing gingival health.
- 3) The prosthesis should be made of a material that has high strength & rigidity.



Arch curvature:

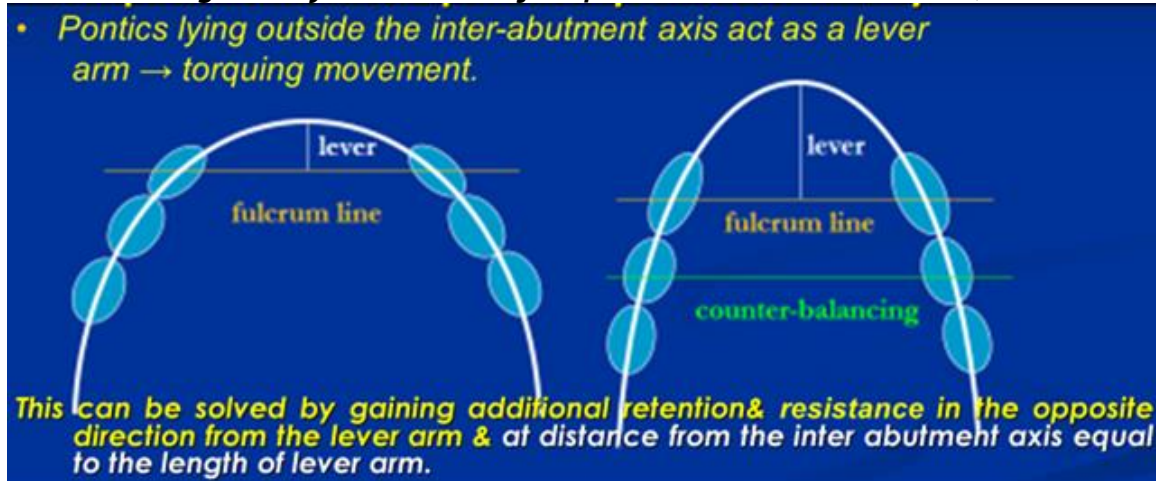
It imposes additional stress on F.P.D. It has effect on the stress occurring in F.P.D. when pontics lie outside the inter abutment axis line. The pontics act as lever arm, which produce a torquing movement. **This is common problem in replacing all four maxillary incisor .**



A common problem in replacing all four maxillary incisor with F.P.D. & most pronounced in the pointed taper arch anteriorly (the more the circular the arch curvature the less will be the problem). as seen in figure, the pontics lies outside the inter abutment axis line as result the pontics will act as lever arm that can produce torquing movement, the more the taper the arch the longer will be the lever arm and the more will be the stress or torquing force (forces directed against a maxillary incisor pontic will tend to tip the abutment teeth due to

curvature of the arch. To solve such problem and in order to offset the torque, additional retention is obtained in the opposite direction from the lever arm & at distance from the inter abutment axis equal to the length of lever arm, this mean, that **two abutment teeth at each end of long span anterior FPD** must be **used** in order to resist this tipping forces. This mean **first premolars** are **used** as **secondary abutments** for a maxillary four pontic canine-to-canine FPD.

Thus, in cases of **pointed taper arch anteriorly** when replacing four maxillary incisors, **the clinician should generally use canines & first premolars as abutment teeth**)



• **Pier (intermediate) abutment:**

An edentulous space can occur on both sides of a tooth creating a lone , free standing pier abutment. Shillingburg and Fisher (1973) – **forces are transmitted to the terminal retainers as a result of the middle abutment acting as a fulcrum causing failure of the weaker retainer. Because of these forces :-**

- The retainers or the casting will get loosened
- Leakage will be caused around the margin leading to extensive caries.

To overcome such complication, you can select one of the following approaches:

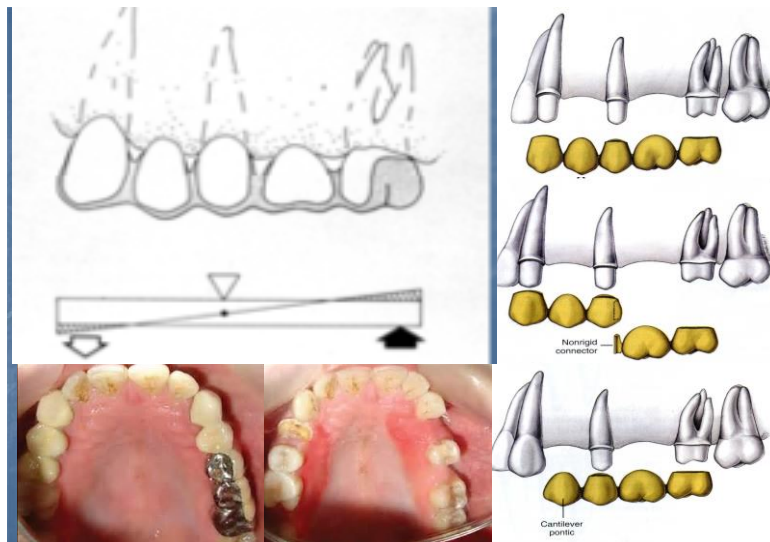
- 1) Such F.P.D. needs extremely retentive retainers.
- 2) Use of non-rigid connector.
- 3) When periodontal support is adequate, a much simpler approach would be to cantilever one segment of the bridge on one side of pier abutment.

Shillingburg and Fisher (1973) recommended the use of a **NON-RIGID CONNECTOR** to reduce this hazard .

- It is a broken stress mechanical union of retainer and pontic
- It transfers shear stress to supporting bone rather than concentrating it in the connectors.
- It appears to minimize mesiodistal torquing of the abutment, while permitting them to move independently
- most commonly used non-rigid design T-shaped key that is attached to the pontic & a dovetail keyway placed in the retainer

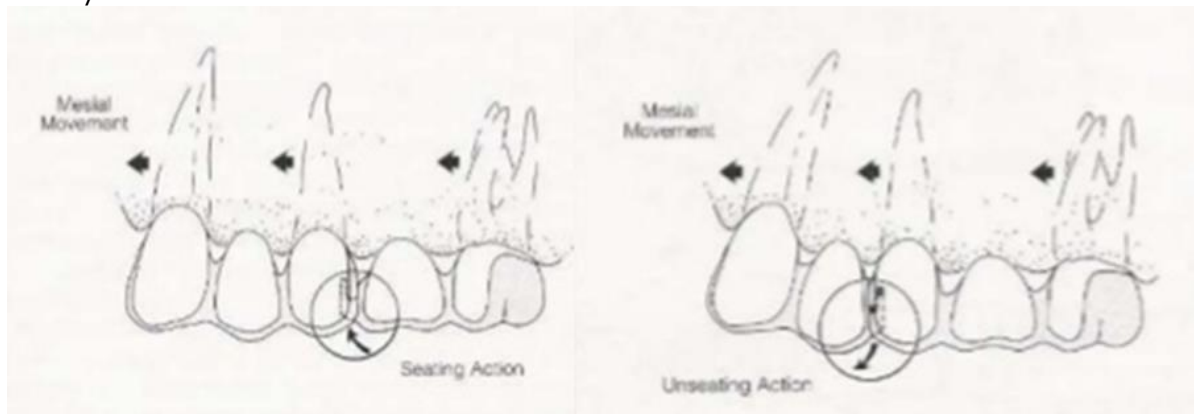
.Location of the key and key way:

- Should be placed in the middle abutment , placement on either of the terminal abutments can lead to pontic acting as a lever arm
- Keyway should be placed within the normal distal contours of pier abutment.
- Key should be placed on the mesial side of the distal pontic.



Why keyway should be placed on the distal not on mesial of pier abutment??????

Long axes of posterior teeth usually lean slightly in a mesial direction and about 98% posterior teeth tilt more mesially when subjected to occlusal forces. **Therefore, if keyway is placed on the distal of pier abutment**, then the mesial movement seats the key into the keyway more solidly. **If placement of the keyway is on the mesial side** then it causes the key to be unseated during the mesial movement which in time can cause a pathologic mobility in the canine or failure of the canine retainer.

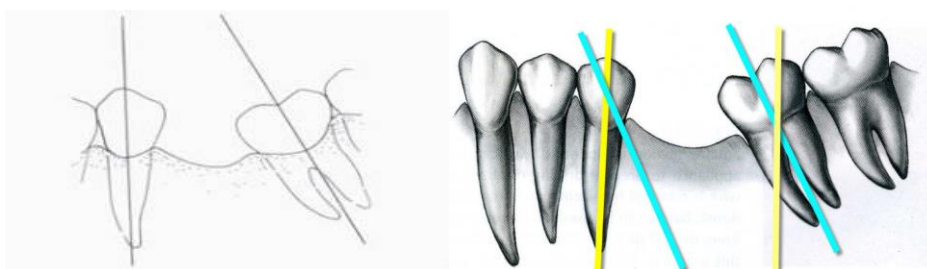


• **Tilted molar abutment:**

Tilted molar abutments / Mesially tilted second molars

Common problem occurs when the mandibular 2nd molar abutment gets tilted into the space formerly occupied by the first molar. Further complication occurs if the 3rd molar is present and has drifted and tilted with the second molar. In such case the mesial surface of the tipped third molar will encroach upon the path of insertion of the FPD.

Tilted second molar lead to difficulty or impossibility to make satisfactory F.P.D. because the positional relationship no longer allow for parallel path of insertion without interference with adjacent teeth.



To solve this problem:

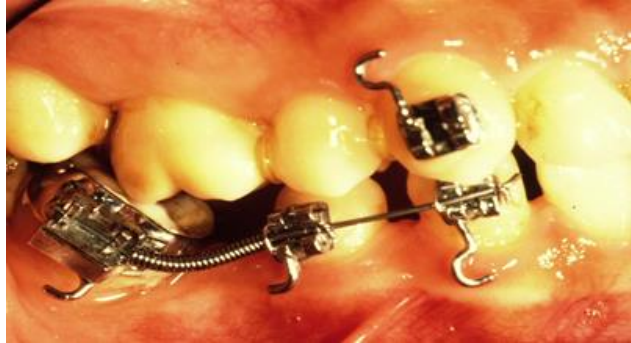1) Ortho treatment (up righting the tilted tooth)

If tilting is severe – uprighting of the molar by orthodontic treatment.

- also ,this mode of treatment helps in distribution of forces under occlusal loading and even helps to eliminate bony defects along the mesial surface of the root.

(usually 3rd molars if present are extracted to facilitate movement of 2nd molar).

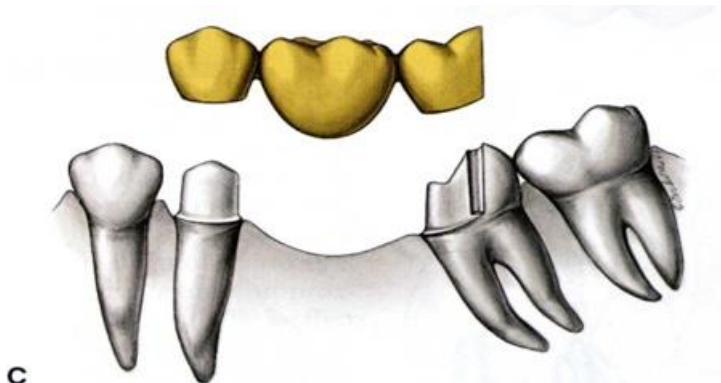
- Average treatment time – 3 months.



2) Using proximal half partial crown as a retainer on tilted molar abutment.

Proximal half crowns can be used as a retainer on distal abutment. this is simply a three –quarter crown that has been rotated 90 degrees so that the distal surface is uncovered. Possible only if

- the distal surface is caries free.
- the distal surface is not decalcified.
- there is a very low incidence of proximal caries throughout the mouth.
- the patient is able to keep the area exceptionally clean.

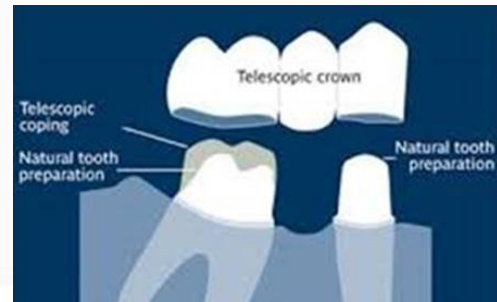
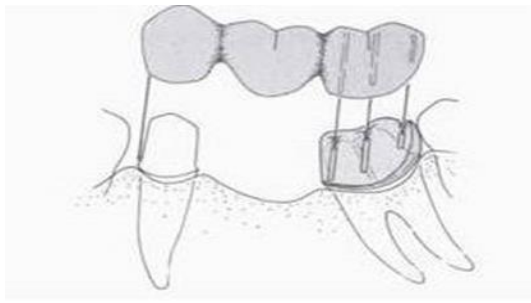


3) Using telescope crown and coping as retainer.

A telescope crown and coping can be used as a retainer on the distal abutment i.e. full crown preparation with heavy reduction is made to follow the long axis of tilted molar. An inner coping is made to fit the tooth preparation and a proximal half crown that will serve as a retainer for the FPD is fitted over the coping.

Advantages

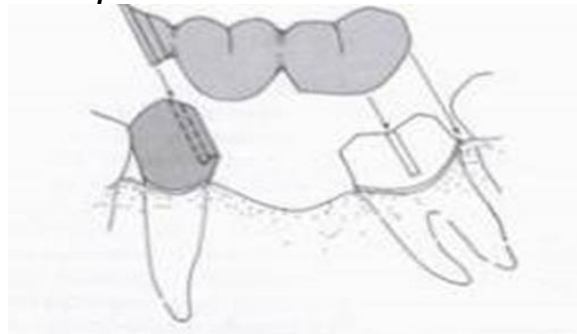
- allows total coverage of the clinical crown while.
- compensating for the discrepancy between the path of insertion of the abutments.
- the marginal adaptation is provided by the coping.



4) ***Non rigid connector is another solution to the problem.***

A full preparation is done on the molar with its path of insertion parallel with the long axis of the tilted tooth. A box form is placed on the distal surface of the premolar to accommodate a keyway in the distal aspect of the premolar. Reasons for NOT placing the non-rigid connector on the mesial aspect of the tipped molar is that it can lead to even greater tipping of the tooth. Uses – when molar exhibits marked lingual as well as mesial inclination because the routine FPD in such cases will lead to drastically overtapered preparation with no retention.

Because telescope crowns and non-rigid connectors both require tooth preparations that are more destructive than normal, the selection of one of these would be influenced by the nature of previous destruction of the prospective abutment tooth for e.g. – the presence of a dowel core or a D.O amalgam on the premolar would favor placement of a non-rigid connector- while extensive facial and / or lingual restorations on the tilted molar would call for the use of a telescope crown.



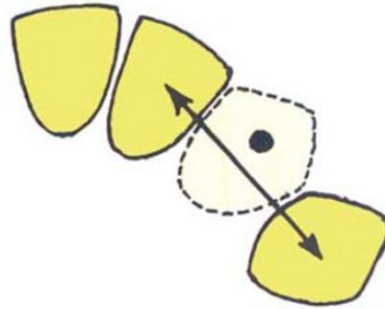
Evaluation of the path of insertion

Path of insertion should be checked before imprint. Parallelometer – mirror can be used for such purpose especially in difficult case or in experienced dentist, Parallelometer - mirror can easily spot the positional relationship of the prepared abutments

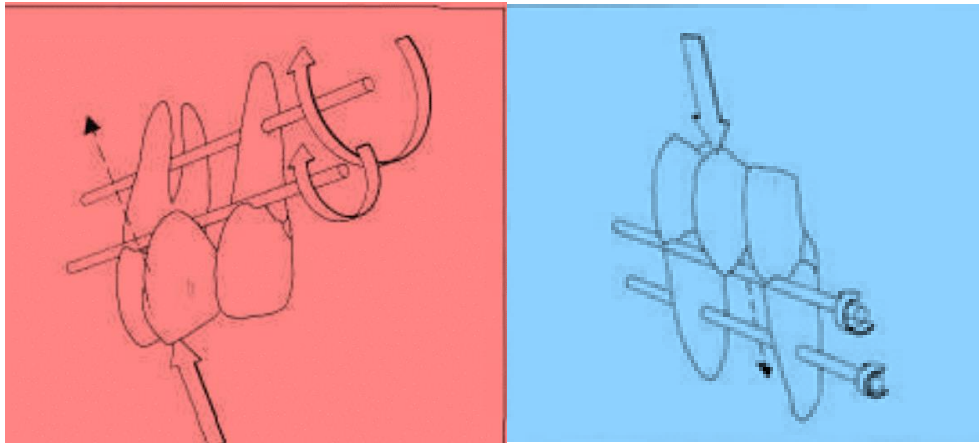


CANINE REPLACEMENT FIXED PARTIAL DENTURE

Fixed partial dentures replacing canines can be difficult because the canine often lies outside the interabutment axis. The prospective abutments are the lateral incisor, usually the weakest tooth in the entire arch, and the first premolar, the weakest posterior tooth.



A FPD replacing maxillary canine is subjected to more stress than that replacing a mandibular canine since forces are transmitted outward (labially) on the maxillary arch, against the inside of the curve (its weakest point), while, on the mandibular canine the forces are directed inward (lingually), against the outside of the curve (its strongest point)



So in cases of **CANINE REPLACEMENT FIXED PARTIAL DENTURE**, you should consider the following points

- Any fixed partial denture replacing a canine should be considered a complex fixed partial denture .
- No fixed partial denture replacing a canine should replace more than one additional tooth. (the support from secondary abutments will have to be considered)
- An edentulous space created by the loss of a canine and any two contiguous teeth is best restored with Implants or a removable partial denture.