

Operative Dentistry

د. احمد حامد علي

Lecture (5)

CARIES DETECTION AND DIAGNOSIS

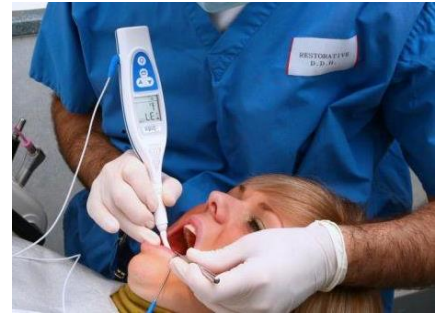Detection of carious lesions must be done while the teeth are clean & dry:

- 1. Pit & fissure lesions:** detection of these lesions most often done by visual inspection. Good lightening & dry clean teeth. It appears that any sign of visible cavitations in the occlusal surface corresponds to the progression of the lesion into the dentin. Bite-wing radiographs can detect only large occlusal lesions. Tactile examination of fissures with sharp probe is unreliable method because the explorer can damage a white spot lesion by breaking through intact surface zone & cause a cavity which will trap dental plaque & encourage lesion progression.
- 2. Lesions involving proximal surfaces:**
 - Bitewing radiographs are the most effective method for evaluation of the proximal smooth surfaces for evidence of demineralization because these areas are not readily assessed visually or tactilely.
 - Fiberoptic transillumination techniques have proven useful. In these techniques, a fine light is transmitted through the contact area. Lesions appear as a dark shadow.
 - The use of orthodontic separator has been advocated in some cases to allow the dentist to see more clearly & gently feel for a break in the enamel surfaces.
- 3. Lesions in smooth free surfaces:** lesions in smooth free surfaces whether in the enamel of the crown or the dentin of the root can be detected easily with visual examination.
- 4. Root surfaces:** Root surfaces exposed to the oral environment, usually due to gingival recession, are at risk for caries and should be examined visually and tactilely. Discoloration of such areas is common and usually is associated with remineralization. Generally, the darker the discoloration, the greater the remineralization. On the other hand, active, progressing caries shows little discoloration and is primarily detected by the presence of softness and cavitations.

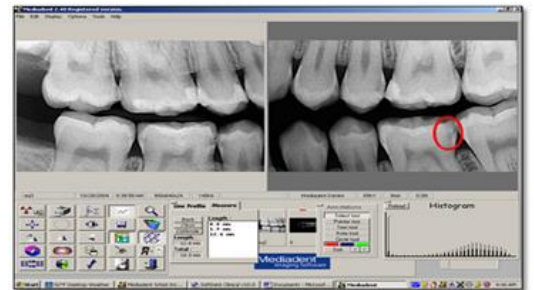
New Caries Detection Devices

The development of several new devices and detection methods is promising.

1. **Electronic caries monitors** are based on the principle that porous carious lesions have lower conductive values than intact tooth structure (for example: CarieScan system).

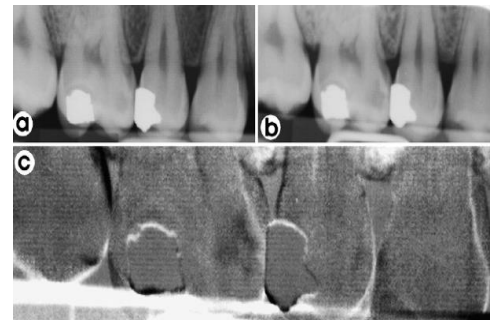


2. **Direct digital radiographs** for caries detection. This systems use a wire-based sensor that contains a computer chip inside a protective casing, the sensor is connected to a PC by wire. The sensor is placed in the patient's mouth, when this sensor hit by x-ray the information is transmitted directly to the computer and displayed as an x-ray image on the computer screen.



Subtraction radiography

Used for detection of recurrent caries. The basis of subtraction radiology is that two radiographs of the same object can be compared using their pixel values. any differences in the pixel values must be due to change in the object.



3. **Intra-Oral camera** for caries detection and for patient motivation.
4. **Magnification using Loupes, and Dental Microscope.**

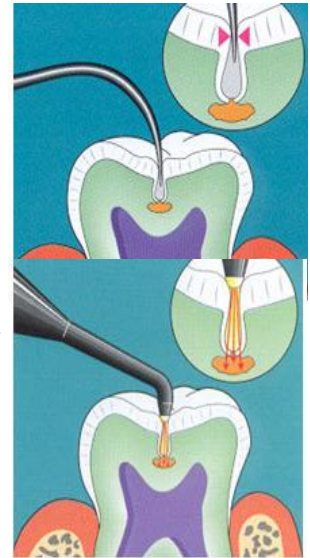
5. Infrared Laser Fluorescence (DIAGNOdent)

It can be used for detection of caries on occlusal and smooth surfaces.

The principle is that cariogenic bacterial metabolites exhibit increased fluorescence causing change in the fluorescence of the lesion.

The **higher** the number the more is the caries

Advantage: the most useful in confirming the presence of caries in suspicious fissure and detecting deep dental caries (hidden caries). However, it is not used for the detection recurrent caries or to detect proximal caries.

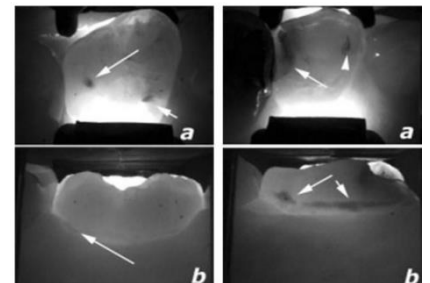


6. Fiber-optic transillumination

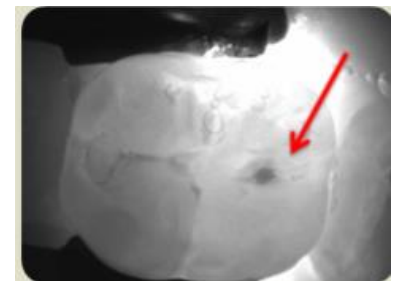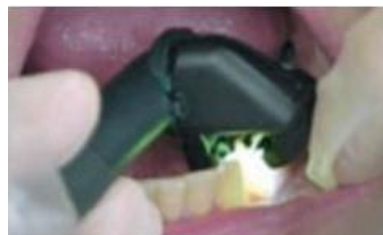Fiber-optic transillumination (FOTI) as a caries detection technique is based on the fact that carious enamel has a lower index of light transmission than sound enamel. The intact tooth absorbs very little light allowing it free passage. In contrast areas of caries absorb and scatter light thus appear as dark shadow. This method is mainly used to determine proximal caries

Advantages: 1. Lesions which cannot be diagnosed radiographically can be diagnosed, 2. No radiation hazard, 3. Comfortable to the patient.

Disadvantages: 1. FOTI is not possible in all locations of carious lesions, 2. can not detect small lesions



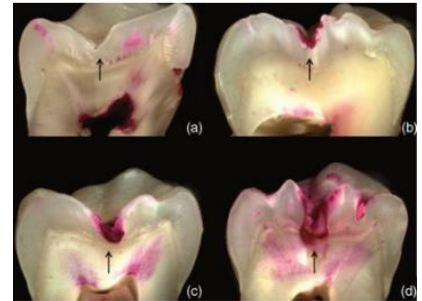
CariVu is a brilliant new approach to caries detection combining FOTI with a digital camera



7. Caries detector dyes

Various dyes such as silver nitrate, methyl red have been used to detect carious sites by change of color.

These dyes aid the dentist in differentiation of infected dentin. These dyes enhance the visual recognition of caries by selectively staining the infected demineralized dentin which should be removed during preparation leaving the inner affected dentine (demineralized but not infected) that should be kept and not removed because it could be remineralized.



Caries Prevention and Treatment

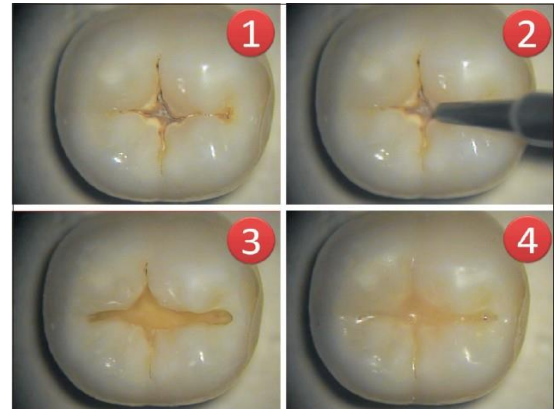
Caries preventive treatment is a complex process involving multiple interrelated factors. Maintaining of good oral hygiene “brushing and flossing”, diet containing sucrose and carbohydrate control, and fluoride treatment; all these factors can affect carious lesion initiation and also remineralization of the incipient carious lesion specially in smooth surfaces to arrested carious lesions. Pit and fissure sealant is the most effective method in preventing pit and fissure caries.

Once caries has produced cavitation of the tooth surface, preventive measures are usually inadequate to prevent further progression of caries. So, cavity preparation and restoration are needed. Once the pulp is dead partially or completely; root canal filling become necessary to avoid tooth extraction.

	Active	Arrested
Occlusal lesion	<p>-Frosted surface, plaque covered white spot lesion.</p> <p>-cavitated lesion; include micro cavities to cavities involving dentine which is visible on bitewing radiograph.</p>	-shiny surface white or brown spot lesion
proximal	<p>-appear on radiograph</p> <p>-appear on radiograph with persistent gingival inflammation despite pt. attempt to remove plaque by flossing.</p> <p>-lesion not presents at previous examination.</p>	-accurate bitewing radiograph shows no lesion progression.
Smooth surface	<p>-white spot lesion close to gingival margin that may have frosted, plaque covered surface</p> <p>-cavitated, plaque covered lesion with or without exposed dentine, if dentine is exposed & soft dentine is heavily infected.</p>	<p>- shiny surface white or brown lesion & lesions are not plaque covered.</p> <p>- cavitated lesion; dark brown & hard dentine at their base, are not plaque covered & away from gingival margin.</p>
Root surface lesion	<p>- close to gingival margin, plaque covered.</p> <p>-soft or leathery consistency</p>	<p>- far from gingival margin, not plaque covered.</p> <p>-as hard as surrounding healthy root surface.</p>

New Technologies for Caries Removal and Cavity Preparation (Minimal Invasive Dentistry)

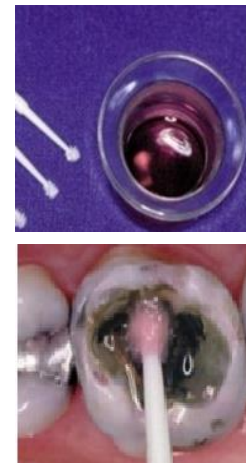
- 1. Air abrasion:** air abrasion removes tooth structure using a steam of aluminum oxide particles generated from compressed air. The abrasive particles strike the tooth with high-velocity and remove small amount of tooth structure.



Clinical application of air abrasion includes:

- Detection of pit and fissure caries.
- Removal of superficial enamel defects.
- Cleaning fissures and surface preparation for sealant preventive resin restoration.
- Small class I and V preparation.

- 2. Chemo mechanical method:** this method involves the application of an isotonic solution on tooth tissue, softening the caries and facilitating its removal using specially design hand instrument. This reduces the removal of sound tooth structure, the cutting of open dentinal tubules, pulpal irritation and pain compared with conventional mechanical method. (For example: Cariosolv gel system).



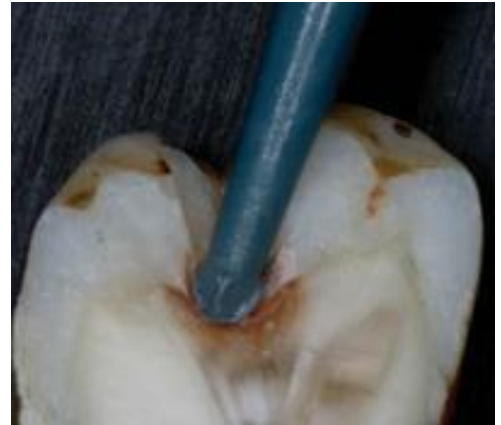- 3. Laser devices:** laser devices that are capable of cutting dental hard tissues effectively and can be used for operative procedures, e.g. Er:YAG laser device, and laser-powered hydrokinetic system (LPHKS).



4. Smart bur (Smartprep)

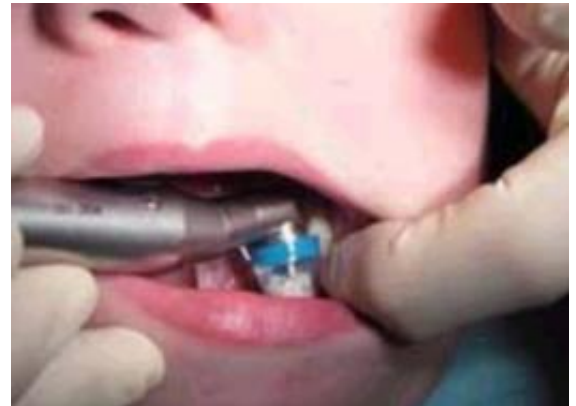The Smartprep bur is a polymer that safely and effectively remove decayed dentin, leaving healthy dentin intact.

The polymer instrument is self-limiting and will not cut sound dentin unless applied with great force, and then it will only wear away, rather than cut the healthy dentin. The self-limiting polymer is unlikely to mechanically expose dentinal tubules and unlikely to cause patient discomfort. In many cases, no local anesthesia is required for patient comfort.



5. Ozone treatment

The ozone delivery system is a device that takes in air and produces ozone gas. The ozone is then delivered via a hose into a disposable sterile cup. The ozone gas is refreshed in this disposable cup at a rate of 615 cc/minute changing the volume of gas inside the cup over 300 times every second. The cup forms a seal around the lesion being treated so that ozone cannot leak into the oral cavity.



Around 20-40 seconds of ozone application have been shown to penetrate through carious dentin to eliminate any live bacteria, fungi, and viral contamination. This treatment eliminates cariogenic organisms as well as priming the tissues for remineralization.