

## Diagnostic Aids

### 1-Study Models:

#### INTRODUCTION

Orthodontic study models are essential diagnostic records, which help to study the occlusion and dentition from all three dimensions. They are accurate plaster reproductions of the teeth and their surrounding soft tissues.

#### IDEAL REQUIREMENTS OF ORTHODONTIC STUDY MODELS

1. Models should accurately reproduce the teeth and their surrounding soft tissues.
2. Models are to be trimmed so that they are symmetrical and pleasing to the eye and so that an asymmetrical arch form can be readily recognized.
3. Models are to be trimmed in such a way that the dental occlusion shows by setting the models on their backs.
4. Models are to be trimmed such that they replicate the measurements and angles proposed for trimming them.
5. Models are to have clean, smooth, bubble-free surfaces with sharp angles where the cuts meet.
6. The finished models should have a glossy mar-proof finish.

#### WHY WE MAKE STUDY MODELS?

1. They are invaluable alone in planning treatment, as they are the only three dimensional records of the patient's dentition.
2. Occlusion can be visualized from the lingual aspect.
3. They provide a permanent record of the intermaxillary relationships and the occlusion at the start of therapy; this is necessary for medicolegal considerations.
4. They are a visual aid for the dentist as he monitors changes taking place during tooth movement.
5. Help motivate the patient, as the patient can visualize the treatment progress.

6. They are needed for comparison at the end of treatment and act as a reference for post-treatment changes.
7. They serve as a reminder for the parent and the patient of the condition present at the start of treatment.
8. In case the patient has to be transferred to another clinician, study models are an important record.

### USES OF STUDY MODELS

1. Assess and record dental anatomy
2. Assess and record intercuspation
3. Assess and record arch form
4. Assess and record the curves of occlusion
5. Evaluate occlusion with the aid of articulators
6. Measure progress during treatment
7. Detect abnormality, e.g. localized enlargements, distortion of arch form, etc.
8. Calculate total space requirements/discrepancies
9. Provide record before, immediately, after and several years following treatment for the purpose of studying treatment procedures and stability.

### PARTS OF THE STUDY MODELS

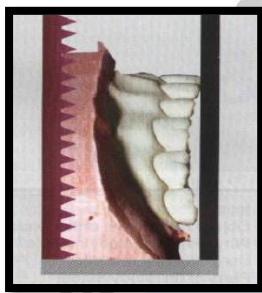
The study models can be divided into two parts for the purpose of description:

- The anatomic portion
- The artistic portion
- The anatomic portion is that part which is the actual impression of the dental arch and its surrounding soft tissue structures. This is the part, which must be preserved when trimming the model.
- The artistic portion is the stone base supporting the anatomic portion. This portion is trimmed in a manner, which depicts, in a general way, the dental arch form and is pleasing to the eye.

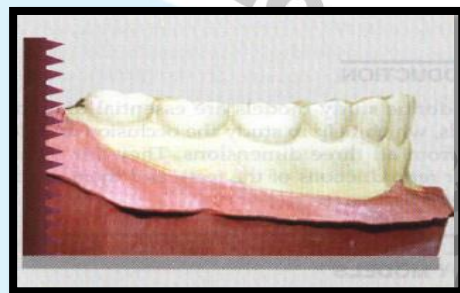## STUDY MODEL FABRICATION AND TRIMMING

Preliminary procedures in the fabrication of study models are:

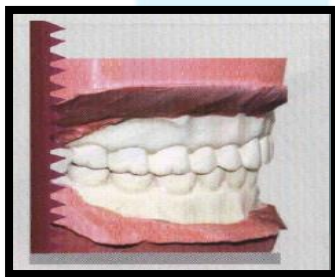
1. Remove any excess flash or obviously excessive bulk on the periphery of the models
2. Remove any nodules that may be present on the occluding surfaces of the teeth
3. Remove any extensions in the posterior areas that prevent occluding of the models
4. Using the wax bite, occlude the models.



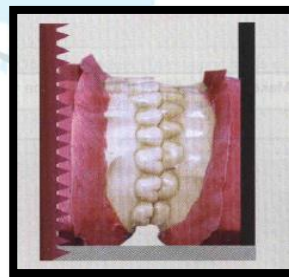
1- Trim lower base parallel to occlusal plane



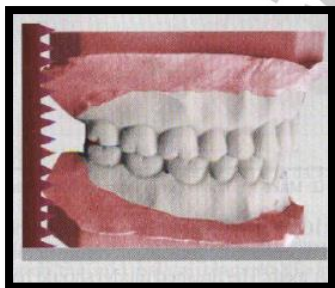
2- Trim lower back perpendicular to base



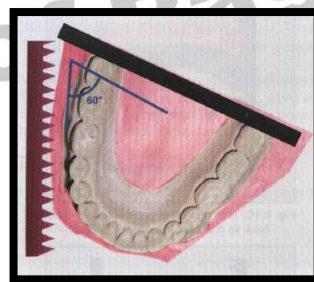
3- With models in occlusion, trim upper back so it is flush with the lower back



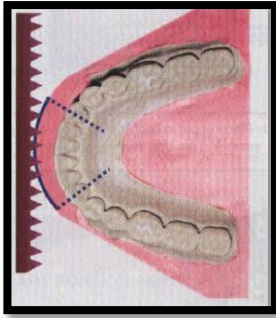
4- Place upper model (on its back) on the model trimmer. Trim until the top base is flat



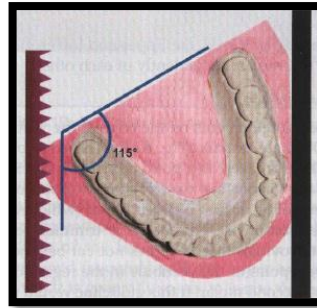
5- Occlude models. Check bases for parallelism, backs for flush plane



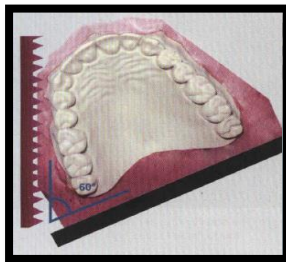
6- Make buccal cuts, at the edge of the vestibule 60° to the base of the model



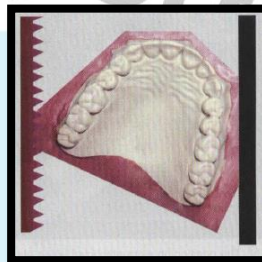7- Make a smooth curve from canine to canine  
In lower models



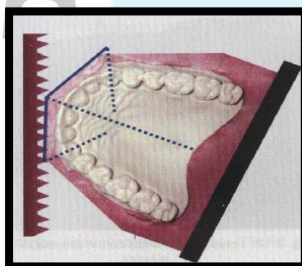
8- Move model trimmer guide to its extreme  
Position to make the heel



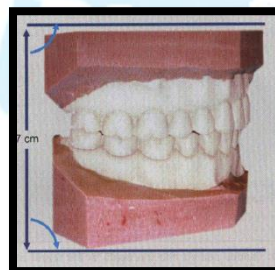
9- Make buccal cuts. at the edge of the  
vestibule 60° to back of the upper model



10- Occlude models. Trim upper heels so they are  
flush with lower heels



11- Make anterior cuts. the ends of which should  
be at the midline and the middle of each canine



12- Occluded models should have a sharp  
90° angle between their base and back

### Finishing the Models

1-The surface must be made smooth, remaining at the same time absolutely flat and at right angles to the bases of the models.

2-The finishing process should not change the dimensions or any of the angulations of the models.

3- After the surfaces have been finished, and the exact dimensions achieved, the model is set aside to dry for 48 hours or dried overnight in an orthodontic oven.

4- At this point the model should be labeled with the patient's name and date on the backs of both the upper and lower models.

5-The final glazing is put on the models by immersing them in a commercial gloss. The models are allowed to remain in this solution for one-half hour.

6-Holding each arch under cold water, the models are polished and soap solution removed by buffing with cotton.

7-The models are set on their occlusal surfaces to dry for another twelve hours, then buffed with a very light but rapid motion using cotton. The models should assume a high, even luster which will then resist soiling while handling.

#### **Handling of the study models:**

The models should be placed on a flat surface with their backs down. They should be picked up together and always returned together. Individual handling of the models is more likely to result in damage to the models.

## **2- FACIAL PHOTOGRAPHS:**

Facial photographs are the easiest to store, occupy the least amount of space and provide immense information to the clinician as well as the patient.

Photographs can be,

- Extraoral photographs
- Intraoral photographs

### **EXTRAORAL PHOTOGRAPHS**

Extra-oral photographs are considered essential records and should be taken **before** starting treatment **and after** completion of treatment.

#### **Uses of extra-oral photographs**

1. Evaluation of craniofacial relationships and proportions before and after treatment.

2. Legal point of view.
3. Assessment of soft tissue profile
4. Proportional facial analysis and/or photographic analysis
5. Important for conducting the Total space analysis
6. Monitoring of treatment progress (if standardized)
7. Invaluable for longitudinal study of treatment and post retention follow-up
8. Detection and recording muscle imbalances
9. Detecting and recording facial asymmetry
10. Identifying patients

**American Board of Orthodontics has laid down guidelines for these extra-oral photographs**


- Quality, standardized facial photographs either blackened white or color prints.
- Patients head oriented accurately in all three planes of space and in FH plane
- One lateral view, facing right, serious expression, lips closed lightly to reveal muscle imbalance and disharmony.
- Background free of distractions
- Quality lightening revealing facial contours with no shadows in the background
- Ears exposed for purpose of orientation
- Eyes open and looking straight ahead, glasses removed.

It is recommended that at least three extra-oral photographs be taken for all patients. This includes:

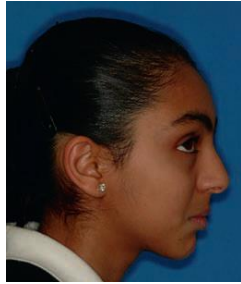
A-Frontal facial with lips relaxed

B-Facial profile with lips relaxed

C - Three-quarter view, smiling or D- Frontal facial, smiling.



A



B



C



D

For facial deformity cases or cases likely to undergo orthognathic correction it is recommended that all the four photographs mentioned above should be complemented with the following:

- 1- Frontal facial in maximum intercuspal position, lips sealed
- 2-Left and right, facial profile in maximum intercuspation, lips sealed
- 3-Left and right, facial profile, lips relaxed
- 4-Left and right three-quarter view, smiling or frontal facial, smiling.

All extraoral photographs should be taken in the natural head position, preferably without any shadows appearing in the background. The ears should be exposed (for the purpose of orientation) and the patient should not be wearing eye ware.

It would be ideal if the distance and magnification could be standardized.

### **INTRAORAL PHOTOGRAPHS**

Intraoral photographs are considered non-essential diagnostic records yet they are simple to take, maintain and store and of course useful, this is because they are neither standardized nor three dimensional.

Must be taken before ,during and after finishing the treatment.

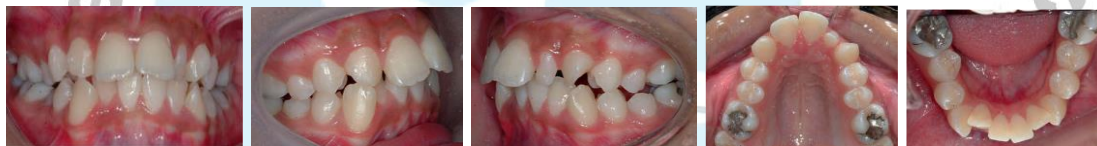#### **These are used for:**

- 1- Helpful in explaining and motivating the patient.
- 2- They are also used to monitor treatment progress and results.
- 3- They are also helpful in medicolegal cases involving the texture and color of teeth especially pre-operatively.

- 4- Assessing and recording health or disease of the teeth and soft tissue structures.
- 5- Study of relationships before, immediately following and several years after treatment, to improve treatment planning.

The American board of orthodontist's guidelines for intraoral photographs

1. Quality, standardized intraoral color prints
2. Photographs should be oriented accurately in all three planes of the space
3. One frontal photograph in maximum intercuspation (A)
4. Two lateral views-right (B) and left (C)
5. Optional-two occlusal views-maxillary (D) and mandibular (E)



A

B

C

D

E

6. Free of distractions-retractors, labels etc.
7. Quality lightening revealing anatomical contours and free of shadows
8. Tongue should be retracted posteriorly
9. Free of saliva and/or bubbles
10. Clean dentition