

ESTHETICS CONSIDERATIONS IN COMPLETE DENTURE

Esthetics: 1. the branch of philosophy dealing with beauty; 2. in dentistry, the theory and philosophy that deal with beauty and the beautiful, especially with respect to the appearance of a dental restoration, as achieved through its form and/or color; those subjective and objective elements and principles underlying the beauty and attractiveness of an object, design, or principle.

Dental esthetics: the application of the principles of esthetics to the natural or artificial teeth and restorations

Denture esthetics: the effect produced by a dental prosthesis that affects the beauty, attractiveness, character, and dignity of an individual. It is a combination of art and science of prosthodontics.

“An international comparative multicenter study of assessment of dental appearance using computer-aided image manipulation”



They concluded that there is often a difference of opinion concerning aesthetics among dentists and technicians on one hand, and patients on the other. For example, patients very often desire whiter teeth than those proposed.

Factors Influencing the Appearance of Dentures:

- ✓ Patient factors
- ✓ Tooth factors
- ✓ Denture base factors
- ✓ Tooth/Denture base factors

Patient Factors

1. Sex
2. Age
3. Personality

Types of Tooth Positioning

1. Personality
2. Horizontally
3. Individual

Tooth Factors

1. Position
2. Color
3. Size
4. Form.

Steps in achieving esthetic complete denture:

1. An accurate impression
2. Jaw relation
3. Selection of teeth
4. Arrangement of teeth
5. Characterization

1- An accurate impression

Thickness of labial flange of both dentures, this is accomplished at the impression phase of treatment, so that the esthetics as well as retention and stability are important goals. Border thickness should vary with the needs of the patient, depending on the extent of residual ridge loss. The vestibular fornix should be filled, but not overfilled, to restore facial contour.

2- jaw relation

Amount of separation between maxilla and mandible, this is establishment of the correct vertical dimension of occlusion; proper vertical dimension of occlusion helps restore normal physiological length to muscles and allows normal facial expression. Reestablishing the appropriate vertical spacing will improve the patient's appearance by decreasing the sunken and aging appearance. This vertical space must be not only esthetically pleasing but also compatible with the typical mandibular joint apparatus, including the muscles of mastication.

3. Selection of teeth:

Teeth selection is very important as the selection of the appropriate shade, size, and form of the artificial teeth determines the esthetic and function of the denture.

Objective of tooth selection:

1. Function efficiently
2. Normal speech
3. Aesthetically pleasing
4. No tissue abuse
5. Should maintain the vertical dimension.

Anterior teeth selection: Anterior teeth selected primarily to satisfy esthetic while posterior selected for function.

Guides for anterior teeth size:

Pre-extraction records:

Diagnostic cast, photograph, radiograph, extracted teeth and previous denture.

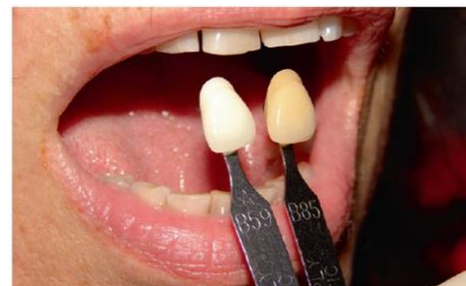Post extraction record:

1. Central incisors restore philtrum if possible.
2. Central incisors restore vermilion border.
3. Incisal points and smile line determine height of tooth (age-related).
4. Position of canine points
 - A. Relate to inter-alar width (smiling).
 - B. Relate to pupils (require pre-extraction photograph).
5. If patient is already a denture wearer, the mouth should be examined with the dentures in the mouth giving importance to physiological and esthetic aspects.

Factors of selection of anterior teeth:

1. Color

Show your patients a complete shade guide and select the two lightest and darkest tabs. Point out how different these two are and find out which

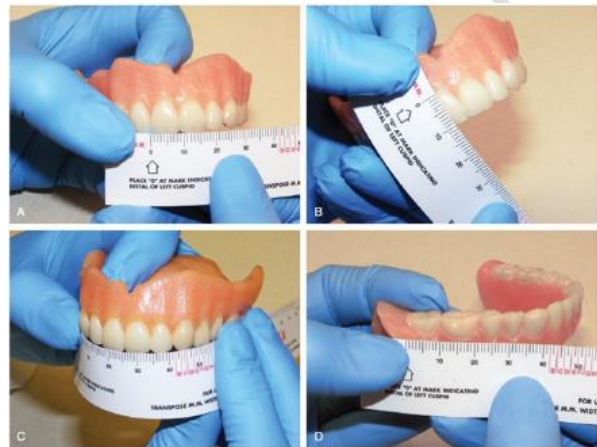

one they prefer. Delete the rejected color, and select another shade from the preferred half of the shade guide. Repeat this pair comparison, and after two or three selections by your patients, you will have the shades that they want. Note the selections used in your file.

2. Size: Depend on:

- a) Existing dentures.
- b) Models of previous teeth.
- c) Photograph

All of above give valuable input for selection of the size and shape of teeth. Teeth can be measured in millimeters and teeth of similar size selected coupled with actual measurement, again use a method of pair comparison to assist patients to decide what size of tooth they prefer.

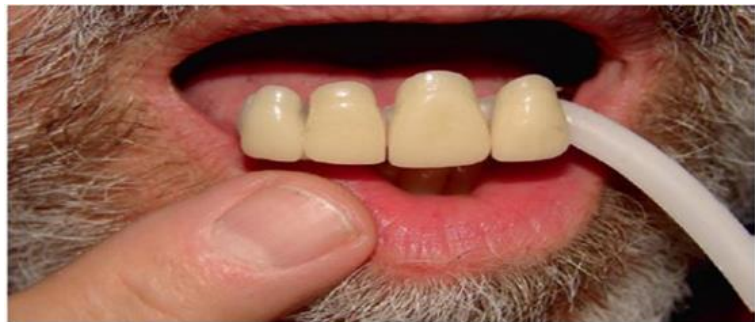

Factors that influence the size of anterior teeth are:

1. Size of the face.
2. Amount of available interarch space.
3. Measured distance between distal of right and left maxillary cuspids.
4. Length of the lip.
5. Size and relation of arches.

3. Mold

select and agree on the *mold* of the teeth. Teeth of a similar size can appear entirely different because of their taper, contacts, and labial curvature. Allow your patient to select between molds of the same size but



different shapes. Set two different molds on the right and left sides of a piece of wax rope and ask patients which they prefer.

There is a choice of mold: square, tapering or ovoid. In general terms, square molds suit patients with large, rugged features. Long and narrow faces may be best suited to tapering molds, whereas ovoid molds tend to suit patients with small, round faces.

Form of the Anterior Teeth

The form or outline of the anterior teeth can be determined using the following factors:

1. Shape of the patient's face or facial form (previously mentioned)
2. SPA factors (sex, personality, age.)

Sex:

The form or shape of the teeth differs in males and females. The differences in the shape of the anterior teeth in males and females are:

- In females, the incisal angles are more rounded and the teeth have a lesser angulation. In males, the incisal angles are rounded to a lesser degree and the teeth are more angular
- The incisal edge of the central incisors is parallel to the lips and the laterals are above the occlusal plane in males. But the incisal edges of the central and lateral incisors follow the curve of the lower lip in females.
- The distal surface of the centrals is rotated posteriorly for females.
- The mesial surface of the lateral incisors is rotated anteriorly in relation to the centrals in females
- In males the mesial end of the laterals is hidden by the centrals. This makes the canine very prominent in males
- Only the mesial thirds of the canines are visible in females because they are rotated anteriorly whereas even the middle two-thirds of the canines are visible in males.
- The cervical regions are prominent in males than in females.
- Females on smiling expose more anterior teeth hence, the premolars should be arranged based on aesthetics for females.

Age:

The age of the patient is important in teeth selection because of the physiological and functional changes that occur in the oral tissues. The patient can be either young,

middle-aged or old-aged. The following changes are observed with an advance in age of the patient:

- Due to decrease in muscle tone, sagging of the cheeks and the lower lips occur. To prevent cheek biting (due to sagging), the horizontal overlap of the posterior teeth can be increased.
- Inter-occlusal distance reduces with age. Hence, mandibular teeth are more visible than the maxillary teeth.
- Old people usually have abraded teeth with worn out contacts. Hence, placement of contoured teeth may look artificial.
- Old patients have gingival recession. It can be reproduced in the dentures to provide a natural appearance.
- Old people show a blunt smile line and pathologic migration of teeth.
- The color of the teeth also changes with age. In old people, the enamel is abraded and the dentine which carries a yellow tinge, is more visible.

Additional clinical and technical considerations in anterior tooth selection patient preferences

A high smile line that displays a lot of gingiva would benefit from the selection of a less tapered mold with a long contact point. This minimizes the interproximal display of pink gingival acrylic, which is more difficult to make look more realistic than teeth. The resultant smile ends up being slightly more dental but with a less gingival display.

Arrangement of teeth

The goals of tooth arrangement are

1. To have the front teeth look good.
2. allow the patient to speak clearly.

have all the teeth positioned for the best comfort, stability and retention of the dentures.

Position of the Teeth

The amount of tooth showing, orientation of the occlusal plane, and labiolingual inclination all have an influence on aesthetics. If the level of the occlusal plane is set too low, or if the anterior teeth are set on a flat plane, then the teeth will be too

visible. This will be emphasized when the patient smiles, as the teeth will not follow the smile line of the lip. The orientation will also have an influence, and if is not approximately parallel to the interpupillary line, then the smile will look crooked. The center line of the teeth is also critical, as this will have a negative effect on appearance if it is not coincident with the center line of the face. The labial frenum should not be used to guide positioning of the center line, as this is often not in the center of the face. The labiolingual position of the anterior teeth, in particular of the necks of the teeth, is critical in terms of lip support. A common misconception is that lip support is reliant on the shape of the labial flange of the denture. However, if the flange is thickened, then this will cause bulking out beneath the nose similar to a gum shield. If teeth are moved away from the crest of the ridge, then this will cause instability of the denture. Setting teeth directly over the crest of the ridge with an upright inclination will not provide adequate lip support. As previously discussed, the use of biometric guides to place the teeth where the natural teeth used to be can improve aesthetics dramatically. A further possibility is to place the necks of the teeth close to the alveolar ridge and tilt the incisal edges of the teeth labially. This will improve the lip support and is less likely to be unstable than when using biometric guides.

Arrangement of teeth with esthetics consideration

The clinician should attempt to create the illusion of natural teeth when finalizing the appearance. It should be remembered that the prevalence of irregularity or crowding of natural teeth is high. Therefore, if dentures are constructed with a 'perfect' arrangement, the risk of the resulting appearance seeming artificial is considerable.

As a general rule, imperfection in the anterior tooth arrangement is a basic requirement in creating the illusion of natural teeth. Complete symmetry should be avoided: for example, the anterior teeth should not be placed so that the incisal edges are all at the same level.

The vertical axes of the anterior teeth can be varied, but if the inclination of these axes on one side of the mouth does not approximately balance that on the other, an unsatisfactory appearance will result.

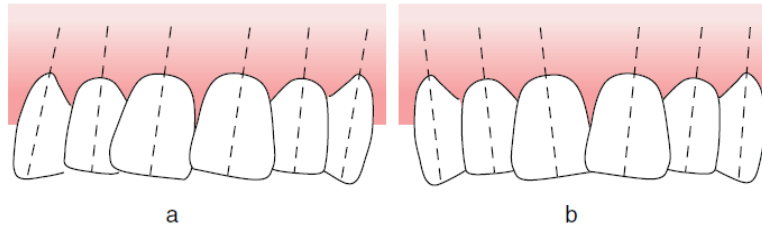
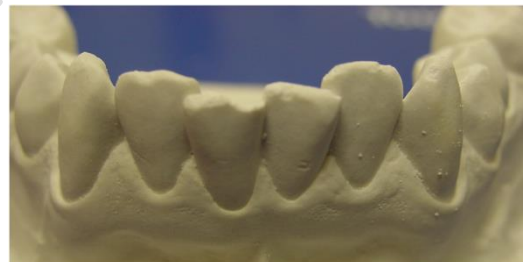

Figure 13.4 (a) Imbalance produced by inclining the vertical axes of the anterior teeth in the same direction. (b) The improvement in appearance produced by counterbalancing the inclination of the axes on one side of the mouth with those on the other.

Arrangement of the lower anterior teeth

In many patients, they will be displayed more during function than the upper teeth and therefore may be a dominant factor in determining the patient's dental appearance. Again, the same general rules regarding perfection and evenness of tooth arrangement which have been discussed previously should be applied. The following should be considered when arranging lower anterior teeth:

1. Vertical overlap.
2. Horizontal overlap.
3. Antero-posterior inclination in proximal view.
4. Inclination of long axes.



Incisal relationship

The method of determining an incisal relationship which is appropriate for an edentulous patient's skeletal relationship is important. If a patient is provided with dentures which have an inappropriate incisal relationship, for example, a Class I incisal relationship on a marked skeletal Class II base, there is a risk that, in addition to problems with stability, the dentures will lack in harmony and the aesthetic result will be poor.

The Gingival Contour

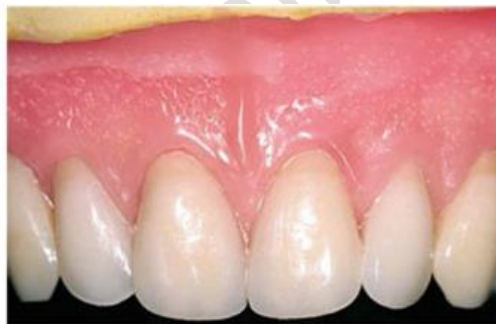There are three aspects to consider:

1. the contour of the gingival margins at the necks of the teeth.

2. the contour of the flange.
3. the color of the flange.

In a natural dentition, the contour of the gingival margin varies from central incisor to lateral incisor to canine. This should be reproduced in a complete replacement denture. In terms of the shape of the flange, the clinician must decide whether to provide a flange with a smooth or anatomical finish. In the case of the anatomical finishing, the dental technician is instructed to

1. reproduce the shapes of the roots of teeth when contouring the flange.
2. The flange can also be stippled to reproduce stippling of the keratinized gingiva. These features are most useful when the patient has a high smile line and is likely to have a visible flange. A potential problem with anatomical contouring is the difficulty in keeping the flanges clean, particularly when extensively stippled.
3. Finally, the appearance of the oral mucosa can be reproduced using color tints in the acrylic resin. This is time consuming for a dental technician and will be facilitated by the technician seeing the patient or a photograph of the oral mucosa. Nonetheless, the appearance of the denture will be enhanced if the flange is visible due to a high smile line.



Anatomical features reproduced in the appearance of a denture flange.

Denture base factors:

1. Contour
2. Colour

Benefits of properly contoured dentures:

- ✓ Improved tolerance and comfort
- ✓ Facilitates stability and control.
- ✓ Prevents chronic biting of the lip or cheek.

Characterization

To alter by application of unique markings, indentations, coloration and similar custom means of delineation on a tooth or dental prosthesis thus enhancing the natural appearance.

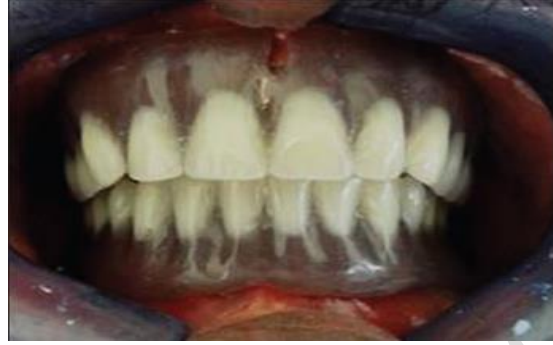Characterizing the dentures without deviating grossly from the principles of teeth setting to suit the individual's appearance. The possible effect is that all dentists may give almost identical complete dentures to their patients. All complete denture wearers were looking similar possessing a monotony of sameness. They understandably do not ask for what they don't know. It is the duty of the dentist to inform the patient that his or her complete denture can be characterized to suit his/her wish and appearance. Characterization helps the dentist to incorporate his artistic skills along with theoretical knowledge in the fabrication of denture. Size and shade of the teeth can be selected to match the patients natural teeth. The aim is that the teeth should harmonize with the facial features, and it should be functionally acceptable. Characterization should have some amount of realistic perception rather than incorporating unrealistic features.

According to Frush and Fisher dentogenic concept includes effects of three main factors such as age, sex and personality in sequence of esthetic planning. Various means like minor irregularities in tooth arrangement, overlapping, tilting, depth grinding, modification of incisal edges, rotations of teeth, stippling, staining, tinting of the denture base, crowding and fixing dental jewelry etc., can be incorporated depending on patient's desire towards achieving natural illusion.

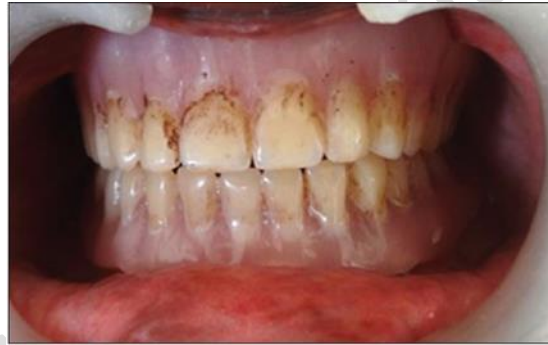Final Decision for Esthetics depends upon:

- Maxillomandibular relationships
- Patient's appearance
- Patient's mental attitude
- Functional requirements

Denture flanges mimicking gingival color along with Stippling



Tobacco staining on complete denture



Crowding and overlapping of the maxillary anterior teeth.

