

Radiology

Lec. 11

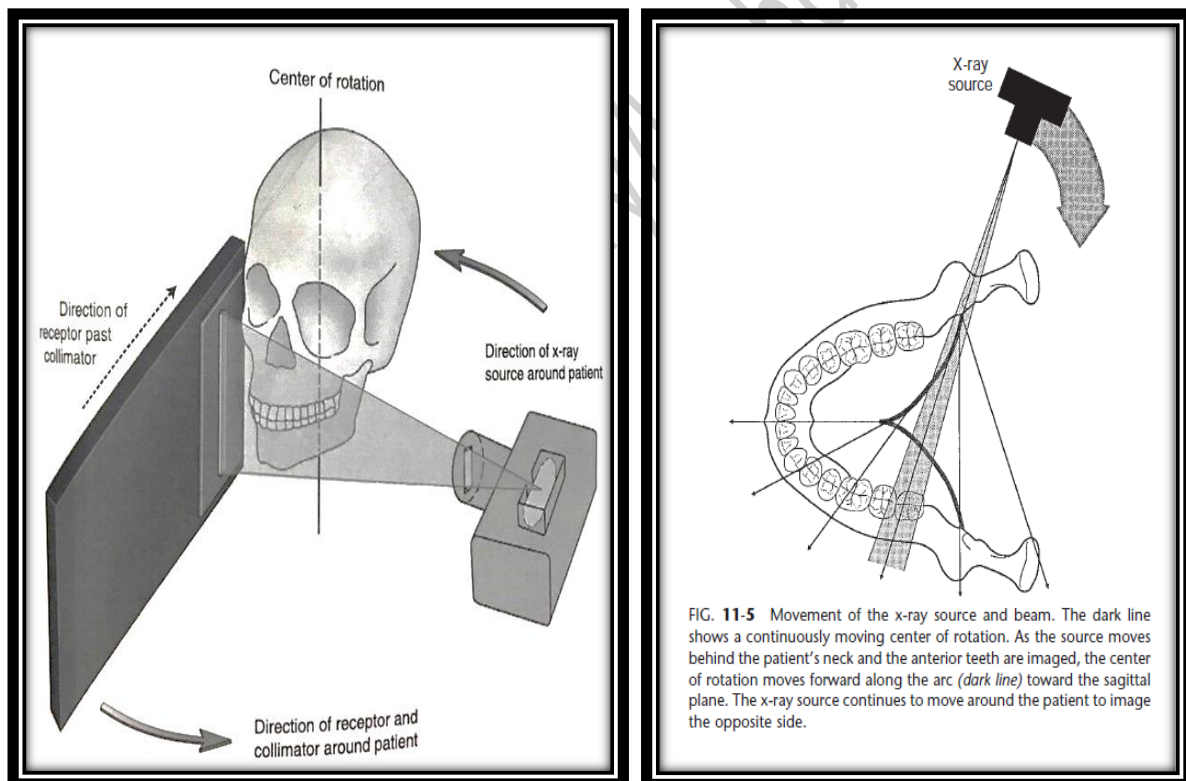
Panoramic Radiography

Dr. Areej

Panoramic imaging (also called *pantomography*) is a technique for producing a single tomographic image of the facial structures that includes both the maxillary and mandibular dental arches and their supporting structures.

Principles of panoramic radiography

Paatero and Numata were the first to describe the principles of panoramic radiography. x-ray source rotate around the patient's head and in opposite direction to the rotation of image receptor and collimator. Lead collimators in the shape of a slit, located at the x-ray source and at the image receptor, limit the central ray to a narrow vertical beam.



Indications

1. Overall evaluation of dentition
2. Evaluation of intraosseous pathology such as cysts, tumors and infections.

3. Gross evaluation of of tempromandiular joints
4. Evaluation of impacted teeth.
5. Evaluation of permanent teeth eruption and mixed dentition.
6. Dentomaxillofacial trauma such as fracture.
7. Developmental disturbances of maxillofacial skeleton.

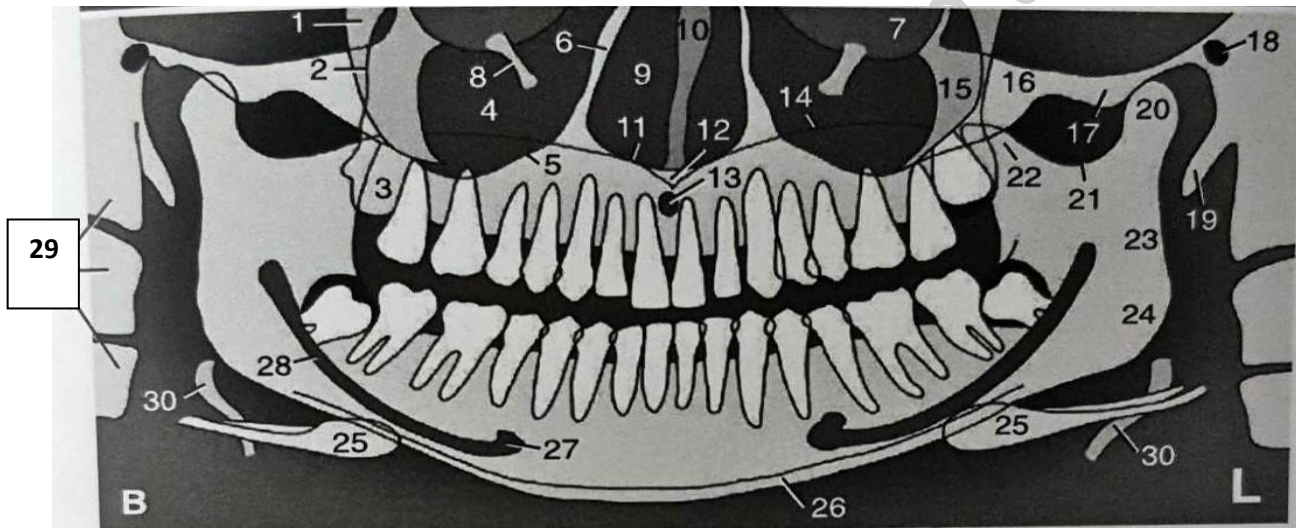
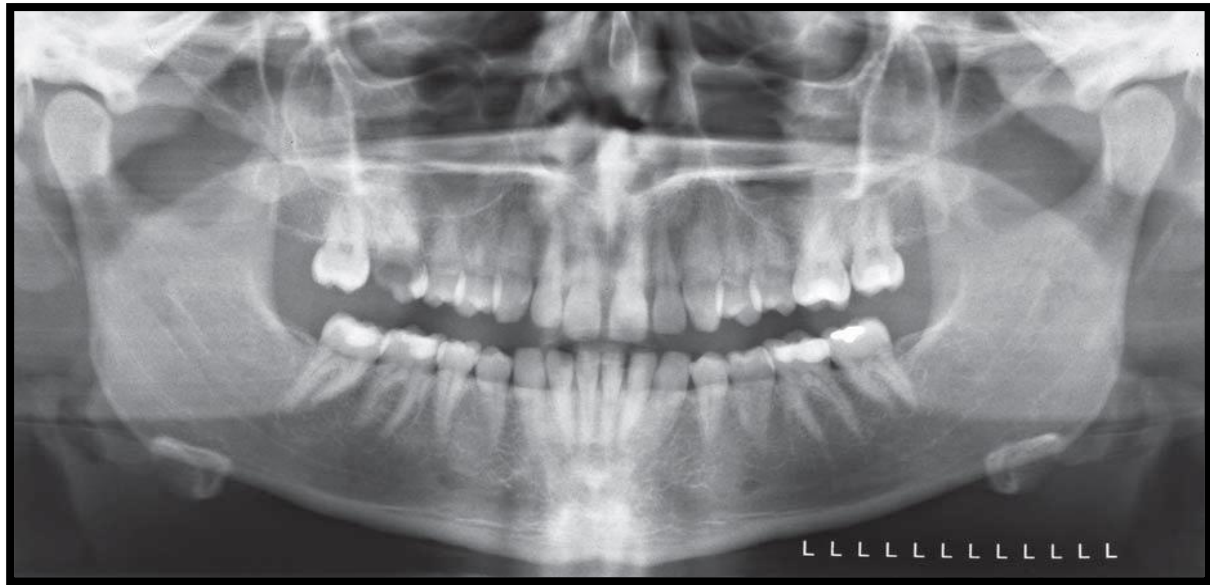Advantages of Panoramic radiograph

The principal advantages of panoramic images include the following:

1. Broad coverage of the facial bones and teeth
2. Low patient radiation dose(compared to full mouth survey and CBCT)
3. Convenience of the examination for the patient
4. Can be used in patients with trismus (unable to open their mouths)or patient untolerate intraoral film.
5. Short time required to make a panoramic image, usually in the range of 3 to 4 minutes (This includes the time necessary for positioning the patient and the actual exposure cycle.)
6. A useful visual aid in patient education and case presentation.
7. Easy radiographic technique.

Disadvantages

1. Lower resolution images that don't provide fine details provided by intraoral periapical radiographs. Thus it is not as useful as periapical radiography for detecting small carious lesions, fine structure of the marginal periodontium, or periapical disease. The proximal surfaces of premolars also typically overlap.
2. Unequal magnification and geometric distortion across the image.
3. The presence of overlapping structures, such as the cervical spine, can hide odontogenic lesions, particularly in the incisor regions.
4. Important objects may be situated outside the plane of focus (image layer) and may appear distorted or not present at all.
5. Difficult to image both jaws when patient has sever maxillomandibular discrepancy.
6. Require accurate patient positioning to avoid positioning errors and artifacts.



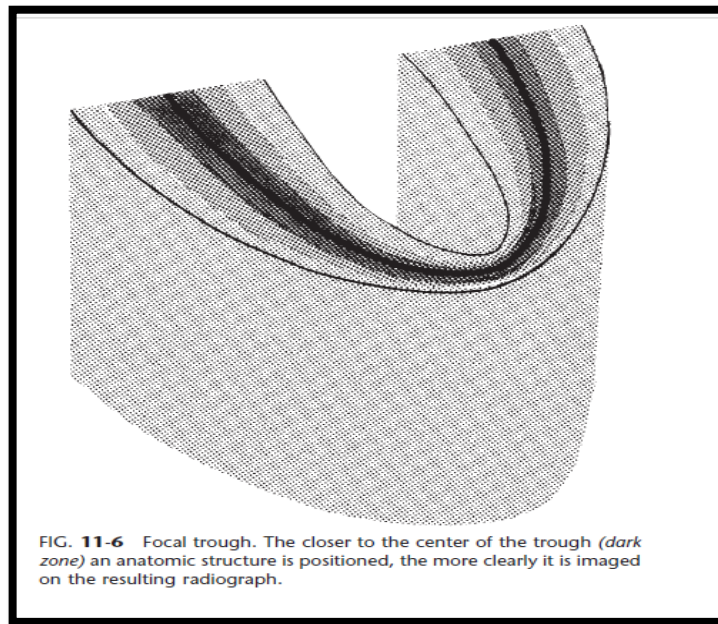
Anatomical landmarks in the panoramic radiograph

- | | | |
|----------------------------------------------------------------------------|-------------------------------------------|---------------------------------|
| 1. Pterygomaxillary fissure | 11. Floor of the nasal cavity | 22. Coronoid process |
| 2. Posterior border of maxilla | 12. Anterior nasal spine | 23. Posterior border of ramus |
| 3. Maxillary tuberosity | 13. Incisive foramen | 24. Angle of mandible |
| 4. Maxillary sinus | 14. Hard palate/floor of the nasal cavity | 25. Hyoid bone |
| 5. Floor of the maxillary sinus | 15. Zygomatic process of the maxilla | 26. Inferior border of mandible |
| 6. Medial border of maxillary sinus/
lateral border of the nasal cavity | 16. Zygomatic arch | 27. Mental foramen |
| 7. Floor of the orbit | 17. Articular eminence | 28. Mandibular canal |
| 8. Infraorbital canal | 18. External auditory meatus | 29. Cervical vertebrae |
| 9. Nasal cavity | 19. Styloid process | 30. Epiglottis |
| 10. Nasal septum | 20. Mandibular condyle | |
| | 21. Sigmoid notch | |

Focal Trough or IMAGE LAYER

—The image layer is a three-dimensional curved zone, where the structures lying within this layer are reasonably well defined on final panoramic image.

—The structures seen on a panoramic image are primarily those located within the image layer. Objects outside the image layer are blurred, magnified, or reduced in size and are sometimes distorted to the extent of not being recognizable.



Real , Double and Ghost images

—Because of the rotational nature of x-ray source and receptor, the x-ray beam intercepts some anatomic structures twice . Depending on their location, objects may cast three different types of images:

1. Real images: object that lie between the center of rotation and the receptor form a real image(all the objects within focal trough cast relatively sharp images). (figure D)
2. Double images: objects that lie posterior to the center of rotation and that intercepted twice by the x-ray beam form double images (figure E).
3. Ghost images: objects that located between the x-ray source and center of rotation, can cast ghost images. The ghost image appear on the opposite side of it's true anatomic location and at higher level.(figure F)

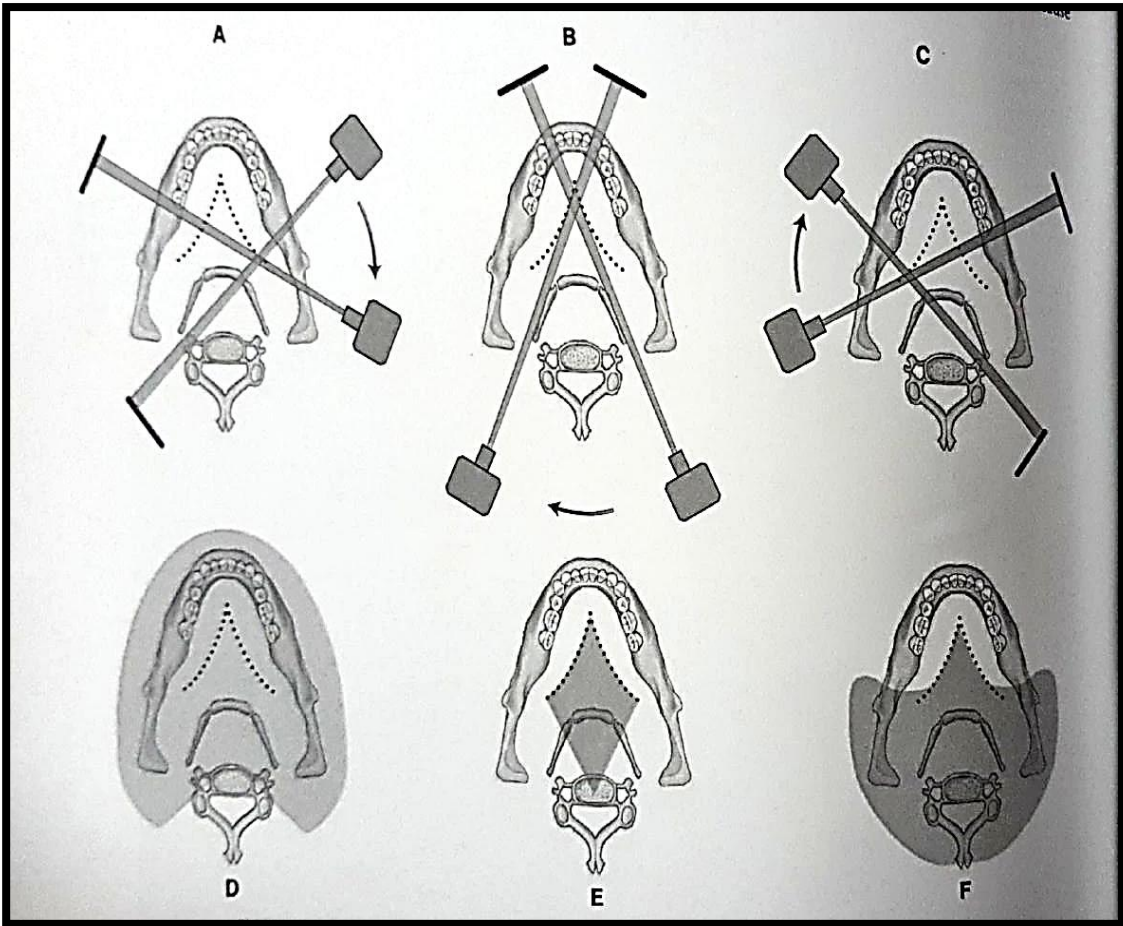


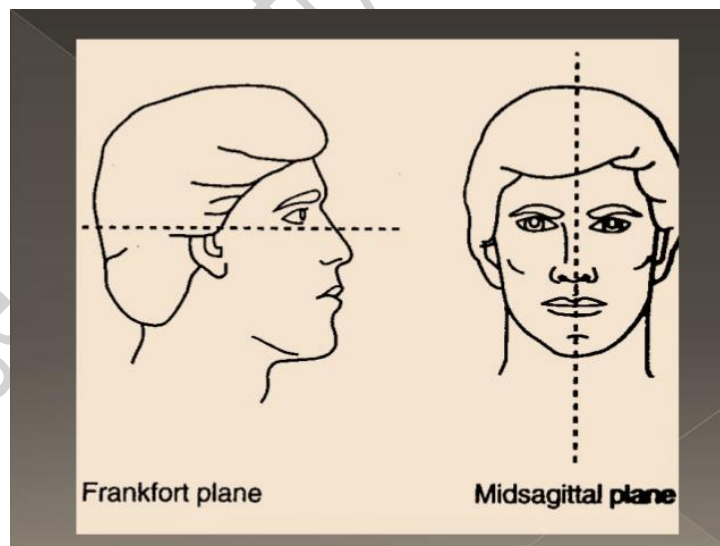
FIG. 11-9 Orthoralix 8500 panoramic machine. (Courtesy Orthoralix 8500, KaVo Dental Corp., Gendex Dental Systems, Lake Zurich, Ill.)

FIG. 11-10 Proline XC panoramic machine. (Courtesy Planmeca Inc., Wood Dale, Ill.)

Patient Positioning and Head Alignment

To obtain diagnostically useful panoramic radiographs, it is necessary to properly prepare patients and to position their heads carefully in the image layer.

1. Dental appliances, earrings, necklaces, hairpins, and any other metallic objects in the head and neck region should be removed.
2. Demonstrate the machine to the patient by cycling it while explaining the need to remain still during the procedure. This is particularly true for children, who may be anxious. Children should be instructed to look forward and to not follow the tube head with their eyes
3. The anteroposterior position of the patient head is achieved typically by place the incisal edges of their maxillary and mandibular incisors into a notched positioning device (the biteblock).
4. The midsagittal plane must be centered within the image layer of the particular x-ray unit. (Patients should not shift the mandible to either side)
5. The patient's chin and occlusal plane must be properly positioned to avoid distortion. The occlusal plane is aligned so that it is lower anteriorly, angled 20 to 30 degrees below the horizontal. A general guide for chin positioning is to place the patient so that a line from the tragus of the ear to the outer canthus of the eye is parallel with the floor. (Frankfort plane)



6. Patients are positioned with their backs and spines as erect as possible and their necks extended.
7. Ask the patient to swallow and hold the tongue on the roof of the mouth. This raises the dorsum of the tongue to the hard palate, eliminating the air space and providing optimal visualization of the apices of the maxillary teeth.

—Most common errors in panoramic radiograph

1. Placement of the patient either too far anterior or posterior results in significant dimensional aberrations in the images. Too far posterior results in magnified mesiodistal dimensions through the anterior sextants and resulting “fat” teeth (see Figure 11-7, *F*).

Too far anterior results in reduced mesiodistal dimensions through the anterior sextants and resulting “thin” teeth (see Figure 11-7, *D*).

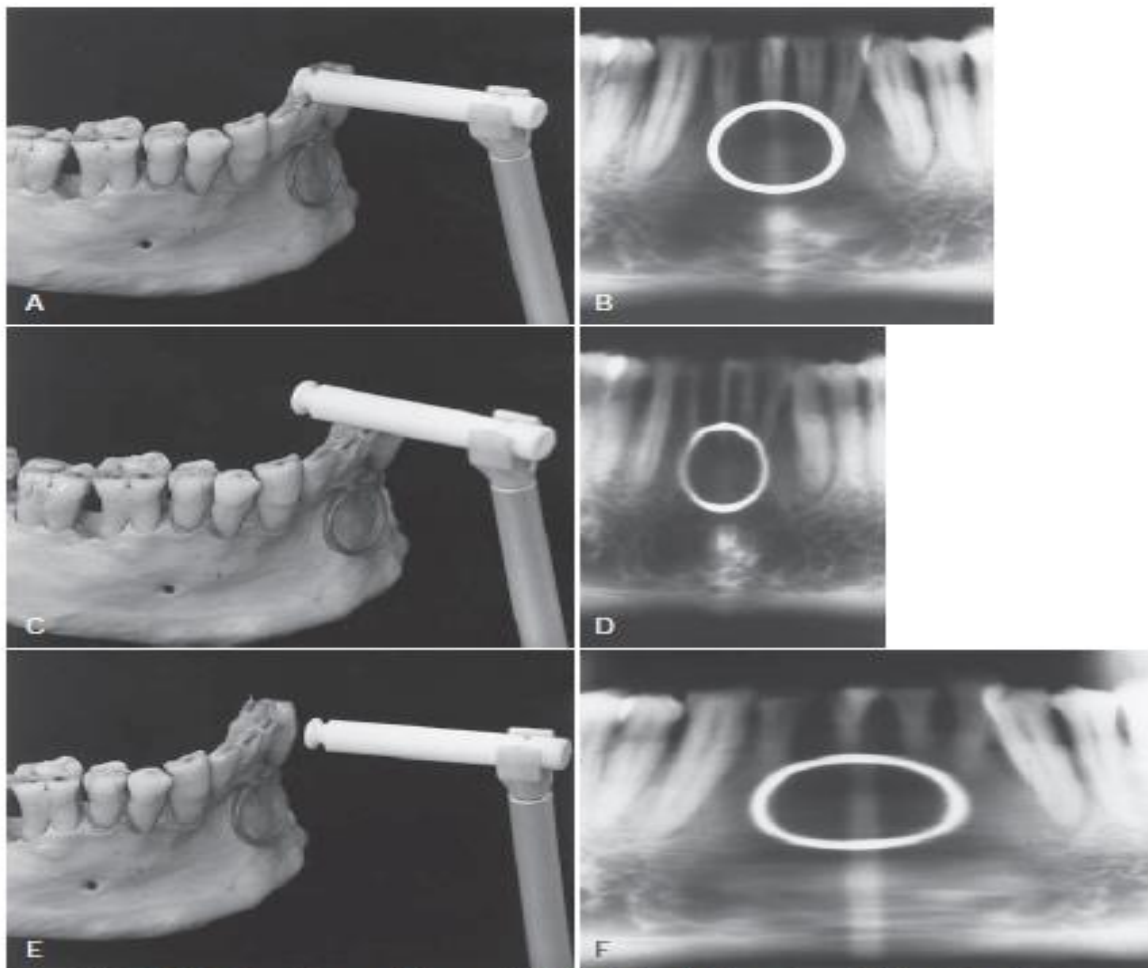
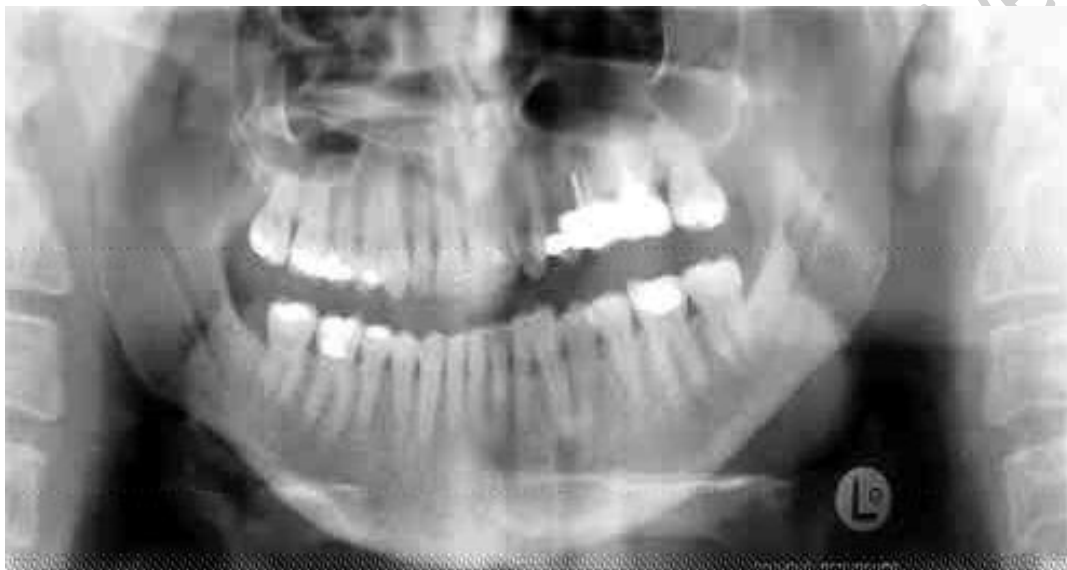
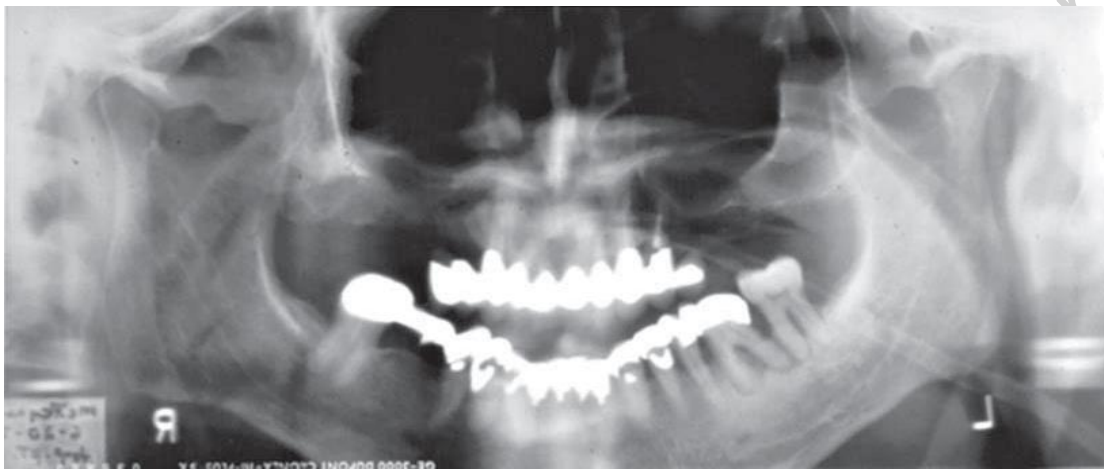
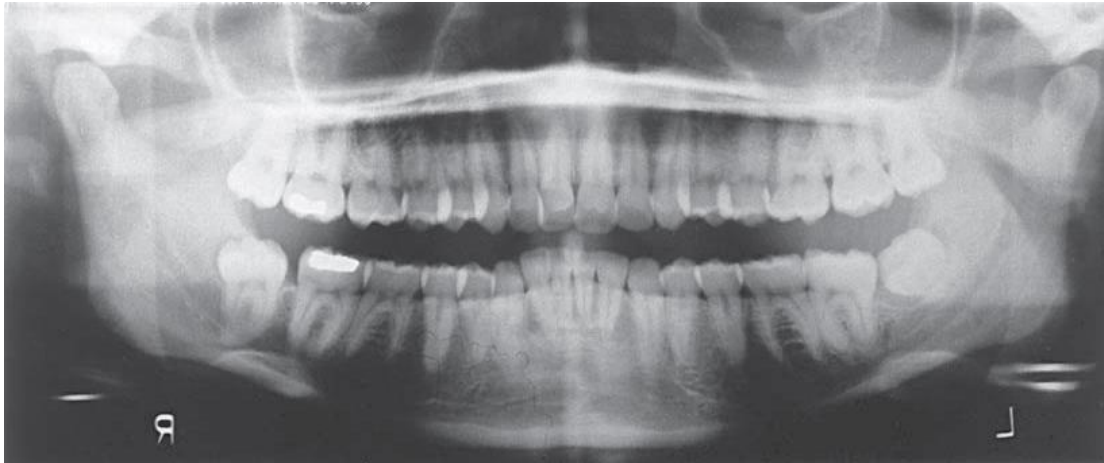FIG. 11-7 **A**, Mandible supporting a metal ring positioned at the center of the focal trough. The incisal edges of the mandibular teeth are indexed by a bite rod-positioning device. The mandible is positioned at the center of the trough. **B**, Resultant panoramic radiograph. **C**, Mandible and ring positioned 5 mm anterior to the focal trough. The incisal edges of the teeth are anterior to the trough. **D**, Resultant panoramic radiograph demonstrating the horizontal minification of both ring and mandibular teeth. **E**, Mandible and ring positioned 5 mm posterior to the focal trough. The incisal edges of the teeth are also posterior to the trough. **F**, Resultant panoramic radiograph demonstrating the horizontal magnification of both ring and mandibular teeth.

2. Failure to position the midsagittal plane lead to rotational midline results in a radiograph showing right and left sides that are unequally magnified in the horizontal dimension . Poor midline positioning is a common error, causing horizontal distortion in the posterior regions, excessive tooth overlap in the premolar regions and, on occasion, nondiagnostic, clinically unacceptable images.
 - ❖ A simple method for evaluating the degree of horizontal distortion of the image is to compare the apparent width of the mandibular first molars bilaterally. The smaller side is too close to the receptor and the larger side is too close to the x-ray source



3. If the chin is tipped too high, the occlusal plane on the radiograph appears flat or inverted, and the image of the mandible is distorted (Fig. 11-12, A). In addition, a radiopaque shadow of the hard palate is superimposed on the roots of the maxillary teeth. While If the chin is tipped too low, the teeth become severely overlapped, the symphyseal region of the mandible may be cut off the film, and both mandibular condyles may be projected off the superior edge of the film (Fig. 11-12, B).



— FIG. 11-12 Panoramic radiographs demonstrating poor patient head alignment. **A**, The chin and occlusal plane are rotated upward, **B**, The chin and occlusal plane are rotated downward.

—
 4. improperly positioned patient. Patients don't sit straight and align or don't stretch their back leading to large radiopaque region in the middle (“ spine-shadow ghost ”

