

PULPOTOMY

The procedure that involve the amputation of affected, infected coronal portion of the dental pulp leaving intact the vital tissue in the canals, followed by placement of a medicament or dressing over the remaining pulp stump in an attempt to promote healing and retention of this vital tissue (preserving the vitality and function of the remaining part of radicular pulp).

Objectives

- ☺ Removal of inflamed and infected coronal pulp at the site of exposure thus preserving the vitality of the radicular pulp and allowing it to heal.
- ☺ The next main objective is to maintain the tooth in the dental arch.

Indications of Pulpotomy

- 1) Mechanical pulp exposure in primary teeth.
- 2) Teeth showing a large carious lesion but free of radicular pulpitis
- 3) History of only spontaneous pain
- 4) Hemorrhage from exposure sites bright red and can be controlled
- 5) Absence of abscess or fistula
- 6) No interradicular bone loss
- 7) No interradicular radiolucency
- 8) At least 2/3rd of root length still present to ensure reasonable functional life
- 9) In young permanent tooth with vital exposed pulp and incompletely formed apices.

Contraindications of Pulpotomy

- ✗ Persistent toothache.
- ✗ Tenderness on percussion
- ✗ Root resorption more than 1/3rd of root length
- ✗ Large carious lesion with non-restorable crown
- ✗ Highly viscous, sluggish hemorrhage from canal orifice, which is uncontrollable
- ✗ Medical contradictions like heart disease, immunocompromised patient
- ✗ Swelling or fistula
- ✗ External or internal resorption
- ✗ Pathological mobility
- ✗ Calcification of pulp.

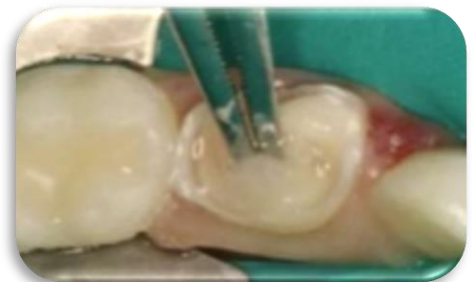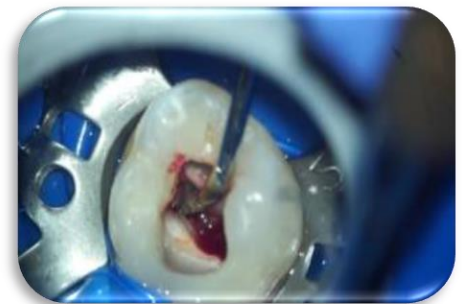
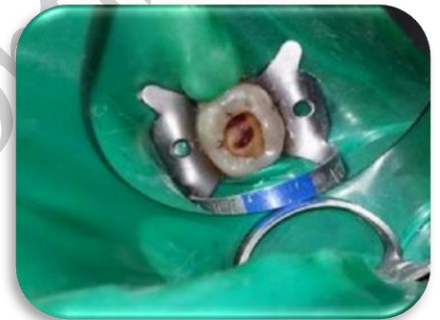The clinical procedure

The justification for this procedure is that the coronal pulp tissue, which is adjacent to the carious exposure, usually contains microorganisms and shows evidence of inflammation and degenerative change. The abnormal tissue can be removed, and the healing can be allowed to take place at the entrance of the pulp canal in an area of essentially normal pulp. Even the pulpotomy procedure, however, is likely to result in a high percentage of failures unless the teeth are carefully selected.

In the pulpotomy procedure,

- 1) At first, the tooth should be anesthetized and isolated with the rubber dam. A surgically clean technique should be used throughout the procedure. All remaining dental caries, as well as the overhanging enamel, should be removed to provide good access to the coronal pulp. Pain during caries removal and instrumentation may be an indication of faulty anesthetic technique. More often, however, it indicates pulpal hyperemia and inflammation, which makes the tooth a poor risk for vital pulpotomy. If the pulp at the exposure site bleeds excessively after complete removal of caries, the tooth is also a poor risk for vital pulpotomy.
- 2) Removal of the entire roof of the pulp chamber should be done. No overhanging dentin from the roof of the pulp chamber or pulp horns should remain. No attempt is made to control the hemorrhage until the coronal pulp has been amputated. Funnel-shaped access to the entrance of the root canals should be created. A sharp discoid spoon excavator, large enough to extend across the entrance of the individual root canals, may be used to amputate the coronal pulp at its entrance into the canals. The pulp stumps should be excised cleanly, with no tissue tags extending across the floor of the pulp chamber. Then irrigation to the pulp chamber with a light flow of water from a water syringe and evacuated.
- 3) Placement of cotton pellets moistened with water in the pulp chamber and allowed to remain over the pulp stumps until a clot forms which is apparently essential for healing.

There are two specific pulpotomy techniques have evolved and are in general use:



Pulpotomy Technique for Permanent Teeth

The use of either calcium hydroxide or MTA can be recommended in the treatment of permanent teeth with carious pulp exposures when there is a pathologic change in the pulp at the exposure site. ***This procedure is particularly indicated for:***

- ☺ Exposure that occurred in young permanent teeth (where exposure of the pulp occurred by mechanical or bacterial means) and the remaining radicular tissue is judged vital by clinical and radiographic criteria whereas the root closure is not complete to preserve vitality of radicular pulp and allow for normal root closure.
- ☺ Permanent tooth with a pulp exposure resulting from crown fracture when the trauma has also produced a root fracture of the same tooth.



Note:

The procedure of vital pulpotomy is completed during a single appointment. Only teeth free of symptoms of painful pulpitis are considered for treatment.

If calcium hydroxide is used as a capping material, so it called as calcium hydroxide pulpotomy or young permanent partial pulpotomy or Cvek's Pulpotomy

The clinical procedure

The procedure involves the amputation of the coronal portion of the pulp as described, the control of hemorrhage, and the placement of the capping material over the pulp tissue remaining in the canals. A protective layer of hard-setting cement is placed over the calcium hydroxide (or the capping material being used such as MTA or Biodentine etc...) to provide an adequate seal. The tooth is subsequently prepared for full-coverage restoration.

However, if the tissue in the pulp canals appears hyperemic after the amputation of the coronal tissue, a pulpotomy should no longer be considered. Endodontic treatment is indicated if the tooth is to be saved. After 1 year, a tooth that has been treated successfully with a pulpotomy should have a normal periodontal ligament and lamina dura, radiographic evidence of a calcified bridge, and no radiographic evidence of internal resorption or pathologic resorption. The treatment of permanent teeth by the pulpotomy method has resulted in a higher rate of success when the teeth are selected carefully based on existing knowledge of diagnostic techniques.

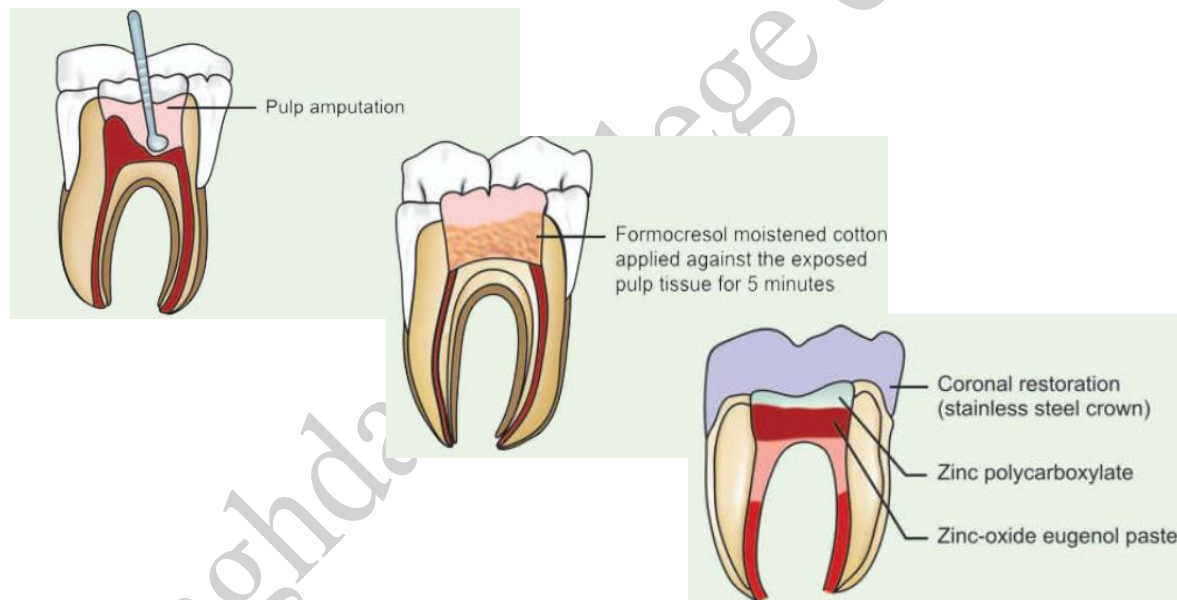
Pulpotomy Technique for Primary Teeth

The same diagnostic criteria recommended for the selection of permanent teeth for the pulpotomy procedure should be used in the selection of primary teeth for this procedure. The treatment is also completed during a single appointment. A surgically clean technique should be used. The coronal portion of the pulp should be amputated as described

previously, the debris should be removed from the chamber, and the hemorrhage should be controlled. If there is evidence of hyperemia after the removal of the coronal pulp, which indicates that inflammation is present in the tissue beyond the coronal portion of the pulp, the technique should be abandoned in favor of pulpectomy or the removal of the tooth. If the hemorrhage is controlled readily and the pulp stumps appear normal, it may be assumed that the pulp tissue in the canals is normal, and it is possible to proceed with pulpotomy.

The pulp chamber is dried with sterile cotton pellets. Next, a pellet of cotton moistened with a 1:5 concentration of Buckley's formocresol and blotted on sterile gauze to remove the excess is placed in contact with the pulp stumps and allowed to remain for 5 minutes. Because **formocresol is caustic**, care must be taken to avoid contact with the gingival tissues. The pellets then removed, and the pulp chamber is dried with new pellets.

If the pulp stump become black instead of red, freshly prepared thick pulpotomy paste is prepared (by mixing of one drop of T.C.F. + one drop of eugenol+ zinc oxide powder) and placed over the pulp stumps. Then Cement base should applied on it and restored with filling material later on the tooth should restored with a stainless steel crown.



Notes:

Although the formocresol pulpotomy technique has been recommended for many years as the principal method for treating primary teeth with carious exposures, a substantial shift away from use of this medicament has occurred because of concerns about its toxic effects. Many alternatives, including MTA, sodium hypochlorite, ferric sulfate, electrosurgery, and lasers, have been investigated to replace formocresol as the medicament of choice for pulpotomy.

Despite this, formocresol continues to be a very commonly used pulpotomy medicament.



Buckley's original formula for formocresol calls for equal parts of formaldehyde and cresol. The 1:5 concentration of this formula is prepared by, first, thoroughly mixing three parts of glycerin with one part of distilled water, and then adding four parts of this diluent to one part of Buckley's formocresol, followed again by thorough mixing.



Ca (OH)₂ in primary teeth induce osteoclastic activity

What do you know about Pulpotec?

Pulpotec – is a radiopaque, non-resorbable dental paste for simple, rapid and long-term treatment by pulpotomy of vital molars, both permanent and deciduous.

The addition of pharmacological constituents ensures an aseptic treatment, induces cicatrization of the pulpal stump at the chamber-canal interface, whilst maintaining the structure of the underlying pulp.

The treatment of pulpitis with Pulpotec is considerably faster than by pulpectomy. It also avoids the numerous failures that have been noted with so-called «total» pulpectomy (over 50% worldwide in 1995).

Composition

- **Powder** Iodoform, Polyoxymethylene, excipient
- **Liquid** Phenol, Guaiacol, Formaldehyde, Dexamethasone Acetate, excipient

Directions for use (as it appeared in the leaflet of the product)

Perform pulpotomy in the usual way. Pulpotec being antiseptic, the use of a rubber dam is optional. Use high-speed rotary instruments in order to avoid tearing of the radicular endings and take care to eliminate all the cameral pulp. The use of after a pulpotomy performed with laser is also recommended.

Two methods are recommended for inserting PULPOTEC into the pulp chamber:

1. The traditional method Mix Pulpotec liquid with Pulpotec powder and blend to obtain required thick, creamy consistency of the paste. Insert the paste into the pulp-chamber with a large sized paste filler. The presence of small quantities of blood does not affect the efficiency of Pulpotec. Air-dry the cavity just prior to applying the paste. Seal with a temporary cement. Place a cotton roll between the 2 dental arches and request the patient to bite progressively but firmly, so that the Pulpotec paste clings to the walls of the pulp-cavity as well as to the root canal orifices.

2. Another efficient but simple method for inserting Pulpotec into the pulp-chamber mix the powder and the liquid on a glass slab and blend until the mix reaches the consistency

of a small, supple ball of putty. Shape the ball into a cylinder and insert directly into the pulp-chamber. Press into place with a spatula and continue as indicated above with the temporary cement and the cotton roll.

**Setting time of Pulpotec is approximately 7 hours.

The second session should take place once the initial Pulpotec insert has set. The treatment can then be completed by setting the final tight obturation with amalgam or any other suitable material. This can be directly placed on the, possibly leaving a thin intermediary layer of temporary cement to insulate Pulpotec from the final obturation material. Pulpotec being Eugenol free, any bonding application on the treated tooth is advisable. Though not totally necessary, a fixed prosthesis is recommended in order to ensure tight sealing, resistance and long-term results.

APEXOGENESIS

It is defined as the treatment of a vital pulp in the permanent teeth by capping or pulpotomy in order to permit continued growth of the root and closure of the open apex.

Objectives

Maintenance of integrity of the radicular pulp tissue to allow for continued root growth.

Indications

- 😊 Indicated for traumatized or pulpally involved vital permanent tooth with incomplete formation of the root apex.
- 😊 No history of spontaneous pain
- 😊 No sensitivity on percussion.
- 😊 No hemorrhage.
- 😊 Normal radiographic appearance.

Contraindications

- 😞 Evidence that radicular pulp has undergone degenerative changes
- 😞 Purulent drainage
- 😞 History of prolonged pain
- 😞 Necrotic debris in canal
- 😞 Periapical radiolucency.