

## **MINERAL TRIOXIDE AGGREGATE**

MTA is emerging as a popular product for pulpotomies secondary to a variety of factors. Torabinejad described the physical and chemical properties of MTA in 1995.

It is ash colored powder made primarily of fine hydrophilic particles of:

- 1) Tricalcium silicate
- 2) Tricalcium aluminate
- 3) Tricalcium oxide
- 4) Silicate oxide and bismuth oxide is added for radio-opacity.

MTA should mixed with sterile water or other sterile liquids in 3: 1 (powder /liquid) ratio to obtain a putty consistency or a thick grainy paste. If the paste is, too dry it will fall when one try to pick it up. Hydration of the powder results in a colloidal gel composed of calcium oxide crystals in an amorphous structure. This gel solidifies into a hard structure in less than three hours (2 hours and 45 minutes).

MTA has an antibacterial effect on some facultative bacteria but no effect on strict anaerobic bacteria. This limited antibacterial effect is less than that demonstrated by calcium hydroxide pastes. The ability of MTA to resist the penetration of microorganisms appears to be high. – The use of MTA as an agent for pulp capping or for providing apical seal is well documented. Recent studies have indicated that MTA can be used successfully as a pulpotomy agent also.

### **Properties of MTA**

- 😊 It is biocompatible material and its sealing ability is better than that of amalgam or ZOE.
- 😊 Initial pH is 10.2 and set pH is 12.5
- 😊 Antimicrobial activity.
- 😊 The setting time of cement is 4 hours
- 😊 The ability to set in the presence of moisture and blood.
- 😊 Low cytotoxicity
- 😊 It presents with minimal inflammation if extended beyond the apex.

***The negative attributes include:***

- ♣ Difficulty of handling
- ♣ Exceptional cost.
- ♣ MTA can cause pulp canal obliteration.

## MECHANISM OF ACTION

The successful usage of MTA in endodontic applications can be attributed to its biocompatibility, bioactivity and mechanism of action. The four actions of MTA after direct placement in contact with living tissues are:

- (i) Creation of an unfavorable environment for growth of bacteria due to its alkaline pH.
- (ii) Formation of hydroxyapatite like mineral structure on its surface and provide the biological seal.
- (iii) Formation of calcium hydroxide, which dissociates to release Ca ions, to promotes cellular attachment and proliferation.
- (iv) Modulation of cytokine production and encouragement of hard tissue forming cells to differentiate and migrate.

## Clinical applications of MTA

### 1) Pulp capping:

#### a) Direct Pulp Capping:

MTA is suitable as a pulp capping because it stimulates dental bridge formation and the bridge formed adjacent to MTA will be thick and continuous with regional dentin. No bacteria were observed on the cavity wall when MTA was used, due to sealing ability, biocompatibility, alkalinity, and ability of MTA to stimulate dentin bridge formation.

#### b) Pulpotomy of immature permanent teeth:

The pulp responds favorably to the protection provided by an MTA layer, and the reparative dentin is consistently uniform and thicker under MTA more than that with Ca (OH)<sub>2</sub>.

#### c) Pulpotomy of primary teeth

MTA seems to be a suitable replacement for T.C.F.

- 2) Root resorption
- 3) Apexification
- 4) Furcal repair
- 5) Perforation repair
- 6) Root ending filling

## FAILURES AFTER VITAL PULP THERAPY

Factors that may lead to failure in the formation of a calcified bridge across the vital pulp may involve:

- 1) The age of the patient
- 2) Degree of surgical trauma
- 3) Sealing pressure
- 4) Improper choice of capping material
- 5) Low threshold of host resistance
- 6) Presence of microorganisms with subsequent infection.

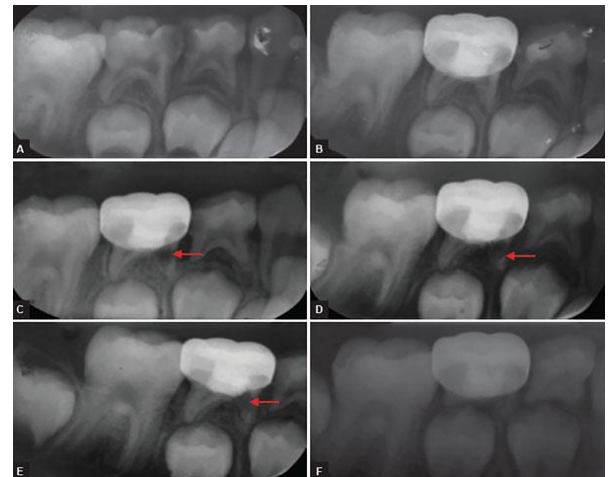
This failure may appear as:

- ☹ Internal resorption
- ☹ Alveolar abscess
- ☹ Early exfoliation or over retention of primary teeth with pulp treatment

### INTERNAL RESORPTION

One of the most frequently seen evidence of an abnormal response in primary teeth within the pulp canal several months after the pulpotomy procedure is the radiographic evidence of internal resorption.

Internal resorption is a destructive process generally caused by odontoclastic activity, and it may progress slowly or rapidly. Occasionally, secondary repair of the resorbed dentinal area occurs. No satisfactory explanation for the post pulpotomy type of internal resorption has been given. However, that with a true carious exposure of the pulp, an inflammatory process will be present to some degree. The inflammation may be limited to the exposure site, or it may be diffused throughout the coronal portion of the pulp. Amputation of all pulp showing the inflammatory change may be difficult or impossible, and abnormal pulp tissue may be allowed to remain. If the inflammation extended to the entrance of the pulp canal, odontoclasts may have been attracted to the area; if it were possible to examine the tooth histologically; small bays of resorption would be evident. This condition may exist at the time of pulp therapy, although there is no way to detect it. The only indication would be the clinical evidence of a hyperemic pulp.

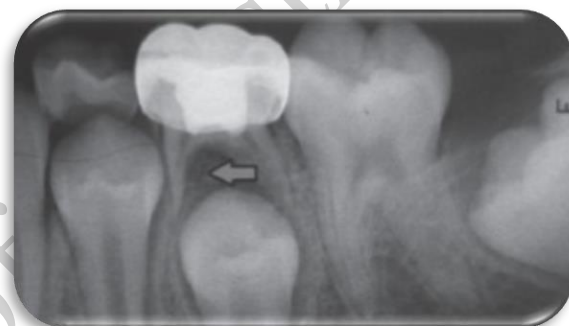

Inflammatory cells drawn to the area because of the placement of an irritating capping material might well attract odontoclastic cells and initiate internal resorption. This may explain the occurrence of internal resorption even though the pulp is normal at the time of treatment. Because the roots of primary teeth are undergoing normal physiologic resorption, vascularity of the apical region is increased. When an irritant in the form of a pulp-capping material is placed on the pulp, odontoclastic activity present in the area and may predispose the tooth to internal resorption.

### **ALVEOLAR ABSCESS**

Some months after pulp therapy has been completed, an alveolar abscess occasionally develops. The tooth usually remains asymptomatic, and the child is unaware of the infection, which may be present in the bone surrounding the root apices or in the area of the root bifurcation.

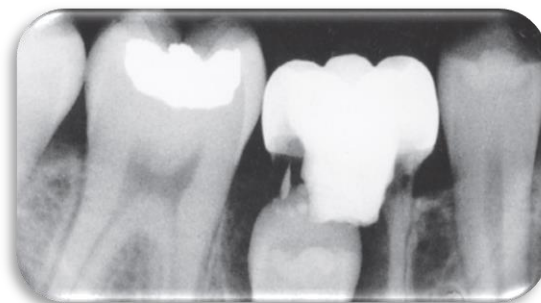
A fistulous opening may be present, which indicates the chronic condition of the infection. Primary teeth that show evidence of an alveolar abscess should be removed. Endodontic treatment may be considered for permanent teeth that have previously been treated by pulp capping or by pulpotomy and later show evidence of pulpal necrosis and apical infection.



### **EARLY EXFOLIATION OR OVER-RETENTION OF PRIMARY TEETH WITH PULP TREATMENTS**

Occasionally a pulpally treated tooth previously believed to be successfully managed will loosen and exfoliate (or require extraction) prematurely for no apparent reason. It is believed that such a condition results from low-grade, chronic, asymptomatic, localized infection. Usually, abnormal and incomplete root resorption patterns of the affected teeth are also observed. When this occurs, space management must be considered.

Another sequela requiring close observation is the tendency for primary teeth undergoing successful pulpotomies or pulpectomies to be over-retained. This situation may have the untoward result of interfering with the normal eruption of permanent teeth and



adversely affecting the developing occlusion. Close periodic observation of pulpally treated teeth is necessary to intercept such a developing problem. Extraction of the primary tooth is usually sufficient. This phenomenon may occur when normal physiologic exfoliation is delayed by the bulky amount of cement contained in the pulp chamber. Even though the material is resorbable, its resorption is slowed significantly when large quantities are present.

**Good  
Luck**