

Dr. Aseel Haidar

Treatment of Deep Caries, Vital Pulp Exposure, Pulpless Teeth

It is well recognizable that maintenance of the primary teeth has many of the same goals as the maintenance of the permanent dentition. Primary teeth aid in maintaining the integrity of the dental arch, thereby preventing malocclusion, allowing for proper speech and mastication, preventing aberrant tongue habits, and providing esthetics. Primary teeth have the additional goal of guiding the eruption of the permanent teeth. Therefore treating primary teeth that have been afflicted by disease or trauma is imperative. However, the treatment of the dental pulp exposed by the caries process, by accident during cavity preparation, or even because of injury and fracture of the tooth has long presented a challenge.

Children and young adults who have not received early and adequate dental care and optimal systemic fluoride often have deep carious lesions with pulpal exposures.



Notes:



Experience, patience, skill and considerable clinical acumen are necessary to overcome the difficulty of pulp treatment in children.



Pulp treatment in children is more challenging and difficult than in adult due to the following reasons:

- 1) Behavioral management problems in children.
- 2) Limited opening of the mouth.
- 3) Presence of complex root canal system in primary molars: fine and tortuous canals, accessory canals, lateral canals, anastomoses, etc...
- 4) Danger of injuring the underlying permanent tooth bud.

Objectives of pulp therapy

The primary objective of pulp therapy is to maintain the integrity and health of the teeth and their supporting tissues. Other objectives of pulp therapy are:






Conservation of the tooth in a health state functioning as an integral component of dentition.



Preservation of dental arch space and prevent consequent malocclusion due to premature tooth loss.



Maintain esthetics, mastication.

-  Prevent aberrant tongue habits
-  Aid in speech.
-  Prevent psychological effects associated with tooth loss.



Notes:


In certain restraints, pulpal therapy cannot saved the tooth such as:


- Medically compromised.
- Non-restorable teeth.
- Rate of root resorption
- Life expectancy of a tooth.


DIAGNOSTIC AIDS IN THE SELECTION OF TEETH FOR VITAL PULP THERAPY


1) HISTORY OF PAIN

The history of either the presence or the absence of pain may not be as reliable in the differential diagnosis of the condition of the exposed primary pulp as it is in permanent teeth. Degeneration of primary pulp even to the point of abscess formation without the child recalling pain or discomfort is common. Nevertheless, the history of a toothache should be the first consideration in the selection of teeth for vital pulp therapy.

 *Momentary pain:* Immediate response to hot or cold that disappears on removal of the stimulus indicates that the pathosis is limited to the coronal pulp. A toothache coincident with or immediately after a meal may not indicate extensive pulpal inflammation; could be due to an accumulation of food within a caries lesion, by pressure, or by a chemical irritation to vital pulp protected by only a thin layer of intact dentin.

 *A severe toothache at night* usually signals extensive degeneration of the pulp and calls for more than conservative pulp therapy. This type of pain indicates pulpal damage—irreversible pulpitis.

 *A spontaneous toothache* of more than momentary duration occurring at any time usually means that pulpal disease has progressed too far for treatment, even with a pulpotomy.

 *Persistent pain:* Pain from thermal stimuli would indicate wide spread inflammation of the pulp, extending into the radicular filaments.

2) CLINICAL SIGNS AND SYMPTOMS

- a) A gingival abscess or draining fistula associated with a tooth with a deep caries lesion is an obvious clinical sign of an irreversibly diseased pulp. Successful endodontic therapy or extraction of the tooth can resolve such infections.
- b) Abnormal tooth mobility is another clinical sign that may indicate a severely diseased pulp. If pain is absent or minimal during manipulation of the diseased mobile tooth, the pulp is probably in a more advanced and chronic degenerative condition. The dentist should distinguish pathologic mobility from normal mobility in primary teeth near exfoliation.
- c) Sensitivity to percussion or pressure is a clinical symptom suggestive of at least some degree of pulpal disease, but the degenerative stage of the pulp is probably of the acute inflammatory type. Tooth mobility or sensitivity to percussion or pressure may be a clinical sign of other dental problems as well, such as a high restoration or advanced periodontal disease. However, when identification of this clinical information occur in a child and is associated with a tooth having a deep caries lesion, the problem is most likely to be caused by pulpal disease and possibly by inflammatory involvement of the periodontal ligament.

3) RADIOGRAPHIC INTERPRETATION

A recent x-ray film must be available to examine for evidence of periradicular or periapical changes, such as thickening of the periodontal ligament or rarefaction of the supporting bone. Radiographic interpretation is more difficult in children than in adults:

- ✓ The permanent teeth may have incompletely formed root ends, giving an impression of periapical radiolucency.
- ✓ The roots of the primary teeth undergoing even normal physiologic resorption often present a misleading picture or one suggestive of pathologic change.
- ✓ The proximity of caries lesions to the pulp cannot always be determined accurately in the x-ray film. What often appears to be an intact barrier of secondary dentin protecting the pulp may actually be a perforated mass of irregularly calcified and carious material. The pulp beneath this material may have extensive inflammation.

4) PULP TESTING

Historically the value of the electric pulp test in determining the condition of the pulp of primary teeth is questionable. Although it will give an indication of whether the pulp is vital, the test does not provide reliable evidence of the degree of pulpal inflammation. A complicating factor is the occasional positive response to the test in a tooth with a necrotic pulp if the content of the canals is liquid. The child's apprehension associated with the pulp testing itself can affect the reliability of the pulp test for the young child. Types of pulp testing:

1) Thermal test

- ♣ Cold test: Applied in several different ways like stream of cold air, cold- water bath, ethyl chloride, dry ice etc...
- ♣ Heat test: The mostly used way is by applying hot gutta - percha and hot compound.

2) Electrical Pulp Testing**5) PHYSICAL CONDITION OF THE PATIENT**

Although local observations are of extreme importance in the selection of cases for vital pulp therapy, the dentist must also consider the physical condition of the patient. In seriously ill children, extraction of the involved tooth after proper premedication with antibiotics, rather than pulp therapy, should be the treatment of choice. Children with conditions that render them susceptible to subacute bacterial endocarditis or those with nephritis, leukemia, solid tumors, idiopathic cyclic neutropenia, or any condition that causes cyclic or chronic depression of granulocyte and polymorphonuclear leukocyte counts should not be subjected to the possibility of an acute infection resulting from failed pulp therapy. Occasionally, pulp therapy for a tooth of a chronically ill child may be justified, but only after careful consideration is given to the prognosis of the child's general condition, the prognosis of the endodontic therapy, and the relative importance of retaining the involved tooth.

EVALUATION OF TREATMENT PROGNOSIS BEFORE PULP THERAPY

The diagnostic process of selecting teeth that are good candidates for vital pulp therapy include:

- 1)** The dentist must decide that the tooth has a good chance of responding favorably to the pulp therapy procedure indicated.
- 2)** The advisability of performing the pulp therapy and restoring the tooth must be weighed against extraction and space management.
- 3)** The tooth is restorable or not.
- 4)** The periodontal structures if they are irreversibly diseased.
- 5)** The level of patient and parent cooperation and motivation in receiving the treatment.
- 6)** The level of patient and parent desire and motivation in maintaining oral health and hygiene.
- 7)** The caries activity of the patient and the overall prognosis of oral rehabilitation.
- 8)** The stage of dental development of the patient.
- 9)** Age of the patient.
- 10)** The degree of difficulty anticipated in adequate performance of the pulp therapy (instrumentation) in the particular case.

- 11) Space management issues resulting from previous extractions, preexisting malocclusion, ankylosis, congenitally missing teeth, and space loss caused by the extensive carious destruction of teeth and subsequent drifting.
- 12) Excessive extrusion of the pulpally involved tooth resulting from the absence of opposing teeth.

TREATMENT OF THE DEEP CARIES LESION

The indications, objectives, and type of pulpal therapy depend on whether the pulp is vital or nonvital, based on the tooth's clinical diagnosis of normal pulp, reversible pulpitis, irreversible pulpitis, or necrotic pulp.

INDIRECT PULP TREATMENT

(GROSS CARIES REMOVAL OR INDIRECT PULP THERAPY)

The procedure in which only the removal of gross caries from the lesion and then sealed the cavity for a time with a biocompatible material is referred to as *indirect pulp treatment*. Indirect pulp treatment is not a new procedure but it has attracted renewed interest. Teeth with deep caries that are free of symptoms of painful pulpitis are candidates for this procedure.

Aim: To remove the infected dentin and leaving intact the affected dentin, so that the affected dentin will remineralize and act as a barrier above the healthy pulp. Therefore, there will be:

- Arresting to the carious process
- Promoting the dentin sclerosis
- Stimulating formation of tertiary dentin
- Remineralization of carious dentin.

Indications:

- 😊 Deep caries in which the pulpal inflammation has been judged minimal and complete removal of caries would probably cause pulpal exposure.
- 😊 The tooth should have **NO**:
 - ✓ No history of spontaneous, unprovoked toothache (The tooth may have had a history of toothache associated with eating, as long as pain subsided immediately after removal of the stimulus).
 - ✓ No tenderness to percussion.
 - ✓ No abnormal mobility.
 - ✓ No radiographic evidence of radicular disease.
 - ✓ No radiographic evidence of abnormal internal or external root resorption.

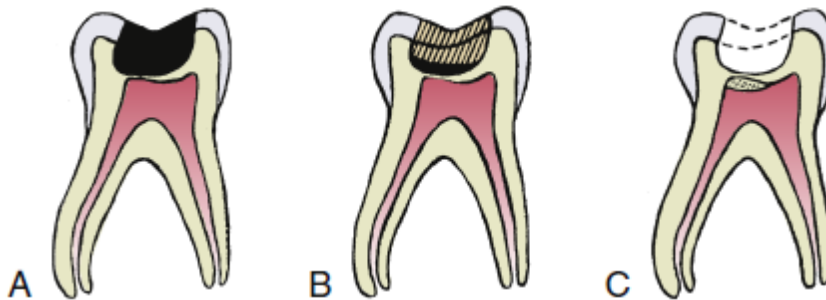
Contraindications:

- When there is wide spread inflammation or evidence of periapical pathosis.

The clinical procedure

It involves removing the gross caries with large round bur or spoon excavators, but allowing sufficient caries to remain over the pulp horn to avoid exposure of the pulp. The procedure usually results in some discomfort to the child; therefore, it is advisable to use a local anesthetic. The walls of the cavity should be extended to sound tooth structure because the presence of carious enamel and dentin at the margins of the cavity will prevent the establishment of an adequate seal (**extremely important**) during the period of repair. A radiopaque biocompatible base material (CaOH_2) should be placed over the remaining thin layer of caries at the base of the cavity and then the cavity is sealed with a durable interim restoration. Some interim restorative materials may also serve as the base material. The treated teeth should not be reentered for at least 6 to 8 weeks. During this time, the caries process in the deeper layer will be arrested. The rate of regular dentin formation observed during the indirect pulp treatment technique was highest during the first month.

If the decision is made to reenter the tooth after the minimum 6 to 8 week waiting period, the tooth is anesthetized and isolated with the rubber dam, and then removal of the temporary restorative material and calcium hydroxide dressing. Careful removal of the remaining carious material, sclerotic may reveal a sound base of dentin without an exposure of the pulp. If a second layer of dentin covers the pulp, a liner material containing calcium hydroxide is applied. The cavity preparation is completed, and then restoring the tooth in a conventional manner.



A, A primary or permanent tooth with deep caries. **B**, The gross caries has been removed and the cavity sealed with durable biocompatible cement or restorative material. **C**, Six to eight weeks later, the cavity is reopened and the remaining caries excavated. A sound dentin barrier protects the pulp, and the tooth is ready for final restoration.

**Notes:**

🤪 If caries process does not already expose the pulp, it will have a chance to form protective layer of secondary dentine during the waiting period, but if the caries process has already invaded the pulp and caused inflammation, the $(CaOH_2)$ and the temporary filling will help in neutralizing the irritant and will reduce the pulpal inflammation.

🤪 Treatment was judged successful if:

- ✓ The restoration was intact.
- ✓ The tooth had no history of pain after treatment and during the waiting period.
- ✓ The tooth had normal mobility.
- ✓ The tooth was not sensitive to percussion.
- ✓ There was no radiographic evidence of abnormal root resorption nor a radicular disease.
- ✓ There was no clinical evidence of direct pulp exposure when the tooth was reentered.

🤪 Its rationale is that carious dentin consists of two distinct layers. An outer layer irreversibly denatured that is infected, and not remineralizable which should be removed and an inner layer that is reversibly denatured, not infected (affected), remineralizable and which should be preserved.

Removing the outer layers of the carious dentin, that contain the majority of the microorganisms thus reducing the continued demoralization of the deeper dentin layers from bacterial toxins, and sealing the lesion to allow the pulp to regenerate reparative dentin.

Vital Pulp Exposure

Direct pulp capping

The placement of a medicament or non-medicated material on an exposed pulp that is occurred in course of excavating the last portions of deep dentinal caries or because of trauma.

Aim: To create new dentin in the area of the exposure and subsequent healing of the pulp.

Indications of Direct Pulp Capping:

Pulp-capping procedures should be limited to asymptomatic (absence of pain) vital primary teeth or young permanent teeth, with the possible exception of discomfort caused by the intake of food, the teeth should have:

- ☺ True pinpoint exposure (small mechanical exposure less than 1 mm) surrounded by sound dentin produced accidentally by trauma during cavity preparation.
- ☺ Mechanical or carious exposures less than 1 mm, in an asymptomatic vital young permanent tooth.
- ☺ The exposure site should have bright red hemorrhage easily controlled by dry cotton pellet with minimal pressure.
- ☺ Lack of bleeding at the exposure site (the amount of bleeding considered normal in the absence of a hyperemic or an inflamed pulp).

Contraindications:

- 1) Cariously exposed deciduous teeth
- 2) Spontaneous pain or severe toothache at night
- 3) Swelling
- 4) Fistula
- 5) Tenderness to percussion
- 6) Pathologic mobility
- 7) Root resorption—external/internal
- 8) Periapical/interradicular radiolucency
- 9) Pulp calcifications
- 10) Profuse hemorrhage from the exposure site
- 11) Pus or exudate from exposure site.

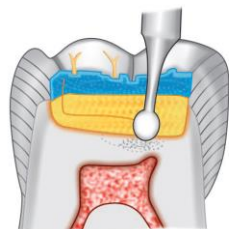
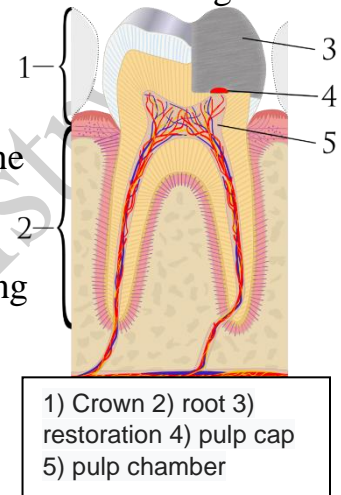
The clinical procedure

All pulp treatment procedures should be carried out with sterile instruments in clean conditions. Use of the rubber dam will help keep the pulp free of external contamination.

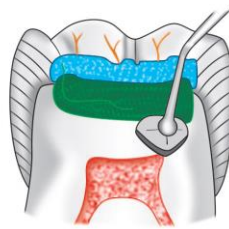
During caries removal if there is a pulpal exposure, necrotic and infected dentin chips could be pushed into the exposed pulp, and this can impede healing, causing further pulpal inflammation. Therefore while excavating caries from a deep cavity, it should be remembered that peripheral carious dentin from the walls should be removed first followed by removal from the floor of the cavity. Following a clinical exposure, use a nonirritating solution of normal saline (avoid the use of caustic solution because it may lead to pulpal injury) or anesthetic solution to cleanse the area and keep the pulp moist.

A blood clot formed after cessation of the bleeding, impedes the pulpal healing. Therefore, care must be taken not to allow clot formation. The clot formed does not allow the capping material to contact the pulp tissue directly, or the clot material itself could breakdown, producing degradation products that act as substrate to the bacteria.

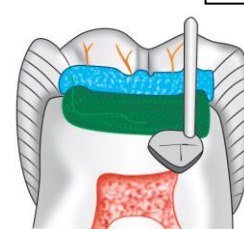
Then apply a pulp-capping agent over the exposure site and adequate seal following pulp capping is necessary to prevent bacterial contamination. Stainless steel crown restoration is the most preferred one.



Remove the caries with a slow-speed bur



Place calcium hydroxide over the exposed pulp



Direct pulp capping



Notes:

😊 Calcium hydroxide is the material of choice for pulp capping of normal permanent teeth with vital pulp tissue due to its good ability in stimulating the repair reaction. All pulps capped with Dycal responded satisfactorily with complete bridging with no evidence of inflammation of the pulp or obliteration of the canal.

😊 The use of mineral trioxide aggregate (MTA) and Biodentine as a capping material have shown promise.

😊 The capping material should:

- Stimulate reparative dentin formation
- Maintain pulpal vitality
- Be Bactericidal or bacteriostatic
- Adhere to dentin and to restorative material
- Resist forces during restoration placement and must resist forces under restoration during lifetime of restoration

- Able to be sterilized
- Radio-opaque
- Provide bacterial seal

Clinical success of direct pulp capping depends upon the following salient features:

- Maintenance of pulp vitality
- Lack of undue sensitivity or pain
- Minimum pulp inflammatory response
- Ability of the pulp to maintain itself without progressive degeneration.

Direct pulp capping is less preferred in primary teeth because:

Rapid spread of inflammation throughout the primary coronal pulp, due to increased blood supply. Therefore, there is less chance that the infection will be limited to the exposed part of the pulp increasing the likelihood of rapid and widespread of bacteria.

Baghdad College of Dentistry