
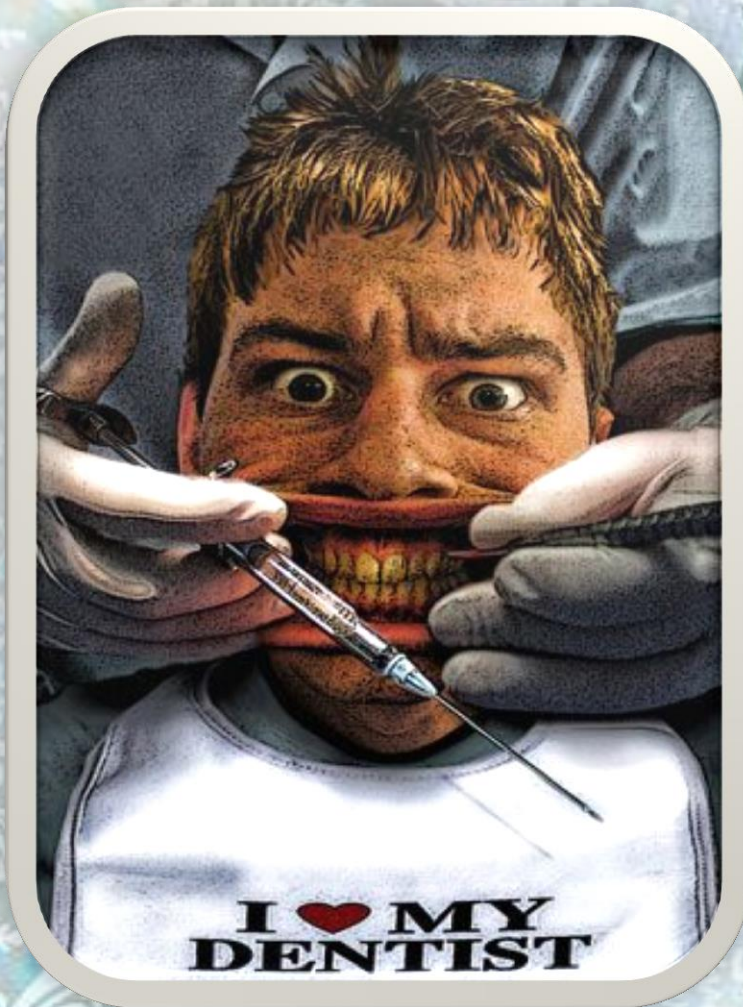


# Pediatric Dentistry



4<sup>th</sup> year



Lec. 25

## COMPLICATIONS AFTER LOCAL ANESTHESIA

Assistant Professor  
Zainab Juma Jafar

# COMPLICATIONS AFTER LOCAL ANESTHESIA

- ❖ **Local**—complications occurring locally in the region of injection.  
**Systemic**—complications impact on the general health.
- ❖ **Primary**—complications caused and manifested at the time of anesthesia.  
**Secondary**—complications manifested later, even though caused at the time of insertion of needle and injection.
- ❖ **Mild**—only slight changes produced which reverse without specific treatment.  
**Severe**—pronounced deviation from normally expected pattern and requires definite plan of treatment.
- ❖ **Transient**—complications may be severe but leaves no residual effect.  
**Permanent**—complications may be mild but leave a residual effect.

## Complications that are attributed to solution or insertion of needle

### Solution

- Toxicity
- Idiosyncrasy
- Systemic drug reactions
- Allergy and anaphylactoid reactions
- Infection caused by contaminated solution
- Local irritation/tissue reaction

### Insertion of needle

- Syncope
- Muscle trismus
- Pain/hyperalgesia
- Edema
- Infection
- Broken needle
- Hematoma and sloughing of tissues
- Facial nerve paralysis
- Burning on injection

Complications can be classified as **generalized** and **localized**, and divided into **early** and **late**.

## GENERALIZED COMPLICATIONS:

### Psychogenic

*The most common psychogenic complication of LA is fainting. The chances of this happening are reduced by sympathetic management and administration of the anesthetic to children in the semi-supine position.*

### Allergy

*Allergy to local anesthetics is a very rare occurrence. Allergy can manifest in a variety of forms, ranging from a minor localized reaction to the medical emergency of anaphylactic shock. If there is any suggestion that a child is allergic to a local anesthetic they should be referred for allergy testing to the local dermatology or clinical pharmacology department.*

*Children who are allergic to latex merit consideration as this material is included in the rubber plungers of some cartridges.*

### Toxicity

*Overdosage of local anesthetics leading to toxicity is rarely a problem in adults but can occur in children. Children over 6 months of age absorb local anesthetics more rapidly than adults; however, this is balanced by the fact that children have a relatively larger volume of distribution and elimination is also rapid because of a relatively large liver. The maximum dose of lidocaine is 4.4 mg/kg.*



## Treatment of toxicity

The best treatment of toxicity is prevention. Prevention is aided by:

- Aspiration
- Slow injection
- Dose limitation.

When a toxic reaction occurs, the procedure is as follows:

1. Stop the dental treatment.
2. Provide basic life support.
3. Call for medical assistance.
4. Protect the patient from injury.
5. Monitor vital signs.

## Cardiovascular effects

*Result from the combined action of the anesthetic agent and the vasoconstrictor. Local anesthetics affect the cardiovascular system by their direct action on cardiac tissue and the peripheral vasculature. They also act indirectly via inhibition of the autonomic nerves that regulate cardiac and peripheral vascular function. Adrenaline has both direct and indirect effects on the heart. The doses used in clinical dentistry will increase cardiac output, although this is unlikely to be hazardous in healthy children. Felypressin at high doses causes coronary artery vasoconstriction.*

## CNS effects

*The fact that local anesthetic agents influence activity in nerves other than peripheral sensory nerves is obvious to any practitioner who has inadvertently paralysed the peripheral branches of the motor facial nerve during an alveolar nerve block injection. At low doses the effect is excitatory as CNS inhibitory fibers are blocked; at high doses the effect is depressant and can lead to unconsciousness and respiratory arrest. Fatalities due to*

local anesthetic overdose in children are generally the result of CNS depression.

## Methaemoglobinaemia

Some local anesthetics cause specific adverse reactions when given in overdose. Prilocaine causes cyanosis due to methaemoglobinaemia. In methaemoglobinaemia the ferrous iron of normal haemoglobin is converted to the ferric form, which cannot combine with oxygen.

## Infection

The introduction of agents capable of producing a generalized infection, such as human immunodeficiency virus (HIV) infection and hepatitis, is a complication that should not occur when appropriate cross-infection control measures are employed.

## EARLY LOCALIZED COMPLICATIONS

### Pain

Pain resulting from local anesthetic injections can occur at the time of the injection as a result of the needle penetrating the mucosa, too rapid injection, or injection into an inappropriate site. The sites at which injection may be painful include intra-epithelial, sub-periosteal, into the nerve trunk, and intravascular.

An **intra-epithelial** injection is uncomfortable because at the start of the injection the solution does not disperse and this causes the tissues to balloon out.

**Sub-periosteal** injections may produce pain both at the time of injection and postoperatively. The initial pain is due to injection into a confined

space, with the delivery of solution causing the periosteum to be stripped from the bone.

Direct contact of the nerve trunk by the needle produces a sensation similar to an electric shock and immediate anesthesia. This is most likely to occur during inferior alveolar nerve blocks. If the needle does contact the nerve, the patient and parent should be warned that anesthesia of the nerve may be prolonged. Altered sensation may last up to a few weeks in some cases.

Accidental intravascular injections can occur in children if aspiration is not performed. It can cause local pain if the vessel penetrated is an artery and arterial spasm occurs. Intravenous injections can produce systemic effects such as tachycardia and palpitations. Intra-arterial injections are much rare; however, the consequences can be alarming. Such effects range from local pain and cutaneous blanching to severe intracranial problems.

### Failure of local anesthesia

The inability to complete the prescribed treatment because of failure of the local anesthesia can be the result of number of causes, including anatomy, pathology, and operator technique.

Anatomical causes can result from either bony anatomy or accessory innervation. Bony anatomy can inhibit the diffusion of a solution to the apical region when infiltration techniques are used. This can occur in children in the upper first permanent molar region as a result of a low zygomatic buttress. To overcome this problem the anesthetic solution is infiltrated both mesially and distally to the upper first molar/zygomatic buttress region.

Accessory innervation may also produce failed LA in the upper molar region. This may be the consequence of pulpal supply from the greater palatine nerves, which can be blocked by supplementary palatal anesthesia. In the mandible, accessory supply from the mylohyoid, auriculotemporal, and cervical nerves will not be blocked by inferior alveolar, lingual, and long buccal nerve blocks and may require supplementary injections. The most common area of accessory supply occurs near the midline, where bilateral supply often necessitates supplemental injections when regional block techniques are employed.

The presence of acute infection interferes with the action of local anesthetics. This is partly because of the reduction in tissue PH decreases the number of un-ionized local anesthetic molecules, which in turn inhibits their diffusion through lipid to the site of action. More importantly, nerve endings stimulated by the presence of acute infection are hyperalgesic. Regional block and intra-ligamental methods of LA depend on technique, and failure of these forms of LA is often the result of operator error. This cause of failure becomes less common with experience. Infiltration anesthesia is a very simple method that is readily mastered by novices. When this injection fails, reasons other than operator technique should be sought.

### Motor nerve paralysis

Paralysis of the facial nerve can occur following deposition of local anesthetic solution within the substance of the parotid gland because of malpositioning of the needle during inferior alveolar nerve block injections. The terminal branches of the facial nerve run through the parotid gland and will be paralysed by the anesthetic agent. The most dramatic manifestation



*of this complication is the loss of ability to close the eyelids on the affected side. Although paralysis of the eyelid is most often due to faulty technique during inferior alveolar nerve block anesthesia, it can also result from the use of excessive amounts of solution in the maxillary buccal sulcus.*

### **Interference with special senses**

*Such as vision and hearing after the intra-oral injection of LA. Such occurrences most probably result from accidental intra-arterial injections.*

### **Haematoma formation**

*Penetration of a blood vessel can occur during local anesthetic administration. However, haematoma formation is rarely a problem unless it occurs in muscle following inferior alveolar nerve block techniques when it may lead to trismus.*

## **LATE LOCALIZED COMPLICATIONS**

### **Self-inflicted trauma**

*It may occur after LA in children. It may follow regional techniques in the mandible and infiltration anesthesia in the maxilla. The most common site is the lower lip, but the tongue and upper lip can also be affected. It can be prevented by adequate explanation to the patient and parent by the clinician. The use of periodontal ligament techniques may reduce the frequency of this complication. However, it must be stressed that soft tissue anesthesia is not completely avoided with this method in all cases.*

*If the injury occurs, the injured area should be kept clean. If the injury is on the lips or outside cheeks, application of a skin ointment or petroleum jelly is recommended. If the injury is in the mouth, application of a mild oral antiseptic is recommended. The area will generally heal in seven to ten days. However, if there is significant swelling in the surrounding tissue*



areas, the child should be examined as antibiotic drug therapy may be necessary.

### Oral ulceration

Occasionally children will develop oral ulceration few days after LA. This is usually the result of trauma initiating an aphthous ulcer. On rare occasions, needle trauma may activate a latent form of herpes simplex.

### Long-lasting anesthesia

As mentioned above, long-lasting anesthesia can result from direct trauma to a nerve trunk from the needle or injection of solution into the nerve. This may occur after regional block techniques, but it is a rare complication.

### Trismus

Trismus may follow inferior alveolar nerve block injections and is usually the result of bleeding within muscle following penetration of a blood vessel by the needle. Injection of a solution directly into muscle tissue may also result in trismus. The condition is self-resolving, although it may take a few weeks before normal opening is restored.

### Infection

Localized infection due to the introduction of bacteria at the injection site is a complication that is rarely encountered.

### Developmental defects

Local anesthetic agents are cytotoxic to the cells of the enamel organ. It is possible that the incorporation of these agents into the developing tooth-germ could cause developmental defects. There is experimental evidence that such defects can arise following intra-ligamental injections in primary teeth in animal models. Such occurrences in humans have not been reported. In addition, it is possible that physical damage caused by the needle to permanent successors could result from the over-enthusiastic use of intra-ligamentary anesthesia in the primary dentition.