



Epithelial Tissue

by Rasha Mohammed

Epithelial tissue or Epithelium is one of the four basic types of body tissue, The other three types are connective tissue, muscle tissue and nervous tissue, These tissues vary in their composition and their function.

- **Epithelial tissue** is a sheet of cells that covers a body surface(forms the outer layer of the skin) , lines a body cavity(lines open cavities of the digestive and respiratory systems , lining blood vessels) or Glandular epithelium- surrounds glands within the body
- Functions of epithelial Tissue include
- 1)secretion 2)excretion 3) absorption 4) protection 5)sensing 6) filtration

Classification of epithelium

- Classification of epithelium is based on the shape of the cells and the arrangement of the cells within the tissue. Typically, the arrangement of the cells is stated first, then the shape, and is followed by "epithelium" to complete the naming (Ex. Simple Squamous Epithelium)
- **Arrangements:**
- **Simple**- Cells are found in a single layer attached to the basement membrane
- **Stratified**- Cells are found in 2 or more layers stacked atop each other
- **Pseudostratified**- a single layer of cells that appears to be multiple layers due to variance in height and location of the nuclei in the cells
- **Shapes:**
- **Squamous**: flat, thin, scale-like cells
- **Cuboidal**- cells that have a basic cube shape. Typically the cell's height and width are about equal.
- **Columnar**- tall, rectangular or column-shaped cells. Typically taller than they are wide.



EPITHELIA TISSUE

➤ 1) Covering and lining tissue

➤ Simple epithelial tissue

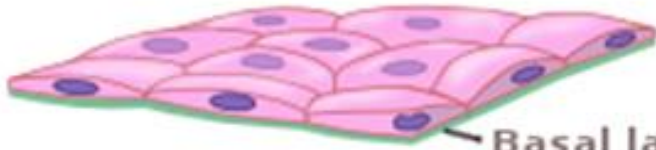- 1. Simple squamous epithelial tissue
- 2. Simple columnar epithelial tissue.
- 3. Simple cuboidal epithelial tissue

➤ Stratified epithelial tissue

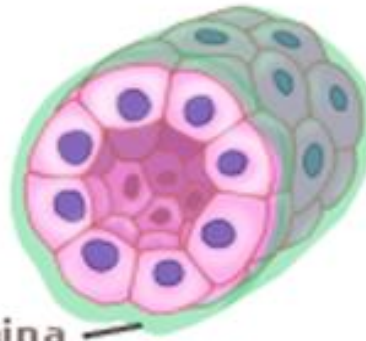
- 1) stratified columnar epithelial tissue
- 2) Stratified squamous epithelial tissue e. a. Keratinized b. non-keratinized
- 3) Stratified cuboidal epithelial tissue
- 4) Transitional epithelial tissue

SIMPLE

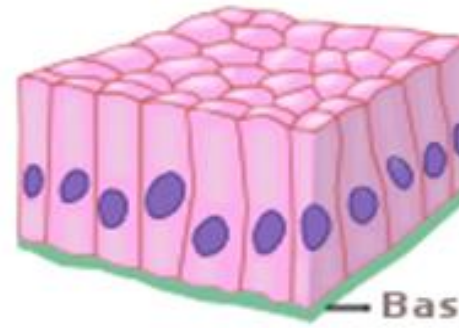
Simple squamous



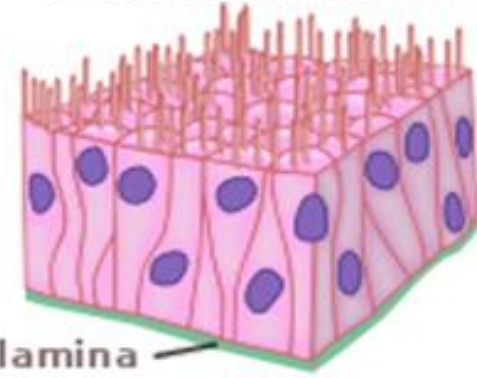
Simple cuboidal



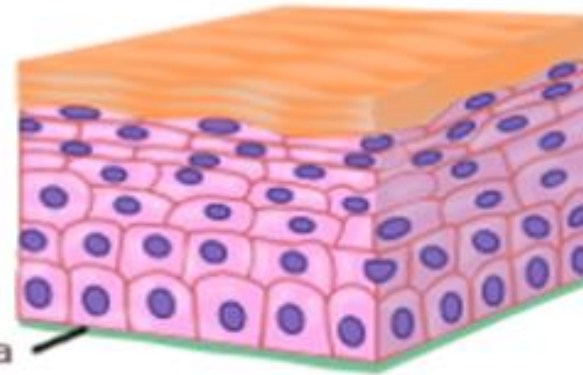
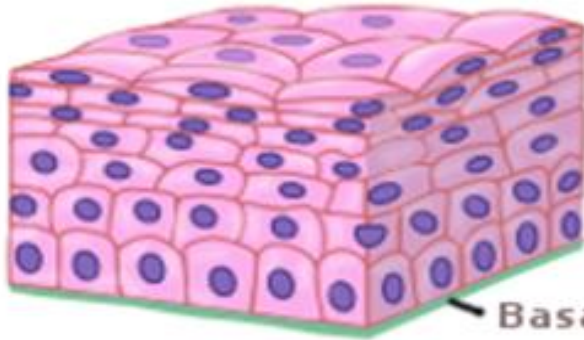
Simple columnar



Pseudostratified

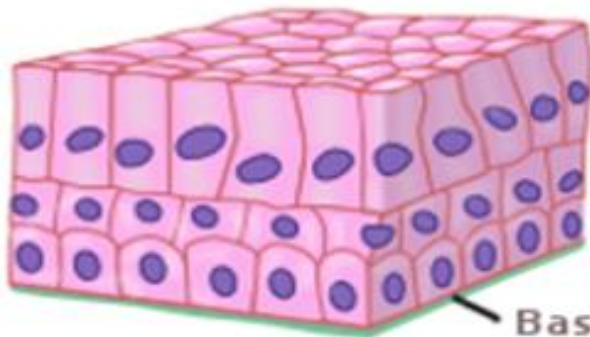


Stratified squamous

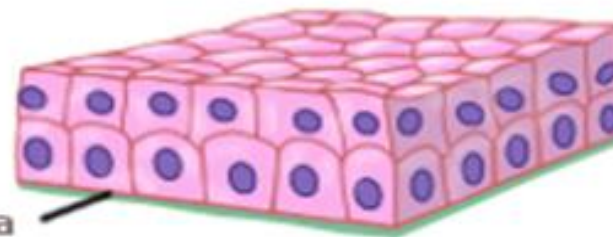


Keratinized stratified squamous

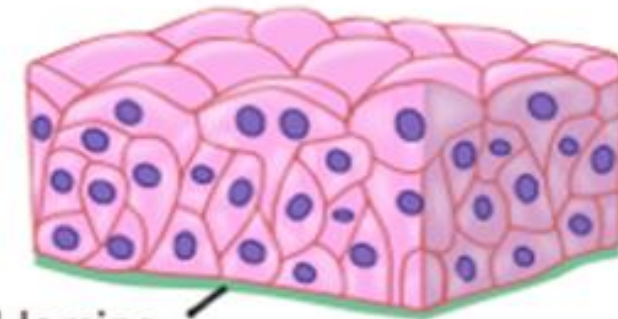
Stratified columnar



Stratified cuboidal



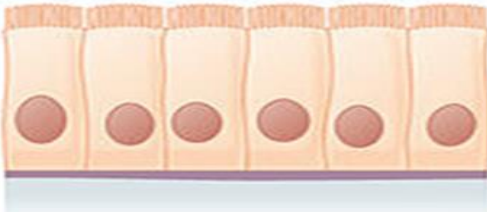
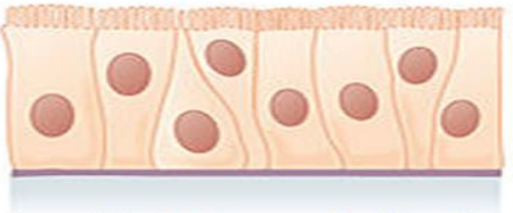


Transitional

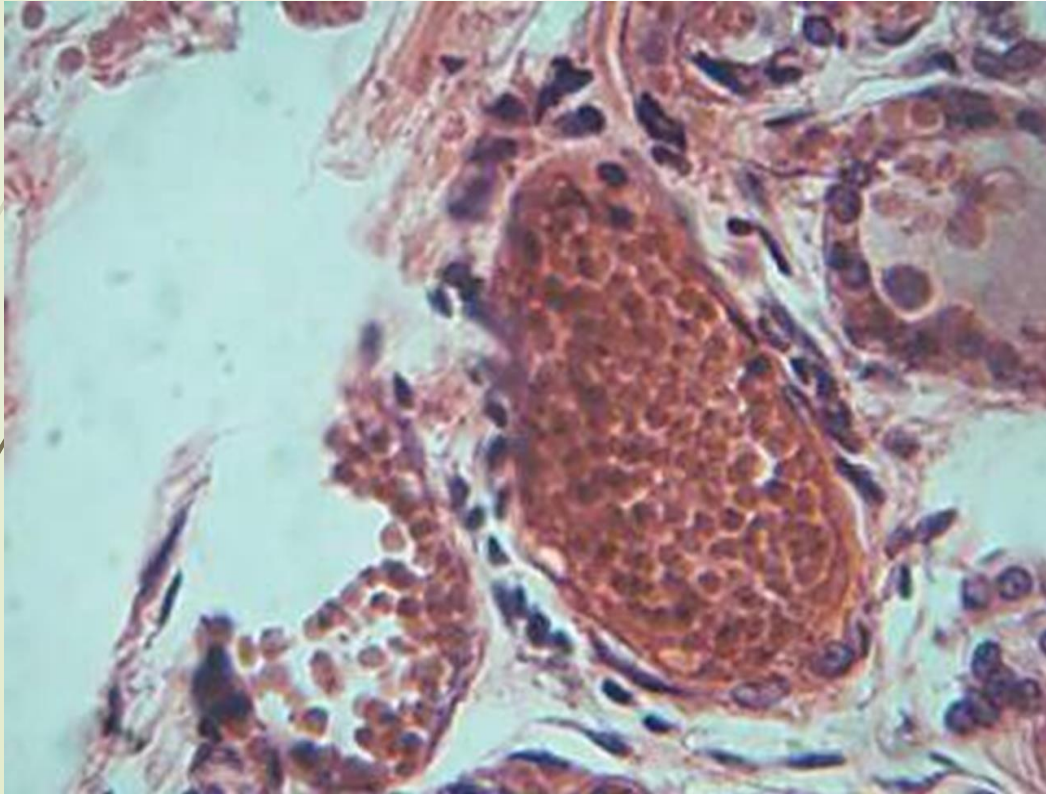


STRATIFIED

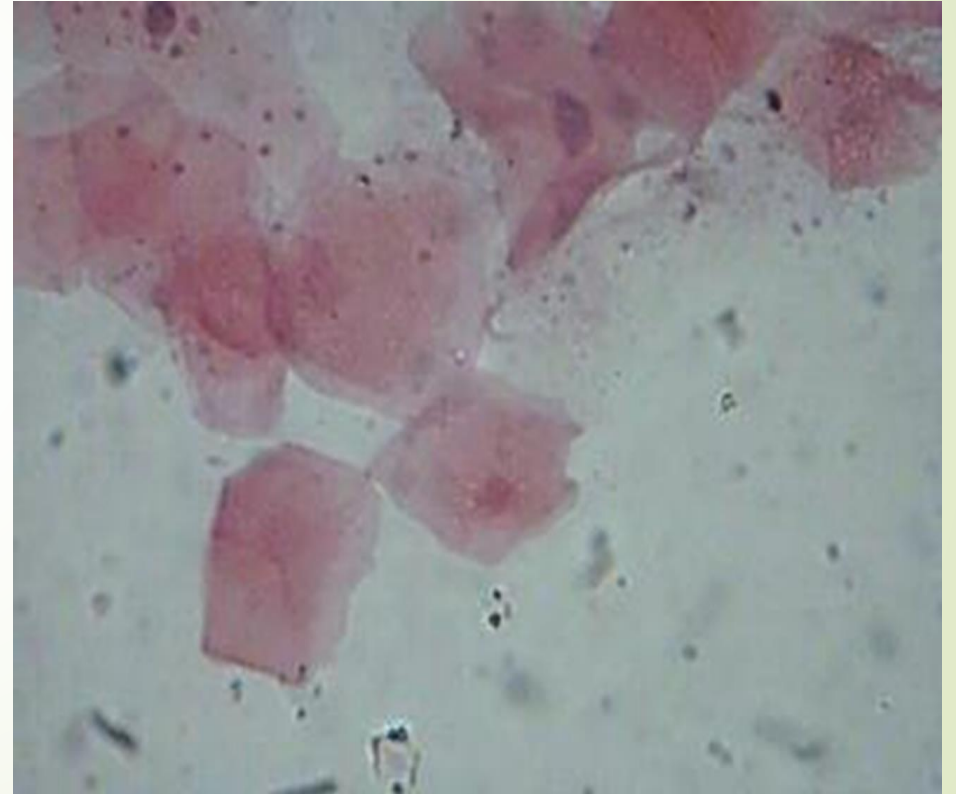Simple epithelial tissue

Cells	Location	Function
<p>Simple squamous epithelium</p>  <p>Description: Single layer of flattened cells with disk-shaped central Nuclei and sparse cytoplasm</p>	<p>Bowman's capsule in kidneys, lungs, endothelium of blood vessels.</p>	<p>Allows materials to pass through by diffusion and filtration, and secretes lubricating substance</p>
<p>Simple cuboidal epithelium</p>  <p>Description: Single layer of eube-like cells with large, spherical central nuclei</p>	<p>:thyroid gland, kidney tubules and ovary surface.</p>	<p>Secretes and absorbs</p>
<p>Simple columnar epithelium</p>  <p>Description: Single layer of with oval nuclei layer may contain mucus-secreting glands (goblet cells).</p>	<p>Ciliated tissues are in bronchi, uterine tubes, and uterus; smooth (nonciliated tissues) are in the digestive tract, bladder</p>	<p>Absorbs; it also secretes mucous and enzymes</p>
<p>Pseudostratified columnar epithelium</p>  <p>Description: Single layer of cells of differing heights some not reaching the free surface, nuclei seen at different levels ,may contain goblet cells and bear cilia.</p>	<p>Ciliated tissue lines the trachea and much of the upper respiratory tract</p>	<p>Secretes mucus; ciliated tissue moves mucus</p>

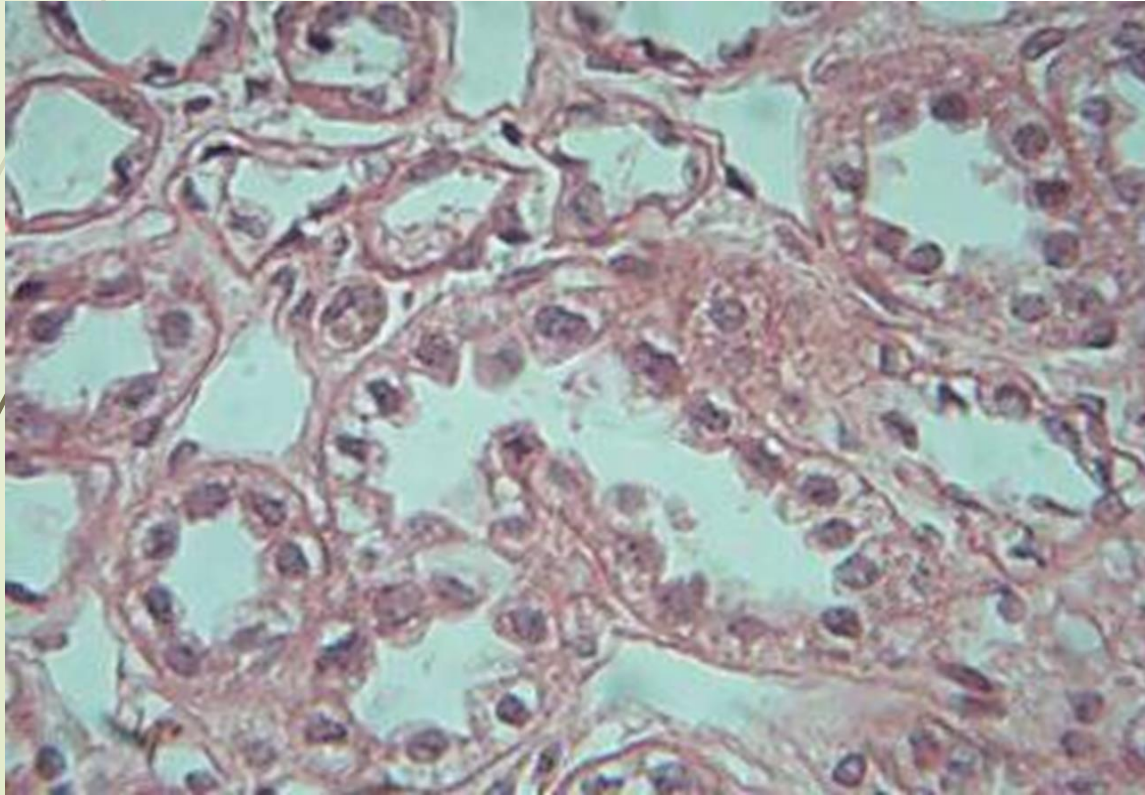
**Simple squamous epithelial tissue
(kidney)**



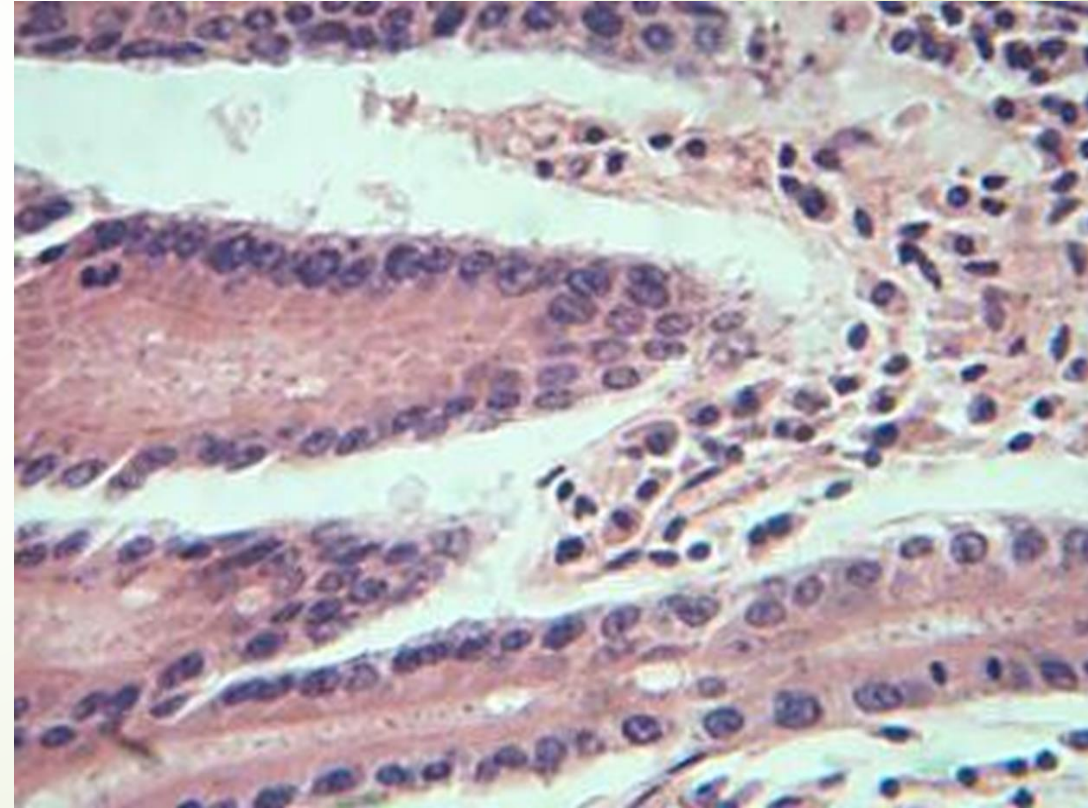
**Simple squamous epithelial tissue
(mouth)**



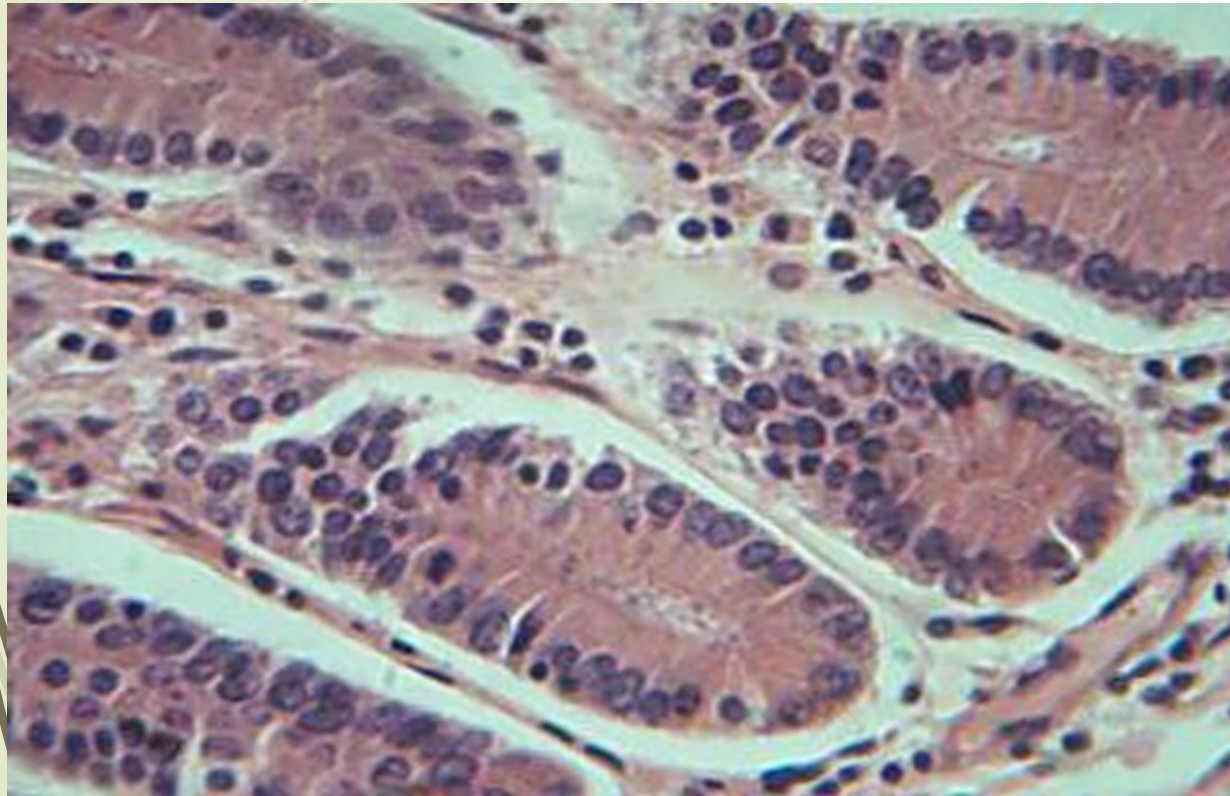
Cuboidal epithelial tissue
(thyroid)



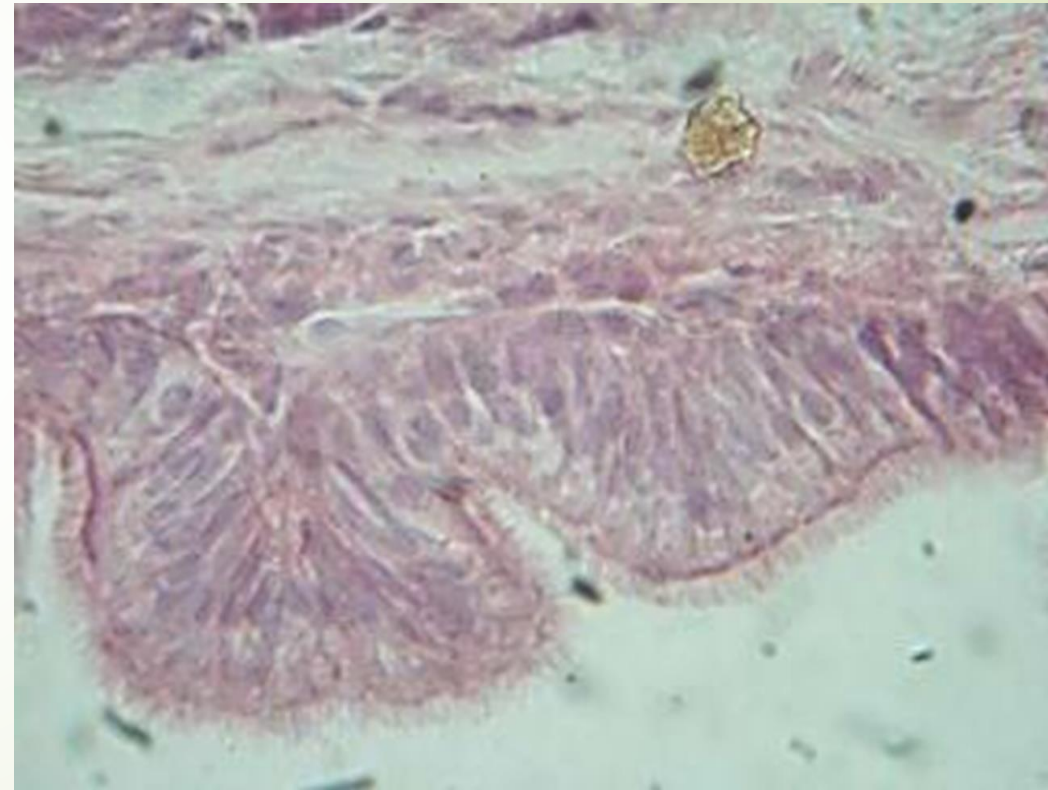
Simple columnar epithelial tissue
(Duodenum)



Simple columnar epithelial tissue(Kidney)



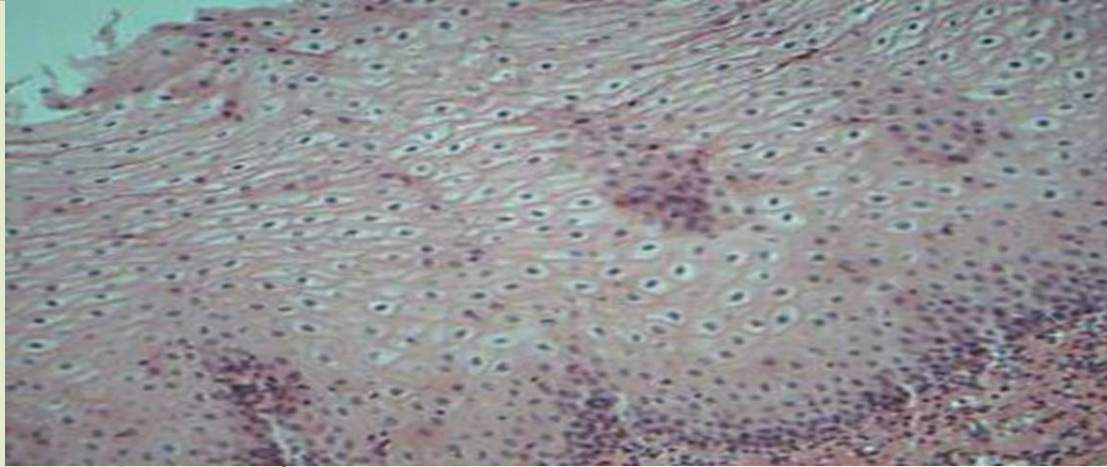
Pseudostratified epithelial tissue(Trachea)



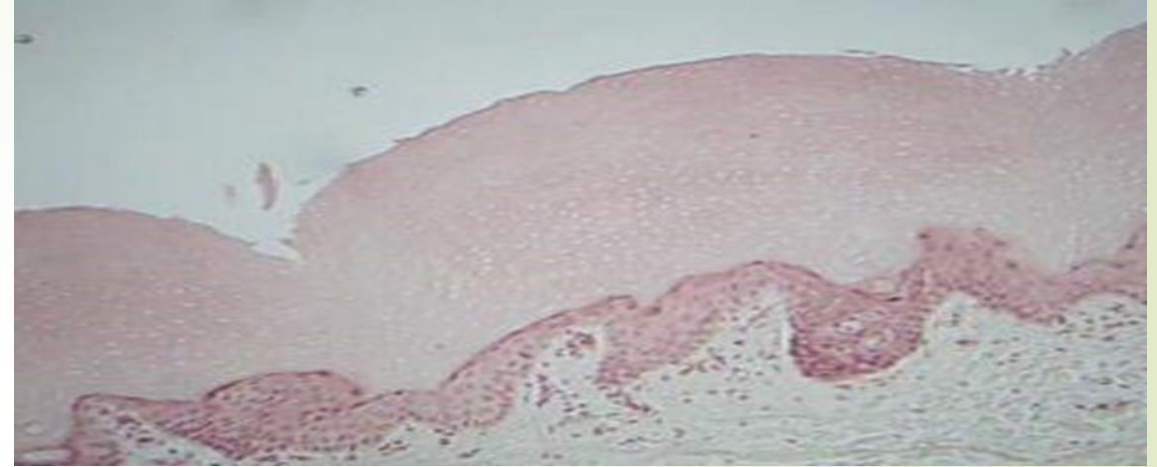
Stratified epithelial tissue

cells	Location	Function
<p>1) Stratified squamous epithelium : Description : Thick membrane composed of several cell layers, basal cells are cuboidal or columnar and metabolically active, surface cells are flattened (squamous); in the keratinized type the surface cells full of keratin and dead ,basal cells are active in mitosis and produce the cells of the more superficial layers.</p>	<p>Non-keratinized Oral cavity, esophagus, pharynx and vagina keratinized epidermis of the skin</p>	<p>Protects underling tissue in areas subjected to abrasion</p>
<p>2- Stratified columnar epithelium: Description : several cell layers, basal cells usually cuboidal ,superficial cells elongated and columnar</p>	<p>pharynx, male urethra, and lining of some glandular ducts.</p>	<p>Protection and secretion.</p>
<p>3- Stratified cuboidal epithelium: Description : Generally two layers of cube- like cells.</p>	<p>It's mainly found in the ducts of glands (sweat glands, parotid gland and mammary glands)</p>	<p>Protection</p>
<p>4-Transitional epithelium: Description : resembles both stratified squamous and stratified cuboidal, basal cells cuboidal or columnar, surface cells dome shaped or squamous- like depending degree of organ stretch</p>	<p>Lines the ureter, urinary bladder and part of urethra.</p>	<p>Stretches readily and permits distention of urine organ by contained urine.</p>

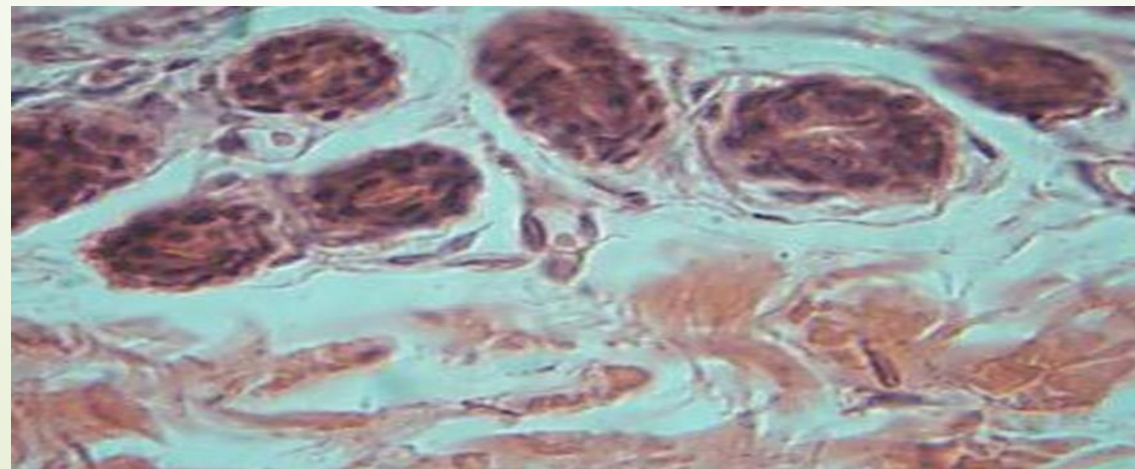
Stratified squamous epithelium
Non-keratinized esophagus



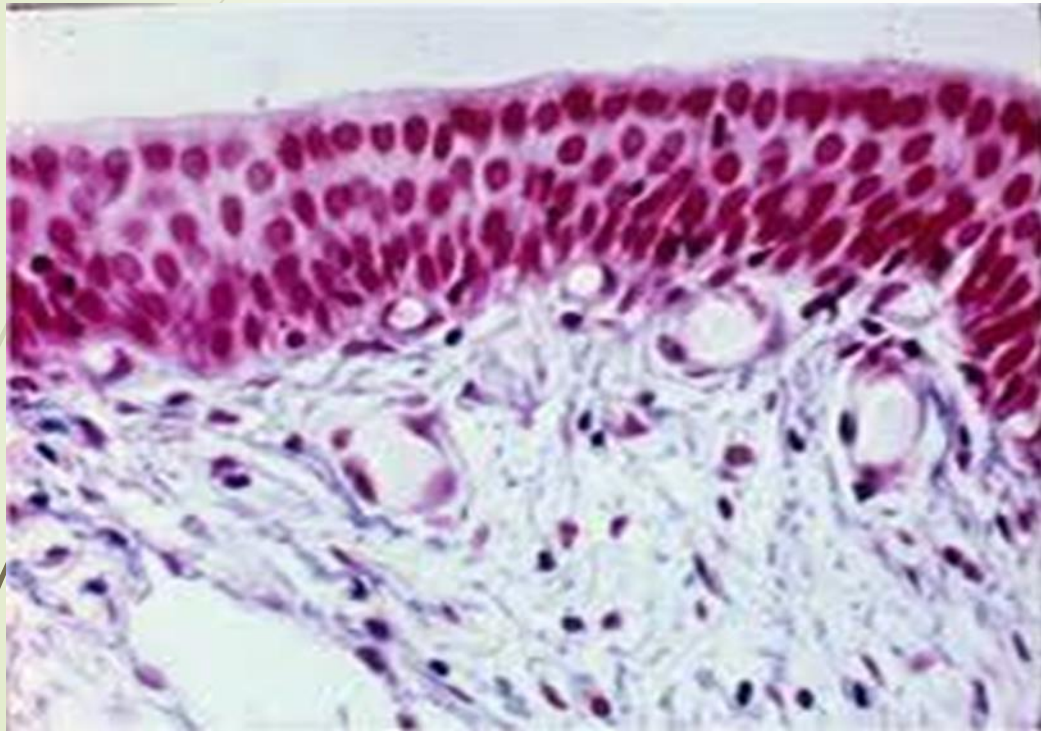
Stratified squamous epithelium
keratinized epidermis of the skin



Stratified Cuboidal Epithelial Tissue



Stratified Columnar Epithelial Tissue



Transitional Epithelial Tissue

