

Radiographical appearance of ameloblastoma

INTRODUCTION

Ameloblastoma, is derived from the English word “amel” which means enamel and the Greek word “blastos” which means the germ. It arises from the epithelium of the dental lamina, and it is characterized by its local aggressive behavior and a high recurrence rate. Ameloblastoma was first described in 1827 by Cusack. **(Cusack, 1827)**

In 1885, Malassez introduced the name “adamantinoma,” which is presently used to illustrate a rare form of bone cancer described by Fisher in 1913. It was first detailed and described by Falkson in 1879. The term ameloblastoma was coined by Ivey and Churchill in 1930, **(Cakur, 2009)**

A currently accepted term. It is considered as a true neoplasm as the name implies it mimics the cells of the enamel-forming organ. It was described by Robinson in 1937, as a benign tumor that is “usually unicentric, nonfunctional, intermittent in growth, anatomically benign and clinically persistent.” The World Health Organization (WHO) (1991) defined ameloblastoma as a benign but locally aggressive tumor with a high tendency to recur, consisting of proliferating odontogenic epithelium lying in a fibrous stroma. **(Kramer , 1992)**

They are rare, odontogenic tumors, thought to be composed of the epithelium of ectodermal origin, which means they are tumors arising from the cells around the tooth root, or in close approximation, derived from the ectoderm germ layer. Ameloblastomas represent about 1% of all jaw tumors, but they are the second-most common odontogenic tumor. They are much more common in the lower jaw than in the upper jaw and more common in the posterior mandible as compared to the anterior. The vast majority of the time, they are a benign tumor with aggressive behavior; however, rarely they can develop into, or be associated with, a

Radiographical appearance of ameloblastoma

malignancy (malignant ameloblastoma or ameloblastic carcinoma). It is extremely rare to find ameloblastomas outside the maxilla and mandible due to the association with teeth and their structures. **(Madhup , 2006)**

Natural History: The vast majority of ameloblastomas are benign and slow-growing, with locally aggressive behavior, which can lead to significant pathology and require extensive surgical treatment. The abnormal cell growth easily infiltrates local tissue, typically bone. Surgical excision is usually needed to treat this disorder. It has a high propensity for local recurrence even with proper surgical management and requires lifelong follow up for surveillance . Patterns of spread: Amelomlastomas spread locally, invading surrounding tissues. They spread through bone and can invade soft tissues as well if given enough time to do so. However, this is a benign tumor so metastasis to lymph nodes, distant sites, etc., is rare and changes the staging to malignant. The thinking is that malignant ameloblastomas comprise less than 1% of all ameloblastomas. **(Mahmoud , 2018)**

The tumor may be asymptomatic initially, later on becoming expansible and during this process the compartments may fuse together to form a large unilocular space. The tumor can also perforate the cortical plate. The classical radiographic appearance is multilocular. The multilocular appearance may be either of the honeycomb type or soap-bubble type. The lesion can cause resorption of roots of the teeth. If it occurs in the maxilla it produces a monocystic lesion. Sometimes even in the mandible the lesion can occur as a unilocular lesion **(Pramod, 2011)**.

Aims of the Review

- Describe the pathophysiology of ameloblastoma.
- To analyze cases of ameloblastoma, with emphasis on the radiographic findings. We also review the current literature briefly and discuss the clinical and radiographic findings

Chapter one: Review of Literature

1.1 Ameloblastoma

Ameloblastoma is a rare, benign, slow-growing, tumour of the bone which can occur in the lower or upper jaw bone. It is very common for this tumor to occur around the position of the third molar tooth. Approximately 80% occur in the mandible and the other 20% in the maxilla. Ameloblastoma in the mandible can progress to great size and cause facial asymmetry, displacement of teeth, malocclusion, and pathologic fractures. (Pramod, 2011)

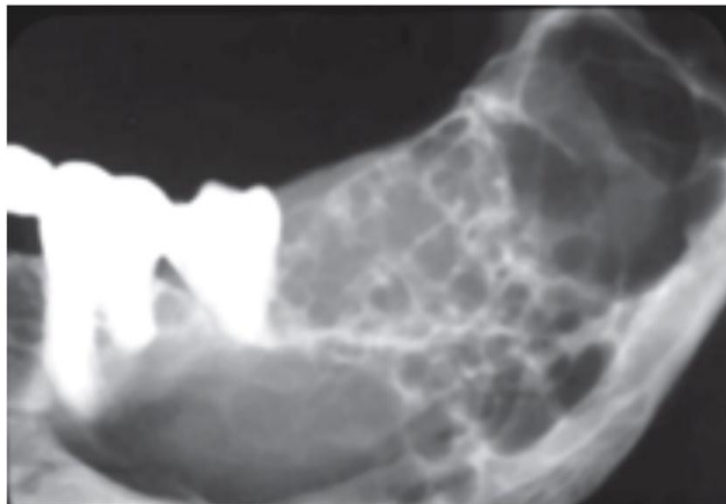


Figure 1: Ameloblastoma of mandible (Pramod, 2011)

1.1.1 Etiology

Ameloblasts are of ectodermal origin and derived from oral epithelium. The cells are only present during tooth development that deposit tooth enamel, which forms the outer surface of the crown. Ameloblasts become functional only after odontoblasts form the primary

Radiographical appearance of ameloblastoma

layer of dentin (the Layer beneath enamel). The cells eventually become part of the enamel epithelium and eventually undergo apoptosis (cell death) before or after tooth eruption. There exist deposits of these cells in the structures in and around the tooth, termed cell rests of Malessez and cell rests of Series. Current thought is that ameloblastomas can arise from either the cells mentioned above or other cells of ectodermal origin, such as those associated with the enamel organ. **(Palanisamy and Jenzer , 2022).**

1.1.2 Epidemiology

Ameloblastomas can occur over a broad age range, and most commonly affect patients between the ages of 20 to 40 years. They are uncommon in children younger than ten years. Males and females are equally affected. Ameloblastomas are located most commonly in the posterior mandible, with fewer tumors arising in the maxilla. **(Mahmoud , 2018)**

1.1.3 Pathophysiology

The cause of ameloblastoma is not well understood. There is recent evidence that genetic mutations that activate a specific signaling pathway (MAPK) play a role in the pathogenesis of ameloblastoma. Further understanding of the molecular basis of tumorigenesis will have implications for diagnosis and therapy. **(Palanisamy and Jenzer , 2022)**

1.1.4 History and physical

Ameloblastomas usually are asymptomatic until the patient notices intraoral or facial swelling. Patients often present with progressive maxillary or mandibular expansion and facial asymmetry. Pain and altered sensation are uncommon. Patients may complain of a change in bite and loose teeth. Smaller tumors are usually detected first on routine

Radiographical appearance of ameloblastoma

dental radiographic exams. Untreated tumors can grow to massive proportions and cause facial deformity, as exhibited, especially in third world countries where patients can go for long periods before seeking treatment or having access to care. (Palanisamy and Jenzer , 2022).

1.2 Classification

Ameloblastoma is classified, according to WHO and the International Agency for Research on Cancer, 2003, as a benign tumor with odontogenic epithelium, mature fibrous stroma and without odontogenic ectomesenchyme. Ameloblastoma is further classified into:

- a. Solid/multicystic
- b. Extraosseous/peripheral
- c. Desmoplastic ameloblastoma
- d. Unicystic.

a- Solid/Multicystic Ameloblastoma

The solid or multicystic ameloblastoma is a benign epithelial odontogenic tumor of the jaws. Nakamura , 2001 .It is slow-growing locally aggressive and accounts for about 10% of all odontogenic tumors in the jaw. (Mendenhall , 2007)

Solid multicystic ameloblastoma (SMA) occur as growths arising from remnants of odontogenic epithelium, exclusively from rests of the dental lamina. SMAs may also arise as a result of neoplastic changes in the lining or wall of a non-neoplastic odontogenic cyst, in particular dentigerous and odontogenic keratocysts. (Peter , 2004)

Radiographically SMAs show an expansile, radiolucent, multiloculated cystic lesion, with a characteristic “soap bubble-like”

Radiographical appearance of ameloblastoma

appearance. Other findings include cystic areas of low attenuation with scattered regions representing soft tissue components. Thinning and expansion of the cortical plate with erosion through the cortex is elicited, with the associated unerupted tooth displaced and resorption of the roots of adjacent teeth common. **(Dunfee , 2006)**

Mostly this type is diagnosed in young adults, with a median age of 35 years and no gender predilection. About 80% of ameloblastomas occurs in the mandible, **(Becelli , 2002)** .frequently in the posterior region. **(Mendenhall , 2007)**

The main modality of treatment is surgery, with wide resection recommended due to the high recurrence rate of solid/multicystic ameloblastomas. The recurrence rate after resection is 13-15%, as opposed to 90-100% after curettage. Recommend a margin of 1.5-2 cm beyond the radiological limit is implicated to ensure all micro cysts are removed. **(Chapelle , 2004)**

Six histopathologic subtypes of solid ameloblastoma include follicular, plexiform, acanthomatous, basal cell, granular and DA. Mixtures of different histological patterns are commonly observed, and the lesions are frequently classified based on the predominant pattern present. The follicular pattern type has the highest recurrence rate of 29.5% and acanthomatous type having the least recurrence rate of 4.5%, and the rate of recurrence depends on the histologic subtypes. **(Hong , 2007)**

Radiographical appearance of ameloblastoma

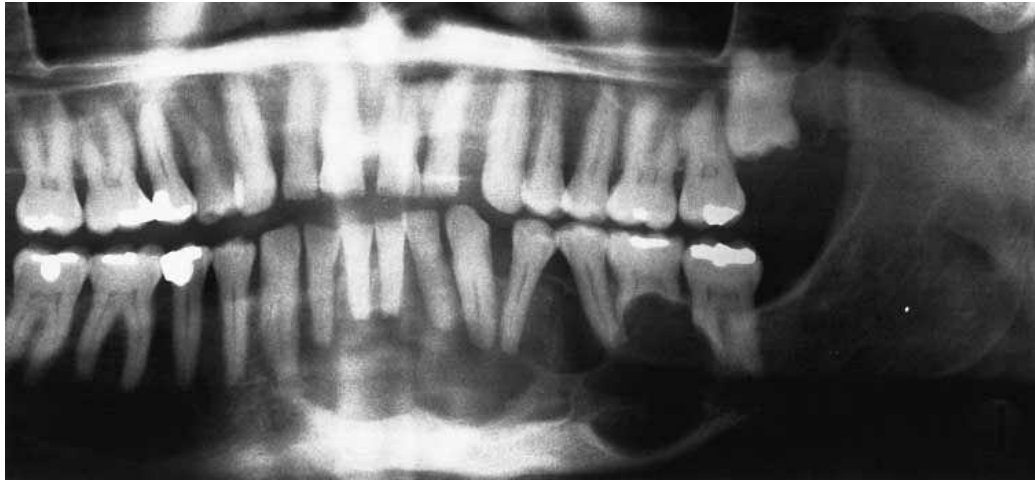


Figure 2: Typical appearance of a multicystic ameloblastoma of the left mandible. Note some spreading of the teeth and the root resorption. (Sanjay et al, 2020)

b- Peripheral Ameloblastoma

The peripheral ameloblastoma (PA) is defined as an ameloblastoma that is confined to the gingival or alveolar mucosa. It infiltrates the surrounding tissues, mostly the gingival connective tissue, but it does not involve the underlying bone. **(Gardner , 1984)**

The PA arises from remnants of the dental lamina, the so-called “glands of Serres,” odontogenic remnants of the vestibular lamina, pluripotent cells in the basal cell layer of the mucosal epithelium and pluripotent cells from minor salivary glands. **(Isomura , 2009)**

The PA is an exophytic growth restricted to the soft tissues overlying the tooth-bearing areas of the jaws, the initial diagnosis often mistaken for fibrous epulis. In the majority of cases, there is no radiological evidence of bone involvement, but a superficial bone erosion known as cupping or saucerization may be detected at surgery. The overall average age is 52.1 years, slightly higher for males than for females. The

Radiographical appearance of ameloblastoma

male/female ratio is 1.9: 1, as opposed to 1.2: 1 for the solid type. The maxilla/mandible ratio is 1: 2.6. (Philips , 2001)

The mandibular premolar region accounts for 32.6% and is the commonest site. The PA is mostly treated with a wide local excision. 9% of recurrence following treatment has been reported, though malignant transformation is rare, metastasis has also been reported (Buchner , 1987; Lin , 1987)

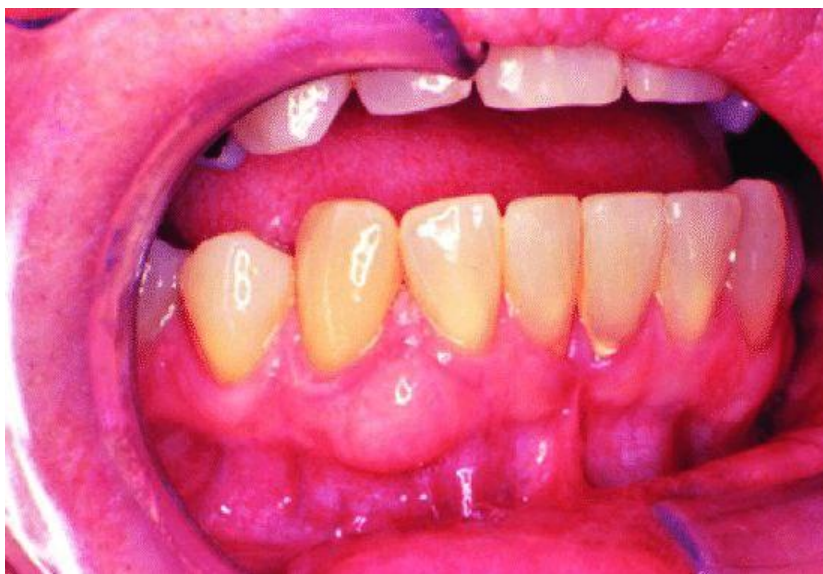

Figure 3: Extraosseous ameloblastoma. Mucosal nodular lesion (John and Merva, 2017)

c- Desmoplastic Ameloblastoma

Desmoplastic ameloblastoma was first reported by Eversole et al. in 1984 and was recently included in the WHO's classification of head and neck tumors (WHO-2005). Eversole , 1984;

This tumor is characterized by an unusual histomorphology, including extensive stromal collagenization or desmoplasia, leading to the proposed term ameloblastoma with pronounced desmoplasia or DA. Richard, 2004.

Radiographical appearance of ameloblastoma

Radio graphically it produces mixed radiolucent - radiopaque lesion with diffuse border that indicates that the tumor is more aggressive than other variants of ameloblastoma. **Mintz , 2009**

Mixed radiologic appearance expresses the infiltrative pattern of the tumor and when the DA infiltrates the bone marrow spaces, remnants of the original nonmetaplastic or no neoplastic bone were found to remain in the tumor tissue. The infiltrative behavior of the DA explains one of the characteristic features of the tumor, the ill-defined border. **Peter , 2004**

The DA also appears as a poorly defined, mixed, radiolucent-radiopaque lesion mimicking a benign fibro-osseous lesion, especially when evaluating panoramic and periapical radiographs. **Sun , 2009**

About 15.9% rate of recurrence has been reported in DA cases treated by enucleation and/or curettage, with an average recurrence period of 36.9 months. The majority of DA cases reported treated by resection, most likely due to ill-defined borders, **Manuel , 2002**

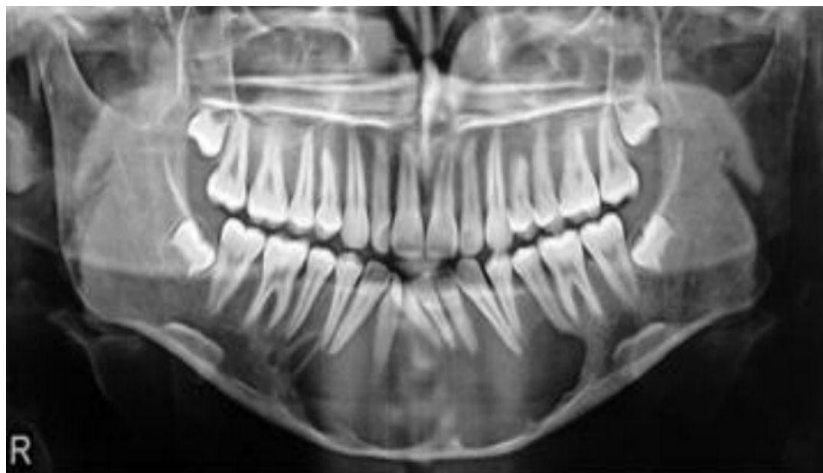

Figure 4: Panoramic radiograph showing mixed radiolucent radio-opacity with ill-defined borders (DA). (Sanjay et al, 2020)

Radiographical appearance of ameloblastoma

d- Unicystic Ameloblastoma

Unicystic ameloblastoma (UA) represents an ameloblastoma variant, presenting as a cyst that show clinical and radiologic characteristics of an odontogenic cyst. 5 to 15% of all ameloblastomas are of the unicystic type. UA with an unerupted tooth occurs with a mean age of 16 years as opposed to 35 years in the absence of an unerupted tooth. The mean age is considerably lower than that for solid/multicystic ameloblastoma with no gender predilection. UA is a prognostically distinct entity with a recurrence rate of 6.7-35.7%, and the average interval for recurrence is approximately 7 years. **Barnes , 2005**

Six radiographic patterns are identified for UA, ranging from well-defined unilocular to multilocular ones. Comparing unilocular and multilocular variants, there is an apparent predominance of a unilocular configuration in all studies of UA, especially in cases associated with impacted teeth. UA might mimic other odontogenic cysts clinically and radio graphically. **Eversole , 1984**

Histopathological classification of UAs are -:

- Luminal UA
- Luminal and intraluminal UAs
- Luminal, intraluminal, and intramural UAs
- Luminal and intramural UAs.

Treatment of UA includes both radical and conservative surgical excision, curettage, chemical and electro cautery, radiation therapy or combination of surgery and radiation. **Philips , 1998**

Radiographical appearance of ameloblastoma

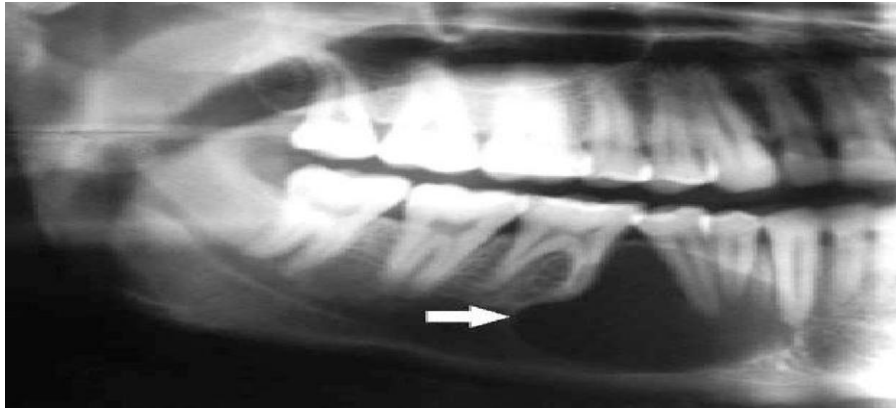


Figure 5: Unicyclic ameloblastoma in a 25-year-old man. Panoramic radiograph shows a well-defined lucent lesion between the canine and first premolar (arrow). Note the loss of lamina dura with tooth displacement. (Sanjay et al, 2020)

1.3 Differential diagnosis

General imaging differential considerations include:

- Dentigerous cyst .
- Cementifying or ossifying fibroma .
- Developmental bone defect .
- Giant cell granuloma .
- Odontogenic keratocyst

1.4 Radiographic features

The radiographic appearance of ameloblastoma is variable. H. M. Worth has described four patterns. (Worth., 1963) (Figure6)

Radiographical appearance of ameloblastoma

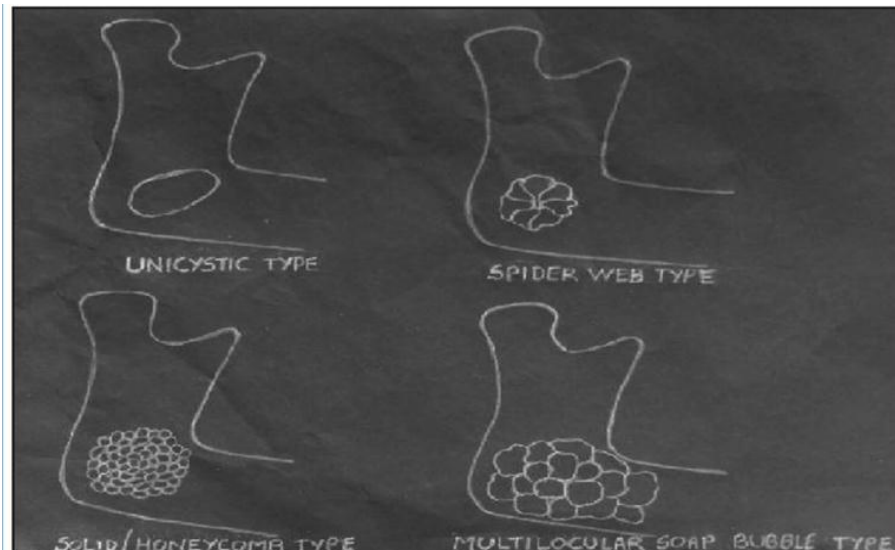


Figure 6: Schematic diagram showing radiographic appearance of ameloblastoma. (More et al, 2012)

a- Unicystic type:

This appears as a unilocular radiolucency resembling a cyst. However, unlike cyst, it causes a break or discontinuity in the peripheral cortex and may even show trabeculae within the lumen. (More et al, 2012)

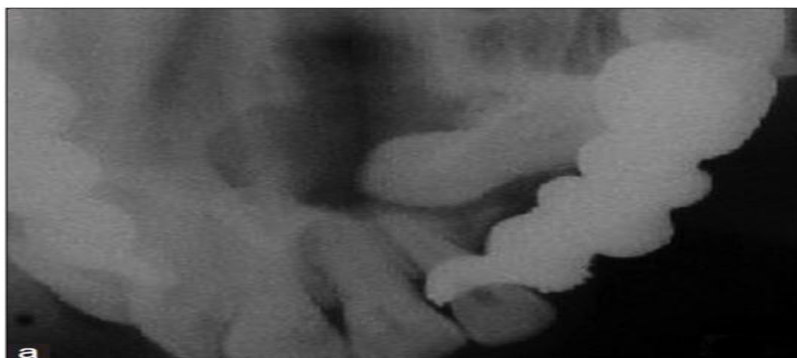

Figure 7: Maxillary occlusal radiograph showing unicystic type of ameloblastoma. (More et al, 2012)

b - Spider-web pattern

This is the most common appearance, where the lesion is seen as a large radiolucent area with scalloped borders. From the center of the

Radiographical appearance of ameloblastoma

lumen coarse strands of trabeculae radiate peripherally, giving rise to a gross caricature of a spider. (More et al, 2012)

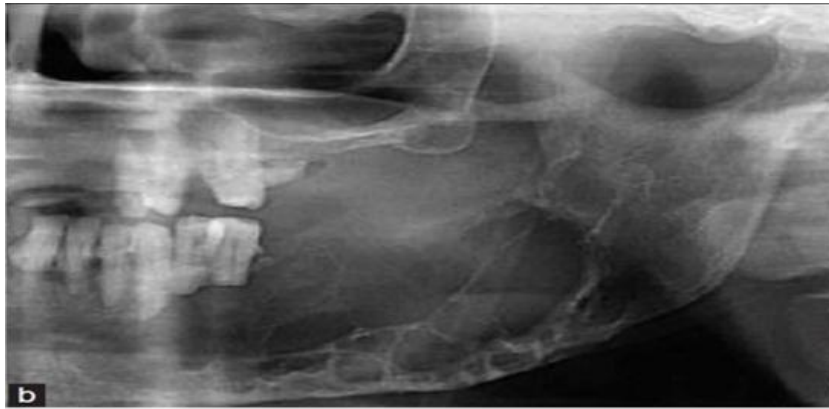

Figure 8: cropped panoramic radiograph showing spider-web type. (More et al, 2012)

c- Soap-bubble pattern

This lesion is seen as a multilocular radiolucency with large compartments of varying sizes, giving rise to the soap-bubble appearance, or a multi-chambered or multi-cystic ‘bunch of grapes’ appearance. (More et al, 2012)

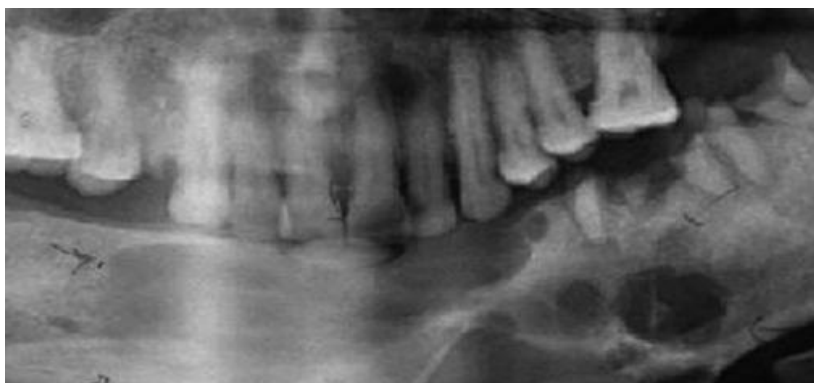

Figure 9: cropped panoramic radiograph showing soap-bubble type. (More et al, 2012)

This is also called a beehive pattern. These are tumors that have not undergone cystic degeneration. Hence, multiple small radiolucencies are

Radiographical appearance of ameloblastoma

seen surrounded by hexagonal or polygonal thick-walled bony cortices, giving rise to a honeycomb appearance. (More et al, 2012)

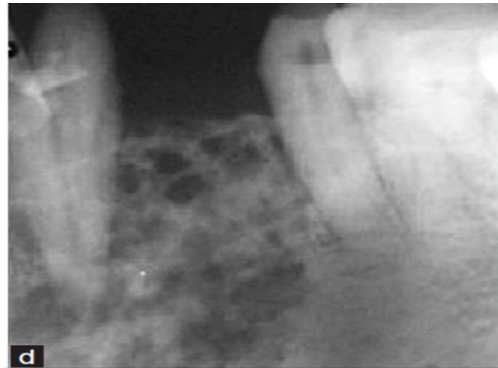


Figure 10: intraoral periodical radiograph showing honeycomb type (More et al, 2012).

1.5. Imaging of ameloblastom

Multicystic ameloblastomas account for 80-90% of cases which are classically expansile "soap-bubble" lesions, with well-demarcated borders and no matrix calcification. Resorption of adjacent teeth and “root blunting” is often a feature. When larger it may also erode through the cortex into adjacent soft tissues.

Unicystic ameloblastomas are well-demarcated unilocular lesions that are often pericoronal in position. These are commonly found in the posterior mandible, particularly at the molars. They are indistinguishable from other unilocular pericoronal lesions, such as dentigerous cysts, ameloblastic fibromas and odontogenic keratocysts on CT. (Jeremy, 2021).

Radiographical appearance of ameloblastoma

A- CT Scan

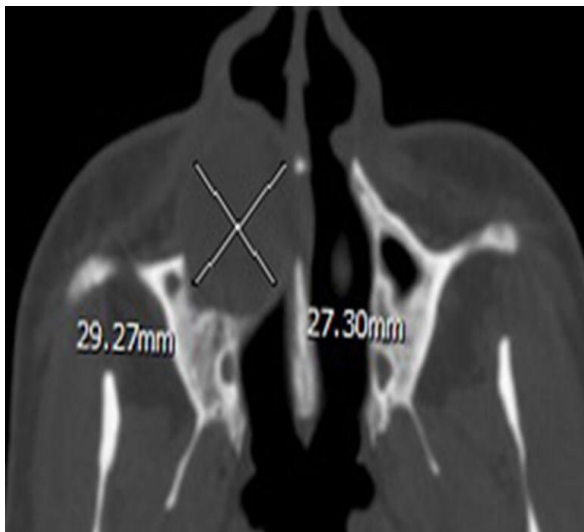


Figure 11:

Axial CT displayed a circular-shaped ameloblastoma occupying the right maxilla. (MengY et al, 2019)

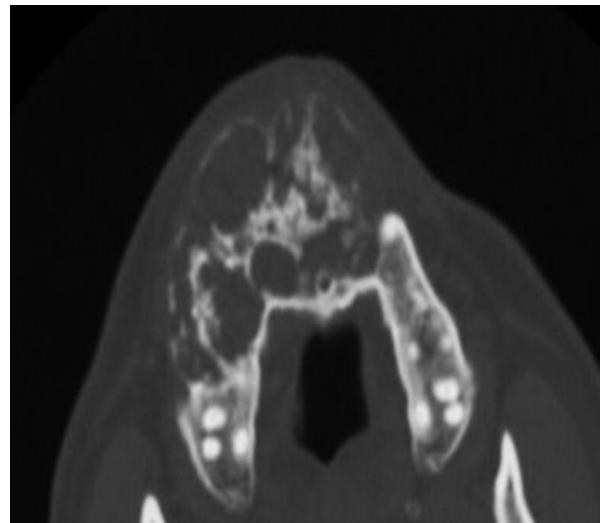


Figure 12:

Axial CT showing a maxillary desmoplastic ameloblastoma with a lobular-oval shape. Note the mixed radiolucent and radiopaque appearance, mimicking a fibro-osseous lesion. (MengY et al, 2019)

B- OPG

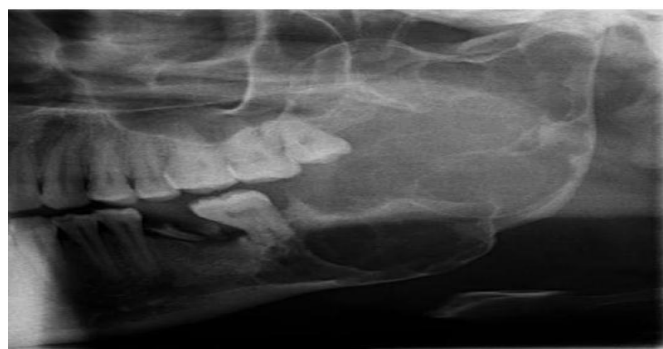

Figure 13: OPG of the involved site showing areas involved and bone destruction. (Sanjay et al, 2020)

Radiographical appearance of ameloblastoma

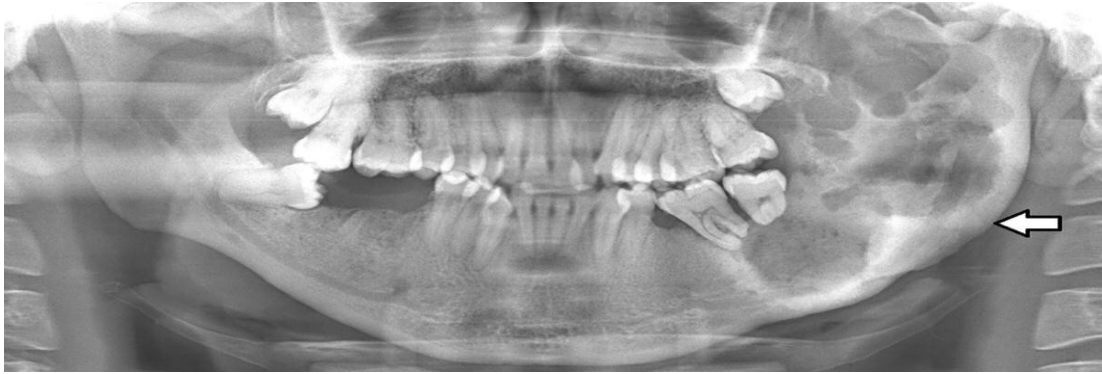


Figure 14: Pantomograph showing both radiolucent and radiopaque appearance (mixed density) of an ameloblastoma in the left mandible(Sanjay et al, 2020).

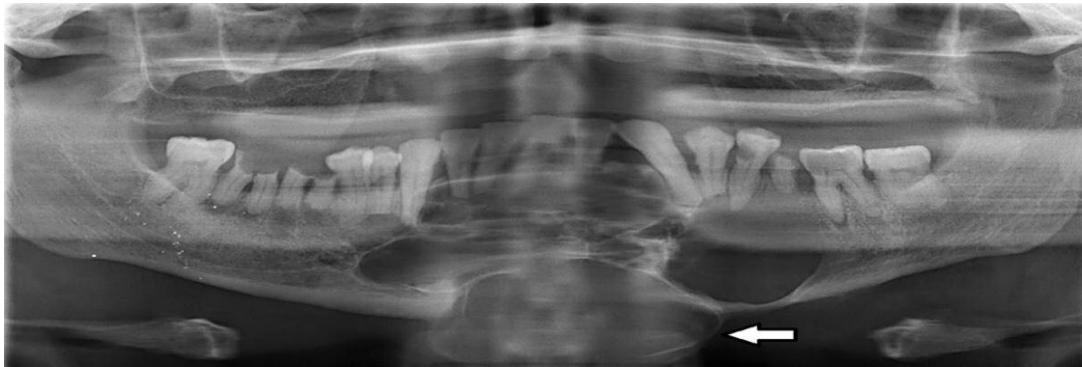


Figure 15: Multilocular appearance of an ameloblastoma in the anterior and posterior regions of the mandible. (Sanjay et al, 2020)

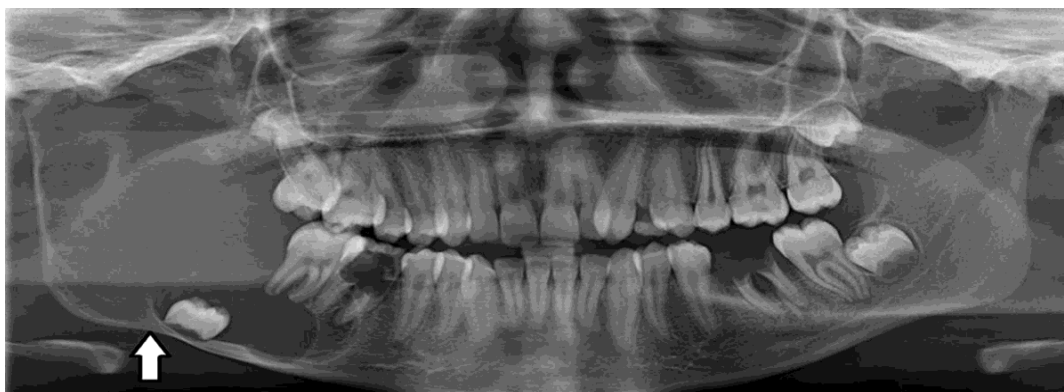

Figure 16: Pantomograph showing multilocular, soap-bubble appearance of an ameloblastoma in the right mandible. (Sanjay et al, 2020)

Radiographical appearance of ameloblastoma

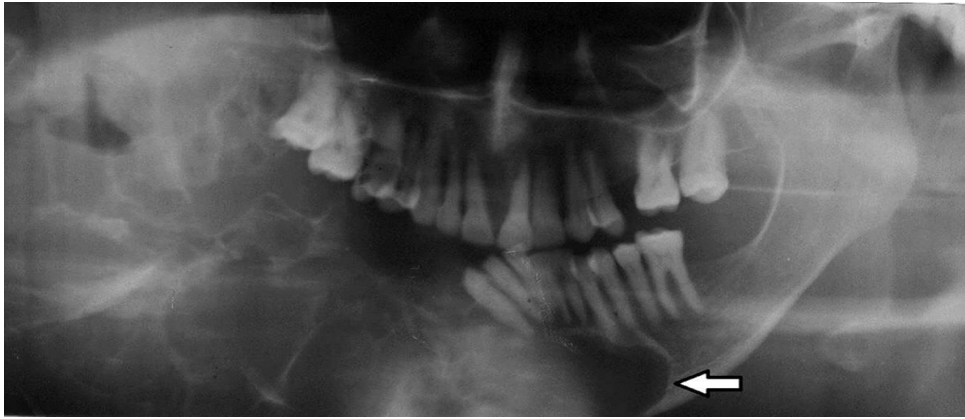


Figure 17: Pantomograph showing multilocular lesion with a spider-like appearance of an ameloblastoma in the mandible. (Sanjay et al, 2020)

C- MRI

In general, ameloblastomas demonstrate a mixed solid and cystic pattern, with a thick irregular wall, often with solid papillary structures projecting into the lesion. These components tend to enhance vividly which is very helpful to distinguish them from other lucent lesions of the mandible. (Jeremy, 2021)

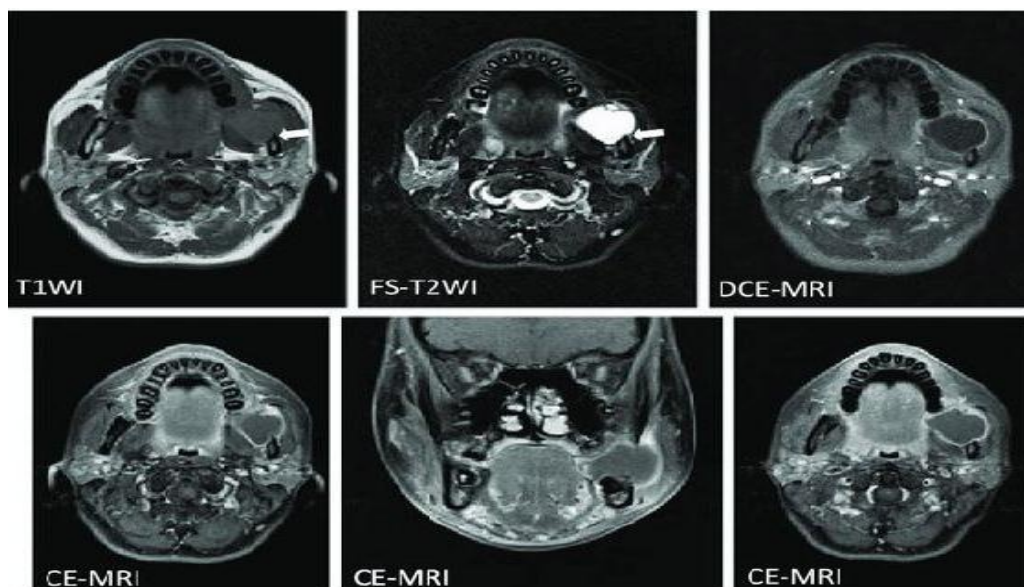


Figure 18: MRI of ameloblastoma. (Wakoh M et al, 2020)

Chapter two: Discussion

Ameloblastoma is a tumour with a well-known propensity for recurrence.⁸ Several factors may influence the rate of recurrence: the clinicoradiologic appearance of the tumour, the anatomic site and the adequacy of the initial surgery. **(Becelli et al.,1977; Iordanidis et al., 1999; and Ferretti et al.,2000)**

Radiologically, the lesions are expansile, with thinning of the cortex in the buccal–lingual plane. The lesions are classically multilocular cystic with a “soap bubble” or “honey- comb” appearance. On occasion, conventional radiographs

reveal unilocular ameloblastomas, resembling dentigerous cysts or odontogenic keratocysts. The radiographic appearance of ameloblastoma can vary according to the type of tumour. CT is usually helpful in determining the contours of the lesion, its contents and its extension into soft tissues. **(Rampton, 1998)**

In a patient with a swelling in the jaw, the first step in diagnosis is panoramic radiography. However, if the swelling is hard and fixed to adjacent tissues, CT is preferred. Although the radiation dose is much higher in CT, the necessity of identifying the contours of the lesion, its contents and its extension into the soft tissues, makes it preferable for diagnosis. Plain radiographs do not show interfaces between tumour and normal soft tissue; only interfaces between tumour and normal bone can be seen. The axial view in contrast-enhanced CT images and the coronal and axial views in magnetic resonance imaging (MRI) clearly show both types of interface. **(Cihangiroglu et al., 2002)**

Radiographical appearance of ameloblastoma

Although there are no appreciable differences between MRI and CT for detecting the cystic component of the tumour, for visualizing papillary projections into the cystic cavity, MRI is slightly superior. MRI is essential for establishing the exact extent of an advanced maxillary ameloblastoma and thus determining the prognosis for surgery. Ameloblastomas are treated by curettage. (**Kawai et al., 1998; and Ziegler et al., 2002**)

Mandibular ameloblastoma has unique radiographic and histopathological features most likely due to its distinct anatomical features. In this study we described a case-series of ameloblastoma in a South African population group. To our knowledge, it is the largest cohort of mandibular ameloblastomas described in the literature.

The wide age range (11–83 years) presented in this study is comparable to other studies (**Reichart et al., 1995; Agbaje et al, 2018; and Siar et al., 2012**) This age range is also described by (**MacDonald et al. ,2004**) in a systematic review in 2004. The mean age of patients in this study was 32.99 years. (**Krishnapillai et al., 2010**) who conducted a study on an Indian population group, showed similar results. Furthermore, this result is supported by a large review of 2444 cases involving mandibular ameloblastomas by (**Reichardt et al.,1995**) which showed a mean age of 35.2 years old.

A nearly equal distribution between males and females was found in this study as well as in a study by (**Chukweneke et al., 2016**). In contrast, a slight male predilection was shown in studies by (**Chawla et al., 2013; Siar et al., 2012; and More et al., 2012**) with ratios of male and female

Radiographical appearance of ameloblastoma

patients being 1.2:1, 1.4:1 and 1.2:1, respectively. Interestingly, this study demonstrated that ameloblastoma in the 5th decade of life had a predilection for males (18) compared to females (8). This could possibly be ascribed to the inherent culture of male patients in seeking professional medical assistance later in the disease process as compared to than their female counterparts (**Thompson et al., 2016**).

More than half of all patients (58.8%) that presented with ameloblastoma of the mandible in this study were of black African descent. Even though black Africans constitute only 32.8% of the population in this region, this study showed that ameloblastoma occurred more often in black Africans but not significantly. Reviews by (**MacDonald;et al., 2004; and Reichardt et al., 1995**) also showed that this tumour had a predilection for black population groups. (**Oginni et al., 2015**) did not agree with this notion.

When comparing ameloblastoma in the maxilla to those in the mandible, numerous authors reported that maxillary lesions tend to occur more frequently in males with an average age of 54.9 years (**Dyalram et al., 2011; and Beogo et al., 2018**). This is in contrast to mandibular lesions in this study which occurred nearly equally in males and females with a lower mean age of 32.99 years. (**Dyalram et al., 2011**) also demonstrated in their sample that maxillary lesions have a higher incidence in Caucasian patients as compared to mandibular lesions which occurred mostly in African American patients.

When assessing ameloblastoma of the mandible, radiographic modalities are useful in determining the size, extent, internal structure, margins and its effect on adjacent structures. With the introduction and use of advanced digital imaging, conventional radiography may appear

Radiographical appearance of ameloblastoma

out-dated. In rural settings or in the developing world this modality may still however be the mainstay of imaging either because advanced digital imaging is unavailable or simply too costly to implement. Pantomographs are still able to provide adequate information to assist in temporary diagnosis prior to histopathological confirmation.

Large reviews by (Agbaje et al., 2018; Ruslin et al., 2018; Siar et al., 2012; and Reichardt et al., 1995) indicate that the mandibular posterior region is the most common site affected by ameloblastoma. The results from this study corroborate these findings. However, (Chukweneke et al., 2016; and Adekeye 1980). Showed that the anterior region was more commonly involved. The difference in location in the various population groups is largely unknown and the histological and molecular characteristics of the tumour may be related to ethnic and geographic differences.

This study (Sanjay et al., 2020) showed similar distribution of radiolucent, and mixed radiolucent-radiopaque lesion's appearance. This significantly contrasts with the finding of (Macdonald et al., 2004) in their systematic review by, in which radiolucent appearance predominated. (Siar et al., 2012) also showed that a large proportion of lesions were radiolucent. Mixed lesions are frequently seen in the desmoplastic subtype of conventional ameloblastoma (Goaz and Wood, 1997) .

The reason for the large percentage of patients in this study having a mixed density is unknown, as is the fact that only two lesions were of the desmoplastic subtype. A large percentage of lesions found in this study (Sanjay et al., 2020) showed well-defined, corticated borders and were easily identifiable from the adjacent, unaffected bone. (Malik et al.,

Radiographical appearance of ameloblastoma

2018; and More et al., 2012) also reported a high proportion of these lesions showing this feature. The majority of tumours that exhibited unclear margins were associated with larger lesions. These lesions appeared to destroy the cortices and involve the surrounding soft tissue. It may be argued that, due to the expansile nature of this tumour, larger lesions tend to destroy the cortex, which in turn gives rise to an unclear margin.

In this study (**Sanjay et al., 2020**), just over two-thirds of lesions appeared multilocular on pantomographs. This is comparable to other studies (**Chawla et al., 2013; and Ogunsalu et al., 2006**). The data in the literature however is conflicting. Some studies indicate a multilocular predominance, whereas others (**Tatapudi et al., 2018; Kim and Jang, 2001**), indicate that the unilocular appearance is more prevalent. Even though there was no statistically significant association ($p = 0.391$) between lesion's aspect and age, it is evident in our sample that in a younger age category, the majority of lesions appeared as unilocular entities. (**Tatapudi et al., 2018**) also showed that the unilocular entity occurs at a younger age when compared to the multilocular variety.

According to (**Worth, 1963**), the "spider-like" pattern is the most common radiological appearance. This is followed by the "soap-bubble" pattern. However, in our study the "soap-bubble" pattern predominated (68.32%). The "spider-like" pattern was present in only a small percentage (10.69%). In addition, the "soap-bubble" pattern presented

almost equally in both radiolucent and radiolucent-radiopaque (mixed) lesions. Ameloblastomas that have caused either only root resorption or root resorption associated with tooth displacement amounted to a substantial proportion (66.38%). In a study by (**Struthers and Shear,**

Radiographical appearance of ameloblastoma

1976) it was shown that the incidence of root resorption in association with ameloblastomas was high (81%). Therefore, the inclusion of ameloblastoma as part of a differential diagnosis is essential when root resorption occurs in the presence of a cystic lesion, especially if the posterior region of the mandible is involved.

A study by (Fulco et al., 2010) reported the average size of ameloblastoma as 43 mm. The results of this study showed that the average size of the lesions (86.39 mm) was more than twice the average size reported in the literature. This difference in size could possibly be attributed to late consultation as a result of limited access to advanced healthcare.

Amongst the histopathological subtypes in this review (Sanjay et al., 2020), the CA was found most frequently (48.65%). Within this subtype, the follicular variant was predominant (51.39%). This is in accordance with other studies in the literature (Chukwuneke et al., 2016; Fulco et al., 2010; and Turki et al., 2016). The plexiform variant was the second most prevalent (16.66%) in this study. In contrast, (Saghravanian et al., 2016) showed that the plexiform pattern was the most commonly occurring variant (41.93%). Only a small percentage (12.84%) of lesions was diagnosed as UA. However, (Tatapudi et al., 2018; Chawla et al., 2013; and Krishnapillai and punny, 2010) showed that UA represented respectively 37%, 34% and 36% of their cohort. According to their results, the UA was the most commonly occurring subtype.

Routine panoramic radiography is part of the diagnostic investigation for pathology screening. However, panoramic radiography cannot rule out other diagnoses whose radiological features can be similar to that of ameloblastomas (Kitisubkanchana et al., 2020). These include

Radiographical appearance of ameloblastoma

odontogenic keratocyst, fibromyxoma, fibrosarcoma, haemangioma, aneurysmal bone cyst and giant cell tumour. In addition, other limitations include the inadequate visualization of bony margins of the tumour, as well as unclear interface between the tumour and normal soft tissue. Furthermore, ameloblastomas have a tendency to perforate the cortex, which is an important feature in order to make a differential diagnosis. This feature cannot always be visualized by conventional radiography (Apajalahtiet al., 2015). CBCT, CT and MRI are much more efficient in defining differential diagnoses (Apajalahtietal., 2015). Another disadvantage of conventional radiography is the inability to assess the internal contents of the lesion. Contrast-enhanced CT and MRI are modalities, which are helpful in this regard (Ariji et al., 2011). Although advanced imagery is required in most cases, it is not feasible due to the lack of availability and the high cost.

Chapter three: Conclusions

The ameloblastoma is usually of late diagnosis because of its poor symptoms and low prevalence. Its treatment preferably includes the resection with safety margins and immediate reconstruction whenever possible. Routine histological classification of the ameloblastoma is mandatory for its morphological characterization and, thus, a better treatment definition. The main success factor associated with the treatment is the early diagnosis and to correlate the histopathologic findings with clinical and radiographic features to achieve at a correct definitive diagnosis as all such lesions might have prognostically different biologic behaviors and the final diagnosis may alter the therapeutic decision significantly.

References

1. Adekeye EO. Ameloblastoma of the jaws: A survey of 109 Nigerian patients. *J Oral Surg* 1980;38:36–40.
2. Agbaje JO et al, Biological profile of ameloblastoma and its location in the jaw in 1246 Nigerians. *Oral Surg Oral Med Oral Pathol Oral Radiol* 2018;126:424–431
3. Apajalahti S et al, Hagström J. Imaging Characteristics of ameloblastomas and diagnostic value of computed tomography and magnetic resonance imaging in a series of 26 patients. *Oral Surg Oral Med Oral Pathol Oral Radiol* 2015.;120:e118–e130 .
4. Ariji Y. et al, Imaging features contributing to the diagnosis of ameloblastomas and keratocystic odontogenic tumours: logistic regression analysis. *Dentomaxillofac Rad* 2011;40:133–140
5. Barnes L et al, editors. Lyon, France: IARC Press; 2005. World Health Organization Classification of Tumours: Head and Neck Tumours.
6. Becelli R et al, Mandibular ameloblastoma: analysis of surgical treatment carried out in 60 patients between 1977 and 1998. *J Craniofac Surg* 2002; 13(3):395–400.
7. Béogo R et al, Maxillary ameloblastoma: results of the treatment in 11 patients. *J Oral Med Oral Surg* 2018;24:6–10.
8. Buchner A, Sciubba JJ. Peripheral epithelial odontogenic tumors: A review. *Oral Surg Oral Med Oral Pathol.* 1987;63:688–97
9. Cakur B et al, Plexiform ameloblastoma. *Erciyes Med J.* 2009;(Suppl 1):S62–7
10. Chapelle KA et al, Rational approach to diagnosis and treatment of ameloblastomas and odontogenic keratocysts. *Br J Oral Maxillofac Surg.* 2004;42:381–90

Radiographical appearance of ameloblastoma

- 11.-Chukwuneke FN et al, Clinical characteristics and presentation of ameloblastomas: an 8-year retrospective study of 240 cases in Eastern Nigeria. *Br J Oral Maxillofac Surg* 2016;54:384–387 .
- 12.-Chawla R et al, Ninety-one cases of ameloblastoma in an Indian population: A comprehensive review. *J Nat Sci Biol Med* 2013; 4:310–315.
13. Cihangiroglu M et al, CT and MRI findings of ameloblastoma in two cases. *Neuroradiology* 2002; 44(5):434–7.
14. Cusack JW. Report of the amputations of the lower jaw. *Dubl Hosp Rec.* 1827; 4:1–38.
- 15.Dunfee BL et al, Radiologic and pathologic characteristics of benign and malignant lesions of the mandible. *Radiographics.* 2006; 26:1751–68.
16. -Dyalram-Silverberg D. et al, Ameloblastoma of the maxilla: a report of 32 cases. *J Oral Maxillofacial Surgery* 2011; 69 :e108–e109.
- 17.Eversole LR et al, Ameloblastomas with pronounced desmoplasia. *J Oral Maxillofac Surg.* 1984; 42:735–40.
- 18.Ferretti C et al, Recurrent ameloblastoma: report of 2 cases. *J Oral Maxillofac Surg* 2000; 58(7):800–4.
- 19.Fulco GM et al, Solid ameloblastomas Retrospective clinical and histopathologic study of 54 cases. *Braz J Otorhinolaryngol* 2010;76: 172–177.
- 20.Gardner DG, Corio RL. Plexiform unicystic ameloblastoma. A variant of ameloblastoma with a low-recurrence rate after enucleation. *Cancer.* 1984;53:1730–5.
- 21.Goaz PW, Wood KM. Differential diagnosis of oral and maxillofacial lesions. St Louis, Missouri: Mosby 1997, pp. 128.

Radiographical appearance of ameloblastoma

22. Gunaratne DA, ColLAmeloblastic Carcinoma. Am J Case Rep. 2015 Jul 01;16:415-9.
23. Hong J et al, Long-term follow up on recurrence of 305 ameloblastoma cases. Int J Oral Maxillofac Surg. 2007;36:283–8.
24. Iordanidis S et al, Ameloblastoma of the maxilla — case report. Aust Dent J 1999; 44(1):51–5.
25. Isomura ET et al, Case report of extralingival peripheral ameloblastoma in buccal mucosa. Oral Surg Oral Med Oral Pathol Oral Radiol Endod. 2009;108:577–9.
26. Jackson IT et al, an Anatomical classification of the maxillary ameloblastoma as an aid in surgical treatment. J Cranio Maxillofac Surg 1996; 24:230–236.
27. John M WRIGHT, Merva Soluk Tekkesin .Odontogenic tumors. Where are we in 2017. J Istanb Univ Fac Dent 2017;51(3 Suppl 1):S10-S30.
28. Jeremy Jones. ameloblastoma. radiopedia journal. 07 Oct 2021,
29. Kawai T et al, Diagnostic imaging in two cases of recurrent maxillary ameloblastoma: comparative evaluation of plain radiographs, CT and MR images. Br J Oral Maxillofac Surg 1998; 36(4):304–10.
30. Kim S-G, Jang H-S. Ameloblastoma: A clinical, radiographic, and histopathologic analysis of 71 cases. Oral Surg Oral Med Oral Pathol Oral Radiol Endod 2001;91:649–653
31. Kitisubkanchana J et al, Odontogenic keratocyst and ameloblastoma: radiographic evaluation [published online ahead of print, 2020 Feb 6]. Oral Radiol. 2020; 10.1007/s11282- 020-00425-2.

Radiographical appearance of ameloblastoma

32. Kramer IR, Pindborg JJ, Shear M. 2nd ed. Berlin: Springer-Verlag; 1992. Histological Typing of Odontogenic Tumours. WHO International Histological Classification of Tumours; pp. 11–14.
33. Krishnapillai R, Punnya VA. A clinical, radiographic, and histologic review of 73 cases of ameloblastoma in an Indian population. *Quintessence Int* 2010;41:e90–e100.
34. Madhup R et al, Giant ameloblastoma of jaw successfully treated by radiotherapy. *Oral Oncol Extra*. 2006;42:22–5.
35. Mahmoud SAMbet al, Primary ameloblastic carcinoma: literature review with case series. *Pol J Pathol*. 2018; 69(3):243-253.
36. MacDonald-Jankowski DS et al. Ameloblastoma in the Hong Kong Chinese. Part 2: Systematic review and radiological presentation. *Dentomaxillofac Rad* 2004;33:141–151
37. Malik AH et al, Ameloblastoma: a clinicopathological retrospective study. *IOSR-JDMS* 2018;17:30–32.
38. Manuel S et al, Desmoplastic ameloblastoma: A case report. *J Oral Maxillofac Surg*. 2002;60:1186–8.
39. Mendenhall WM et al, Ameloblastoma. *Am J Clin Oncol*. 2007;30:6458.
40. Meng Y et al, Three-dimensional radiographic features of ameloblastoma and cystic lesions in the maxilla. *Dentomaxillofac Radiol* 2019; 48: 20190066
41. Mintz S, Velez I. Desmoplastic variant of ameloblastoma: Report of two cases and review of the literature. *J Am Dent Assoc*. 2002;133:1072–5.
42. More C et al, Radiographic analysis of ameloblastoma: A retrospective study. *Indian J Dent Res* 2012;23:698–701.
43. Nakamura N et al, Growth characteristics of ameloblastoma involving the inferior alveolar nerve: A clinical and histopathologic

Radiographical appearance of ameloblastoma

- study. *Oral Surg Oral Med Oral Pathol Oral Radiol Endod.* 2001;91:557–62.
44. Oginni FO et al, A prospective epidemiological study on odontogenic tumours in a black African population, with emphasis on the relative frequency of Ameloblastoma. *Int J Oral Maxillofac Surg* 2015;44:1099–1105
45. Ogunsalu C et al, A new radiological classification for ameloblastoma based on analysis of 19 cases. *West Indian Med J* 2006;55:434–439.
46. Palanisamy JC, Jenzer AC. Ameloblastoma. [Updated 2022 Jan 21]. In: StatPearls [Internet]. Treasure Island (FL), 2022
47. Peter AR, Philipsen HA. 1st ed. London: Quintessence; 2004. Odontogenic Tumors and Allied Lesions; pp. 43–58.
48. Philipsen HP et al, Peripheral ameloblastoma: Biological profile based on 160 cases from the literature. *Oral Oncol.* 2001;37:17–27.
49. Pramod John R, *Textbook of Dental Radiology, Second Edition*, Jaypee Brothers Medical Publishers (P) Ltd, 2011; p.199-201
50. Rampton P. Teeth and jaws. In: Sutton D, editor. *Textbook of radiology and imaging*. Philadelphia: Churchill-Livingstone; 1998. p. 1388–9
51. Reichart PA, Philipsen HA. Desmoplastic Ameloblastoma: Odontogenic Tumors and Allied Lesions, London Quintessence Publishing Co Ltd; 2004.; pp. 69–76.
52. Ruslin M et al, The Epidemiology, treatment, and complication of ameloblastoma in East-Indonesia: 6 years retrospective study. *Med Oral Pathol Oral Cir Bucal* 2018; 23: e54–58.
53. Sanjay et al, Ameloblastoma of the mandible: analysis of radiographic and histopathological features, *J Oral Med Oral Surg* Volume 27, Number 1, 2021

Radiographical appearance of ameloblastoma

54. Saghravanian N et al, 40-year Retrospective Clinicopathological Study of Ameloblastoma in Iran. *Asian Pac J Cancer Prev* 2016;17:619–623.
55. Siar CH et al, Ameloblastoma of the jaws: A retrospective analysis of 340 cases in a Malaysian population. *J Oral Maxillofac Surg* 2012;70:608–615
56. Struthers P, Shear M. Root resorption by ameloblastomas and cysts of the jaws. *Int J Oral Surg* 1976;5:128–132
57. Sun ZJ et al Desmoplastic ameloblastoma - A review. *Oral Oncol.* 2009;45:752–9.
58. Tatapudi R et al, Prevalence of ameloblastoma: A three-year retrospective study. *J Ind Acad Oral Med Radiol* 2018;26:145–151.
59. Thompson AE et al, The influence of gender and other patient characteristics on health-care seeking behaviour: A QUALICOPC study. *BMC Fam Pract* 2016;17:38–45
60. Turki IM, Douggaz A. A histologic variant of ameloblastoma: the acanthomatous type. *Med Buccale Chir Buccale* 2016; 22: 55–57.
61. Wakoh M et al, Luminal, Intramural Unicystic Ameloblastoma with Marked Fluid-Fluid Level: Validity of CT and MRI Findings, Published Online in J-STAGE 20 February, 2020
62. Worth HM. Principles and practice of oral radiologic interpretation. Chicago: Year Book Medical Publishers 1963, pp. 476.
63. Ziegler CM et al, Clinical indications for digital volume tomography in oral and maxillofacial surgery. *Dentomaxillofac Radiol* 2002; 31(2):126–30.