



Republic of Iraq
Ministry of Higher Education
and Scientific Research
University of Baghdad
College of Dentistry



Relining and Rebasing procedures

A Project Submitted to
The College of Dentistry, University of Baghdad, Department of
Prosthodontics in Partial Fulfillment for the Bachelor of Dental
Surgery degree

By:

Ibrahim Ayad Ibrahim

Supervised by:

Assist. Lect. Zinah Salah Mawlood

B.D.S., M.Sc. Prosthodontics

2022 A.D.

1443 A.H.

بِسْمِ اللَّهِ الرَّحْمَنِ الرَّحِيمِ

قَالَ تَعَالَى: "يَرْفَعُ اللَّهُ الَّذِينَ آمَنُوا مِنْكُمْ
وَالَّذِينَ أُوتُوا الْعِلْمَ دَرَجَاتٍ وَاللَّهُ بِمَا
تَعْمَلُونَ خَبِيرٌ"

سورة المجادلة (١١)

Declaration

I certify that this project entitled "Relining and Rebasing procedures" was prepared by the fifth year student Ibrahim Ayad Ibrahim under my supervision at the College of Dentistry/University of Baghdad in partial fulfilment of the graduation requirements for the Bachelor Degree in Dentistry.

Assist. Lec. Dr. Zinah Salah Mawlood

April 2022

Dedication

To the kindest hearts in my life my mother
and my father... who give me all the
support and care in my life.....

Acknowledgements

First of all, I thank **God Almighty**, who blessed me with wisdom, patience, and willpower to reach this level in my life.

I would like to thank Professor **Dr. Raghad Al-Hashimi**, the dean of the College of the Dentistry, University of Baghdad for providing me the opportunity to complete my work.

Also, I express my thanks to Prof. **Dr. Ali Al-Bustani**, Assistant dean for Scientific Affairs and students of the college of Dentistry, University of Baghdad for his continuing support to complete this work.

I would like to thank Prof. **Dr. Hussain Al-Huwaizi**, the previous dean of the College of the Dentistry, University of Baghdad for his support.

I would like to thank Asst. Prof. **Dr. Ghassan Al Taie**, the chairman of the prosthodontic department for his support.

I would like to extend my deepest respect and gratefulness to **Dr. Zinah Salah** for her encouragement, meaningful and valuable instructions, and advice throughout working on this project.

In the end, I thank my family for all the support they have provided throughout the years of studying and their encouragement.

List of Contents

No.	Subject	Page No.
	Acknowledgements	iii
	List of Contents	iv
	List of figures	vi
	List of abbreviations	vii
	Introduction	1
	Aims of the study	2
	Chapter One Literature review	
1.1	Bone resorption	3
1.1.1	Factors related to the Intensity of Bone Resorption	3
1.1.2	Management of Ongoing Changes in the Denture Supporting Tissue	4
1.2	Relining	4
1.2.1	The main objectives of relining or rebasing	5
1.2.2	Indications of Relining and Rebasing	5
1.2.3	Contraindications of Relining	6
1.2.4	Evaluations and Examination Prior to Relining Procedure	6
1.2.4.1	Checking the fit between denture and mucosa	7
1.2.4.2	Checking the Occlusal Relationship	8
1.2.4.3	Checking Alveolar Ridge Mucosa	8
1.2.5	Advantages and Disadvantages of Relining	8
1.3	Classification of Relining Materials	9
1.3.1	Hard Relining Materials	10

1.3.1.1	Chairside Hard Relining Materials	11
1.3.1.2	Heat Cured Acrylic Reliner	12
1.3.2	Soft Relining Materials	13
1.3.2.1	Indications for using soft liners	15
1.3.2.2	Types of Soft Liners	15
1.3.2.2.1	Permanent Soft Liners	16
1.3.2.2.2	Temporary Soft Lining Materials	17
1.3.3	Tissue Conditioners	18
1.4	Relining Procedures	20
1.4.1	Clinical Procedures	21
1.4.1.1	Static Impression Technique	21
1.4.1.2	Functional Impression technique	25
1.4.1.3	Direct Chairside Relining Technique	27
1.4.2	Laboratory Procedures of Relining and Rebasing	29
1.4.2.1	Jig Method	29
1.4.2.2	Flask Method	31
1.4.2.3	Articulator Method	32
1.5	Rebasing	32
	CHAPTER TWO CONCLUSION	
	REFERENCES	

List of Figures

FIGURE	PAGE NO.
FIGURE 1.1 TISSUE ABUSE BENEATH DENTURE	8
FIGURE 1.2 HARD SETTING CHAIRSIDE DENTURE LINER	11
FIGURE 1.3 SOFRELINER SOFT LINER	13
FIGURE 1.4 PERMANENT SOFT LINING MATERIALS	16
FIGURE 1.5. TISSUE CONDITIONER FOR ACRYLIC DENTURES.	19
FIGURE 1.6. CLINICAL IMAGE OF TISSUE CONDITIONER	20
FIGURE 1.7 A. RELIEVING THE DENTURE IN UNDERCUT AREAS. B. RELIEF HOLES FOR THE RELINE MATERIAL	23
FIGURE 1.8 RELINING OF MANDIBULAR COMPLETE DENTURE	24
FIGURE 1.9 REDUCING THE TISSUE SURFACE OF THE DENTURE PRIOR TO FUNCTIONAL METHOD	27
FIGURE 1.10 TAKING THE TISSUE CONDITIONER IMPRESSION	27
FIG. 1.11 JIG METHOD	30

List of Abbreviations

LTSDL	Long Term Soft denture Lining
RLM	Relining Material
CR	Centric Relation
VDO	Vertical Dimension of Occlusion

Introduction

Tooth loss is a significant problem in the elderly population, and in individuals compromised by certain medical conditions. Despite improvements in oral health with a tendency to retain more teeth in elderly peoples' mouths, the usage of removable dental prostheses, partial as well as complete, will be still a necessity for many people.

A number of changes can occur in tissues that support complete denture. According to the survey of dental diseases in 2005, the percentage of individuals between 80 and 84 years of age retaining 20 or more teeth was 21.1%, thus exceeding 20% for the first time since this survey was started. The survey in 2005, however, showed that there was still a high percentage of individuals with multiple missing teeth, i.e., individuals using dentures. **(Shiga et al., 2007)**

Residual ridges, to which removable dental prostheses should be meticulously fitted after production, change in shape due to alveolar bone resorption.

Therefore, they are reduced in size at varying rates in different individuals, and in the same individual at different life periods. **(Kranjčić et al., 2013)**

Alveolar bone resorption causes loss of denture retention and stability, occlusal vertical dimension reduction, facial support, horizontal tooth movement, and occlusal disharmony. **(Falatehan and Gandhanya, 2018).**

When residual ridge Resorption occurs, dentures tend to become loose.**(Knechtel and Loney, 2007).** Dentures are destined to show deterioration in fit no matter how well they are initially prepared. **(Shiga et al.,2007).**

Aims of the study

The Main aim is to explain and discuss the process of restoring the viability of a Denture without having to compromise the patients' health or replacing the denture with a new one through the following:-

- Discuss Relining and Rebasing procedures importance
- Classify and Identify materials employed in the explained procedures.
- Discuss the clinical steps used in the Relining and Rebasing procedures

Chapter One

Literature review

Chapter One: Literature review

1.1 Bone resorption:

It is well known that the alveolar ridge inevitably undergoes resorption with advancing age, irrespective of whether or not the individual uses dentures. For this reason, dentures are destined to show deterioration in fit no matter how well they are initially prepared, Bone resorption is the main cause of removable prosthesis maladaptation; however this latter may also occur due to failures in impression or acrylization during the prosthesis construction.(**Shiga et al., 2007**), (**Kubo et al.,2014**)

Many factors may alter the balance between the process of bone formation and resorption. A number of changes can occur in the tissues that support complete dentures. They are more common under the mandibular dentures than the maxillary dentures. They are also common in maxillary dentures opposing natural teeth. These changes may be insidious or rapid, but they are progressive and inevitable, and are usually accompanied by Loss of retention and stability, vertical dimension at occlusion, facial support, Reorientation of occlusal plane and Shift of dentures (**Kubo et al.,2014**).

Changes in occlusal relationship also induce more adverse stresses on the supporting tissues, which increases the risk of further ridge resorption (**Veeraiyan et al., 2003**).

1.1.1 Factors related to the Intensity of Bone Resorption

1. The edentulous period
2. The Mechanical action on the mucosa
3. Time of prosthesis usage
4. Route of force transmission toward alveolar bone

5. Site of edentulous area
6. Antagonistic arch
7. Adaption of the niche support
8. Saddle extension (**Baat et al.,1993**), (**Aquino et al.,2011**).

1.1.2 Management of Ongoing Changes in the Denture Supporting Tissue

Sometimes, the residual ridge contour changes so rapidly that the repeated construction of new dentures becomes a financial burden to the patient. (**Veeraiyan et al.,2003**).

For most patients, denture relining is an economical means of improving a denture's stability and retention, the overall occlusal vertical dimension and, in some cases, facial appearance. (**Knechtel and Loney, 2007**).

In several cases, the resorption compromises the adaptation of the prostheses, many times also damaging the speech and mastication. Therefore, prosthesis relining is indispensable to recover the biomechanical properties and occlusion and to provide comfort to patient. (**Kubo et al, 2014**)

Relining can reduce the frequency of a patient's visits and medical expenses as compared to fabricating new dentures (**Shiga et al., 2007**).

1.2 Relining

Definitions of Relining

Relining is defined as, "A procedure to resurface the tissue surface of the denture with new base material to make the denture fit more accurately". (**Veeraiyan et al.,2003**)

Relining is a method of adding additional amount of new base material (Acrylic resin) to the fitting surface of denture to improve the fit of the denture. **(Soratur, 2006)**

The term “relining” means renewing one layer of the basal surface of the denture with new base material in cases in which the mandibular position and the occlusal relationship are correctly retained, but the basal surface fit has deteriorated **(Shiga et al., 2007)**.

1.2.1 The main objectives of relining or rebasing

- Re-establish the correct relation of the denture to basal tissue.
- Restore stability and retention
- Restore lost occlusal and maxillo- mandibular relationship

(Baat et al.,1993)

1.2.2 Indications of Relining and Rebasing

Because ridge contours change during denture service, it is sometimes necessary to alter tissue surfaces of prostheses to ensure proper fit. In some instances, this can be achieved by selective grinding procedures. In other instances, tissue surfaces must be replaced by relining or rebasing existing denture **(Anusavice et al., 2013)**.

The indications for relining procedure includes the following:

- 1.** Immediate dentures after 3-6 months where maximum residual ridge resorption would have occurred.
- 2.** Any denture that is loose because of poor adaptation to the supporting tissues
- 3.** Economical reasons where the patient cannot afford a new denture.
- 4.** Geriatric or chronically ill patients who cannot withstand physical and

mental stress of construction of new dentures (**Veeraiyan et al.,2003**), (**Knechtel and Loney, 2007**).

Periodically relining and rebasing removable partial and complete dentures is necessary to ensure acceptable long-term denture function and esthetics. (**Christensen, 1995**)

1.2.3 Contraindications of Relining

there are a number of contraindications for relining procedures:

1. When the residual ridge has resorbed excessively.
2. Abused soft tissues due to an ill-fitting denture.
3. Temporomandibular joint problems.
4. Patient dissatisfied with the appearance of the existing dentures.
5. Unsatisfactory jaw relationships in the denture.
6. Dentures causing major speech problems.
7. Severe osseous undercuts. (**Veeraiyan et al.,2003**)

1.2.4 Evaluations and Examination Prior to Relining Procedure

Oral tissues should be in a state of optimal health to realize the best results from a relining procedure. From a practical and financial standpoint, it is also important to ensure that a denture requiring relining is sufficiently acceptable in other respects to justify prolonging its lifespan (**Knechtel and Loney, 2007**).

To determine if a removable partial denture is in need of relining, some visual reference to the loss of supporting tissue must be established (**Phoenix et al.,2009**).

1.2.4.1 Checking the fit between denture and mucosa

The fit of the basal surface of the denture to the mucosa overlying residual ridge is checked using fitting test materials. In addition, retention and stability of the denture within the oral cavity are tested (**Shiga et al., 2007**).

Perhaps the easiest means of evaluating the space under the denture base is to place a thin mix of alginate (irreversible hydrocolloid) in the denture base area, seat the partial denture in the mouth, and maintain its position until the alginate sets. The denture can then be removed from the mouth, the thickness of the alginate is measured, and an informed clinical judgment is made (**Phoenix et al., 2009**).

In cases in which the denture is fit to the mucosa but tends to become detached from the mucosa during occlusion or cases in which pain is noted in the mucosa, the mandibular position and occlusal relationship are checked, and whether or not the abnormality is improved by occlusal adjustment or tissue treatment is examined (**Shiga et al., 2007**).

A thin mix of alginate impression material may be used to evaluate the fit of a denture base to the underlying soft tissues. In this instance, there is a bulk of alginate impression material at the buccal shelf area and at the crest of the ridge. A reline is indicated (**Phoenix et al., 2009**).

Before relining or rebasing is undertaken, the oral tissue must be returned to an acceptable state of health. Management requires a period of function without the prosthesis or relief of the prosthesis in the affected region along with placement of a tissue resilient liner in an effort to reduce the traumatic effects of pressure (**Carr and Brown, 2011**).

When required, a tissue conditioner may be used to improve tissue health (**Knechtel and Loney, 2007**).

1.2.4.2 Checking the Occlusal Relationship

Whether the occlusal relationship involving mandibular position, occlusal vertical dimension is appropriate or not, is checked.

If a minor problem is found in the mandibular position or occlusion, whether the problem is improved following occlusal adjustment or reformation of the occlusal surface is tested.

Relining is indicated only in cases in which the problem is improved following such adjustments (**Shiga et al., 2007**).

1.2.4.3 Checking Alveolar Ridge Mucosa

The mucosa overlying the residual ridge is checked. If any abnormality is found in the mucosa, tissue conditioning is performed prior to relining (**Shiga et al., 2007**).

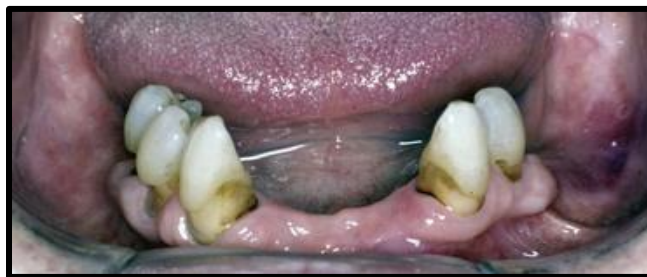

Figure 1.1 Tissue abuse beneath denture (**Carr and Brown, 2011**).

1.2.5 Advantages and Disadvantages of Relining

The **advantages** of relining are:

- 1) Eliminates frequency of patient visits.
- 2) Economical for the patient.

- 3) Improves fit of the denture.
- 4) A soft liner can be incorporated in this denture, if necessary (**Veeraiyan et al.,2003**).

The possible **disadvantages** that are related to relining procedures are:

- 1) Denture base almost always becomes thicker after relining.
- 2) Maxillary denture is displaced anteriorly and, therefore, over-supports the lips after relining.
- 3) Plane of occlusion may be altered.
- 4) It may result in colour difference between the original denture base and the new relining material (**Prakash and Gupta, 2017**).

1.3 Classification of Relining Materials

Denture lining materials are of several types and are used for a variety of reasons (**McCabe and Walls, 2008**).

Manappallil, 2003 classified denture reliners into:

- 1) Hard or soft (resilient)
- 2) Heat cured or self-cured
- 3) Temporary or permanent
- 4) Resin based or silicone based.

While McCabe and Walls, 2008 classified denture relining materials into three groups:

- (1)Hard reline materials
- (2)Tissue conditioners

(3)Soft lining materials

1.3.1 Hard Relining Materials

Materials used for relining can be divided broadly into two types (hard and soft).

Hard materials are made of acrylic, while soft materials are made of acrylic, silicone, polyolefin, etc. Hard materials are usually more selected (**Shiga et al., 2007**).

Hard denture liners are generally used in prosthetic dentistry to reline immediate dentures, for selected RPDs, and for interim dentures until a final denture is completed. Hard liners can be used when there is an adequate residual ridge, resilient mucosa, and mature and healthy supporting structures (**Leinfelder et al., 2007**).

If the fitting surface of a denture needs to be replaced to improve the fit of the denture, a hard relining material can be employed (**Noort, 2013**).

Acrylic resins indicated for immediate and mediate relining, also for rebasing of maladapted prostheses not responding to the retention and stability tests at the delivery moment, and in case of property lost after some time of use (**Kubo et al.,2014**).

The relining either can be achieved with a cold-cure acrylic resin at the chair side, or the denture is sent to a dental laboratory for relining with a heat-cured acrylic. However, a relining should be considered only as a long-term temporary expedient, with laboratory relines being the preferred option (**Noort , 2013**)

1.3.1.1 Chairside Hard Relining Materials

These materials are used for relining resin dentures directly in the mouth (**Manappallil, 2010**).

Chair-side procedures provide immediate resolution, avoiding the edentulous period of time accompanying laboratory relines (**Falatehan and Gandhanya, 2018**).

Several manufacturers offer chemically activated resins for relining dentures intraorally. Unfortunately many of these materials generate enough heat to injure oral tissues.

To receive ADA approval, materials must comply with ANSI/ ADA Specification No. 17, which places limits on the rate of temperature rise and maximum acceptable temperature (**Anusavice et al., 2013**).

One of the most serious drawbacks with attempting a chair-side reline is that there is little control over the amount of denture material removed and the thickness of the reline material that replaces it.

Other problems include high exothermic reactions, unacceptable taste and poor colour stability over time (**Noort, 2013**).

The cold-cured resins come in two types, Powder and Liquid with constituents type 1 and type 2 materials. (**Noort, 2013**).

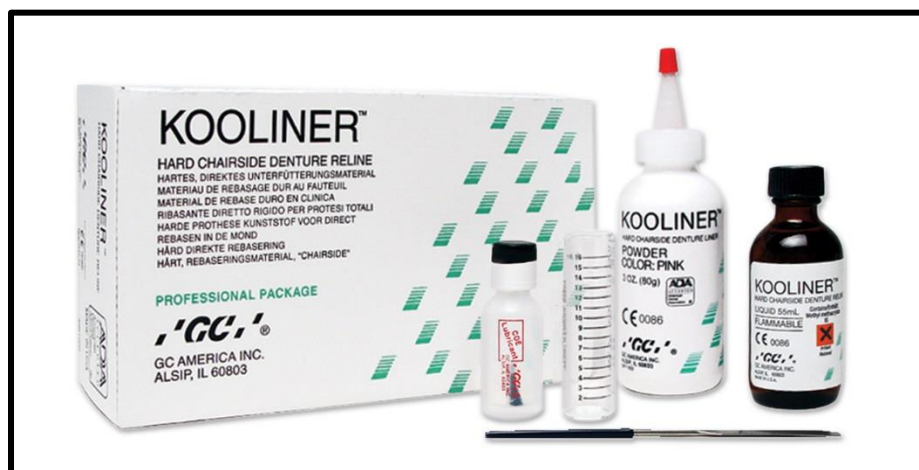

Figure 1.2 Hard setting chairside denture liner (**Manappallil, 2010**).

The major difference between the two cold-cured resin types is that the liquid in the type 1 material contains methylmethacrylate monomer, whilst the liquid of the type 2 material contains butylmethacrylate monomer. Both type 1 and type 2 materials may be classified as autopolymerizing resins and will readily polymerise at room temperature or mouth temperature (**McCabe and Walls, 2008**).

The Disadvantages of Chairside Hard Relining Materials:

They have some disadvantages, including unpleasant odor, irritation to soft tissue caused by monomer, and heat generation during polymerization. The unreacted monomer that gradually leaches out of the hardened acrylic resin might cause a soft tissue reaction as well (**Al Rifaiy, 2011**).

Some of them generate enough heat to injure oral tissues. They tend to discolor, become foul smelling, and may even separate from the denture base (**Manappallil, 2010**). There is some evidence that the heat-polymerized resins showed lower cytotoxic effects than autopolymerizing denture base acrylic resins and light or dual polymerized relining resins (**Chaves et al., 2012**).

1.3.1.2 Heat Cured Acrylic Reliner:

New resin is cured against the old denture by compression molding Technique (**Manappallil, 2010**).

The heat-cured acrylics used by laboratories are identical to those used for the construction of dentures (**Noort, 2013**).

The dimensional change in the resin has been reported as 1.5% to 3% by many authors, and it has been advised that the laboratory technician should use a lower temperature for heat processing as opposed to a boiling

technique (Zarb et al., 2013). For relining, a low polymerization temperature desirable to minimize distortion of the remaining denture base (Manappallil, 2010), (Anusavice et al., 2013).

Heat cured liners have **some disadvantages:**

There is a tendency for it to warp toward the relined side due to:

- A. Diffusion of the monomer from the reliner before curing
- B. Processing shrinkage of the liner. For this reason the rebasing is preferred to relining (Manappallil, 2010).

1.3.2 Soft Relining Materials

Soft lining materials can be defined as soft polymer materials that are applied to the tissue-facing surfaces of dentures that transfer decreased amounts of occlusal forces to underlying tissues, and distribute occlusal forces in a more balanced way. Soft lining materials absorb some of the energy by deformation, which decreases energy absorbed by the tissues (Özkan, 2018).

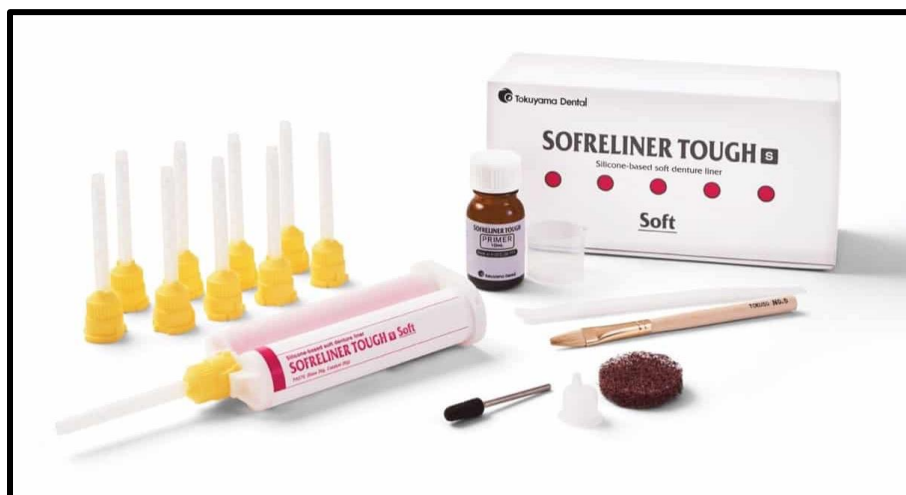

Figure 1.3 Sofreliner soft liner (Soratur, 2006).

Soft liners are polymers with a glass transition temperature below the mouth temperature (i.e., the polymer does not change from liquid to solid completely at mouth temperature) thus the material is semisolid at mouth temperature and therefore the softness **(Babu et al., 2019)**.

Occasionally, a patient will complain of persistent pain and discomfort from a denture, even though the denture would appear totally satisfactory in all other respects.

This problem is seen most commonly in the lower jaw, where there is a smaller surface area over which to distribute the load, and where patients may have a sharp, thin or heavily resorbed alveolar ridge. In such cases, the patient has difficulty in tolerating a hard denture **(Noort , 2013)**.

Therefore, certain groups of patients may be intolerant to hard denture bases due to poor atrophic basal supporting tissues or tissues abused by previous ill-fitting dentures. The use of soft denture liners protects the underlying tissues by absorbing part of the masticatory load, acting like a cushion between the basal supporting tissues and the denture. The liner is applied over the tissue surface of the denture **(Mahalaxmi, 2013)**.

Their effectiveness in handling such cases has been attributed to their inherent elasticity and viscoelastic property that enables them to control the distribution of stresses over the denture bearing mucosa and they also provide a cushioning effect to the cyclic forces of mastication **(Rathi and Verma, 2018)**.

Among soft materials, acryl-based materials are characterized by high viscoelasticity, while materials made of silicone or polyolefin are characterized by high elasticity. Materials made of silicone undergo less change in physical properties over time and exhibit high durability. Materials made of acryl, on the other hand, undergo changes in mucoelasticity over time, gradually lowering stress-breaking effects **(Shiga et al., 2007)**.

1.3.2.1 Indications for using soft liners:

The unique abilities of resilient liner materials to control the distribution of stress over the denture bearing mucosa and to provide a cushioning effect to the cyclic forces of mastication make them suitable for a wide range of applications in the field of prosthetic dentistry (**Rathi and Verma, 2018**).

Resilient materials can be used to stabilize the prosthesis and condition the mucosa. In cases of maladapted prostheses, these materials reduce inflammations and lesions and have been indicated for implant-supported prostheses (**Kubo et al., 2014**).

1.3.2.2 Types of Soft Liners

According to their purpose, soft liners are divided into two groups as:

1) long-term materials (6 months–5 years) are referred to as permanent soft lining materials. They are available in three types:

a. Plasticized acrylic resin.

b. Vinyl resins.

c. Silicone rubbers.

2) short-term materials (3 days–30 days), those that are short-term are referred to as temporary soft lining materials or tissue conditioners.

Even though they are basically the same, these two groups have differences regarding their ingredients and purpose of use (**Özkan, 2018**) (**Manappallil, 2003**).

ISO has given two international standard to soft liners. According to ISO short term soft liners are used for a period of 30 days. And a long term soft liner is one that can maintain its softness for a period of more than 30

days. Some authors classify soft liner that can be used for upto 6 months are called as intermediate liners and long term is one that maintains its softness for a period of 1 year and more(**Babu et al., 2019**).

1.3.2.2.1 Permanent Soft Liners

Long-term soft denture lining (LTSDL) materials constitute a group of polymer materials that can remain in the oral cavity for at least four weeks; in practice, however, their use can extend to several months or even years (**Chladek et al., 2014**). Permanent soft lining materials are most commonly used for patients who cannot tolerate a hard base (**McCabe and Walls, 2008**). The most commonly used long-term soft liners are plasticized methacrylates and silicone rubbers, which are either chemically or heat activated (**Zarb et al., 2013**) The addition of oils and plasticizers as copolymers makes them resilient. When heat processed, they become hard, but they are flexible in the oral cavity (**Manappallil, 2010**).

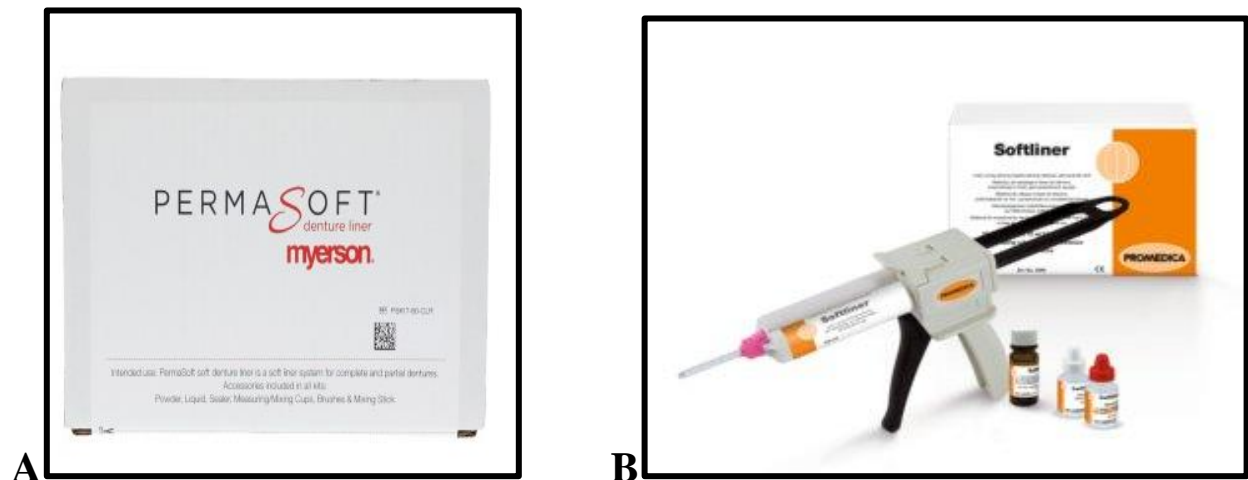

Figure 1.4 Permanent Soft Lining Materials **A.** Acrylic type permanent denture soft liner. It consists of a powder and a liquid which are mixed and applied to the fitting surface of the denture. **B.** A silicone denture soft lining material. It is provided in the form of a cartridge containing two pastes which are mixed when the pastes are extruded through the nozzle (**McCabe and Walls, 2008**).

It's important to note that soft liners are contraindicated in patients with poor saliva flow, as the subsequent friction between the mucoperiosteum and the soft liner can give rise to painful friction (**Noort , 2013**).

Indications of **Permanent Soft Liners**:

Long term soft liners have various clinical applications and uses, which include:

1. Generally, if the patient has pain with his existing dentures during mastication to begin with, the form of the denture, its adaptation and occlusion should be examined. Primarily, the failings of these parts should be fixed. If the existing pain sensation persists after fixing those failings, then, it may be necessary to apply soft lining materials (**Özkan, 2018**).
2. when there is irritation of the mucosa, in areas of severe undercut and congenital or acquired defects of palate (**Manappallil, 2010**)
3. To relieve the pain and increase patient acceptance of the denture, if the patient has an irregular mandibular alveolar ridge covered by a thin and relatively non-resilient mucosa (**McCabe and Walls, 2008**)
4. Used to reline prostheses that are used to restore maxillofacial defects (**Mahalaxmi, 2013**).
5. Patients with sensitivity due to submucosal exposure of the inferior alveolar nerve
6. Patients with highly resorbed ridges (**Zarb et al., 2013**).

1.3.2.2.2 Temporary Soft Lining Materials

Short-term soft liners are soft, resilient, plasticized methacrylate resins commonly used as temporary liners; they have been widely used in

dentistry to manage a multitude of patient problems and clinical applications (**Zarb et al., 2013**).

They are polymers with a glass transition temperature just above the temperature in the mouth thus will have a rubbery behavior and are highly resilient (**Noort, 2013**).

These liners are intended for use as a part of treatment for abused tissues until the tissues revert to normalcy, permitting tissue changes during healing. They remain elastic longer than tissue conditioners but begin to deteriorate (**Mahalaxmi, 2013**).

The materials are not as soft as the tissue conditioners immediately after setting but they retain their softness for longer, taking up to a month or two to harden. Like the tissue conditioners, they are viscoelastic in nature and give a cushioning effect under dynamic conditions of loading (**McCabe and Walls, 2008**).

1.3.3 Tissue Conditioners

Tissue conditioners are soft elastomers used to treat irritated mucosa. Their useful function is very short, generally a matter of a few days. They are replaced every 3-5 days (**Manappallil, 2003**).

It is applied temporarily to the fitting surface of the denture for the purpose of allowing a more even stress distribution. This permits the mucosal tissue to return to its normal shape, and to resolve any inflammation of the denture bearing tissues. Once the inflammation has receded and the tissue has recovered, an impression can be taken for a new denture (**Anusavice et al., 2013**).



Figure 1.5. Tissue conditioner for acrylic dentures. The two large containers contain the powder and liquid components. The powder component consists of beads of polyethymethacrylate. The liquid component consists of a mixture of a plastisizer and a solvent, normally ethyl alcohol (McCabe and Walls, 2008) .

Uses and indications of Tissue Conditioners:

- 1) When the soft tissues have become traumatized due to wearing an ill-fitting denture, to allow the tissue to recover before recording impressions for new dentures (McCabe and Walls, 2008).
- 2) For preventing excessive pressure on healing tissues and contributing to the healing process in patients with temporary or surgical obturators (Özkan, 2018).
- 3) They are also used for provisional adjunctive/ diagnostic purposes such as recovery of the vertical dimension of occlusion and correction of occlusion of old prostheses. They allow assessment for the necessity of using a permanent soft liner for patients with chronic pain or soreness associated with denture wearing.
- 4) Temporary relining of immediate dentures/ immediate surgical splints.
- 5) Relining cleft palate speech aids

- 6) Tissue-conditioning during implant healing period.
- 7) Tissue conditioners can be used as functional impression materials (**Zarb et al., 2013**).
- 8) Chronic bruxism or patients with bruxing tendencies.
- 9) Presence of bony protuberances (**Prasad D. et al., 2014**).

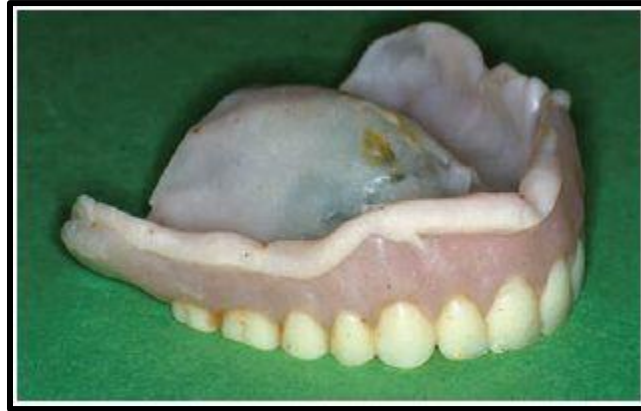

Figure 1.6. Clinical Image of Tissue conditioner .Applied to the surface of an upper denture (**McCabe and Walls, 2008**).

1.4 Relining Procedures

Relining procedures include clinical and laboratory procedures, clinical procedures for relining and rebasing are similar, only the laboratory procedures vary (**Veeraiyan et al., 2003**).

These procedures are as follows:

1. Clinical procedures:

a. Indirect method:

i. Static method

ii. Functional method

b. Direct Chairside method

2. Laboratory Procedures

a. Articulator method

b. Jig method

c. Flask method (Veeraiyan et al., 2003), (S.D et al., 2007).

1.4.1 Clinical Procedures

Whichever technique is employed, it is important to ensure that there are no undercuts within the support surface of the denture because these will hinder its removal from any cast that is ultimately poured in the impression (**Zarb et al., 2013**).

Prior to relining, one layer of the basal surface of the denture needs to be trimmed. In cases with flabby gums or bone tonus, the amount of acrylic to be trimmed is increased or a spillway is created as needed. Care must be exercised to avoid excessive trimming of the acrylic since the strength of the denture usually decreases as the resin base becomes thinner (**Shiga et al., 2007**).

1.4.1.1 Static Impression Technique

All heat-curing resilient materials require indirect, all-laboratory technique. The hard acrylic denture has no contact with the patient before application of the lining (**Yankova et al., 2019**).

The static impression technique involves the use of either a closed- or open-mouth reline/rebase procedure, the closed-mouth reline/rebase method is preferred when the static impression technique is used. (**Zarb et al., 2013**).

In the static impression procedure, the denture is kept out of the mouth for 24 hours. The denture flanges and the tissue surface are reduced by 1-2

mm with stops at the canine and the molar regions. Border molding is done using low fusing stick compound followed by zinc oxide eugenol or rubber base impression in occlusion. The cast is poured and denture is flasked and packed in the usual manner. The denture is inserted after minor occlusal corrections **(S.D et al., 2007)**.

In the so-called open-mouth method, the dentures are used essentially as trays for making the new impressions. It is a method for relining the mandibular and maxillary denture at the same time. It has been emphasized that in this technique the impressions are made independently without utilizing the existing centric occlusion, and a new CRO record is obtained after the impressions have been made **(Veeraiyan et al., 2003)**, **(Zarb et al., 2013)**.

Actually, the dentures are used as special trays for making the secondary impression. ZnOE is the material of choice. It is loaded on the tissue surface of the denture and the impression is made using the denture as the special tray.

After the maxillary and mandibular impressions are made a new centric relation record is accomplished. All these procedures are done in one appointment **(Veeraiyan et al., 2003)**.

Maxillary and mandibular relining/rebasing should be done separately. Several variations have been suggested, all based on using the denture as an impression tray and the actions of the patient to mold the peripheries. The prosthesis is held in position by the patient occluding on the opposing denture before which the occlusion should be corrected either in the preliminary treatment or by modification with hard wax or compound **(Veeraiyan et al., 2003)**, **(Zarb et al., 2013)**.

Steps for a Closed-Mouth Reline Technique:-

1. Record Centric Relation

- a) Existing correct intercuspation (CRO) used to stabilize dentures
- b) Wax interocclusal record made at CR
- c) Reestablishment of a new VDO by occlusal adjustment or use of autopolymerizing resin on the occlusal surfaces of posterior teeth

2. Denture Preparation for the Impression Protocol

- a) Large undercuts relieved
- b) Hard resin surfaces relieved 1 to 2 mm
- c) Tissue conditioner removed or relieved
- d) “Escape” holes drilled, particularly in the maxillary base; this also will assist easy removal of palatal portion during laboratory rebase
- e) Denture periphery shortened to create a flat border

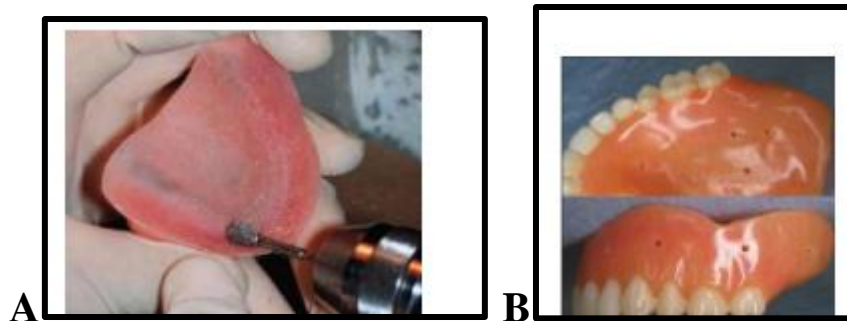


Figure 1.7 **A.** Relieving the denture in undercut areas. **B.** Relief holes for the relined material (Knechtel and Loney, 2007).

3. An Impression Procedure

- a) Border molding achieved with preferred material (e.g., low-fusing compound)
- b) Border molding retained from polymerized tissue conditioning material

c) Posterior palatal seal achieved with low-fusing compound

d) Border molding achieved by choosing impression material that is soft and yet viscous enough to support and register peripheral detail (e.g., one of the polyether impression materials) (Zarb et al., 2013).

Static impression is more advantageous compared to the functional impression because of the following reasons:

- Impression is better controlled using selective pressure technique.
- Impression is not affected by the occlusion of remaining teeth. (S.D et. Al 2007).

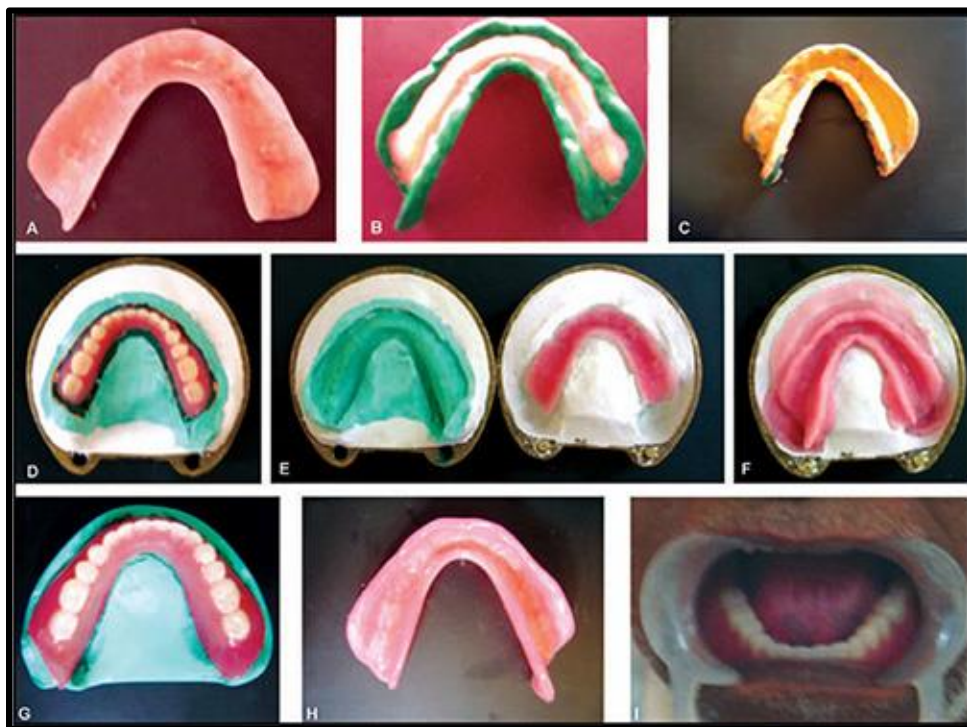


figure 1.8 Relining of mandibular complete denture (A) Denture flanges and tissue surface reduced by 2mm with stops in the canine and molar region (B) Border molding with low fusing stick compound (C) Final impression (D) The cast along with denture invested in the dental flask (E) Removal of low fusing compound and impression material (F) Acrylic packed on the tissue surface of the denture (G), (H), (I) After Relining the denture (S.D et al., 2007)

1.4.1.2 Functional Impression technique

It is both simple and practical and has gained considerable clinical support. It is based on the use of tissue conditioners as functional impression materials.

Here, the patient need not be without dentures unlike previous techniques (i.e. dentures are not required for laboratory procedures) (**Veeraiyan et al., 2003**)

Direct technique is a completely clinical procedure comprising a complex of intraoral and extraoral steps. A basic requirement is to use cold-curing RLMs, the most popular of which are silicone-based (**Yankova et al.,2019**).

In the functional impression procedure, the denture flanges and the tissue surface are reduced by 1-2 mm with stops at the canine and the molar regions.

Border molding is done with low fusing impression compound. Tissue conditioning material is used for recording the impression. Patient is instructed to close in occlusion with light pressure and patient is allowed to wear the denture for 24 hours. The denture with the tissue conditioning material is used to pour a cast followed by flasking and packing as in for laboratory procedure in conventional complete dentures (**S.D et al., 2007**)

Steps of functional impression technique:-

1. The patient is advised to avoid nightwear of dentures.
2. Occlusal errors in the dentures are corrected to obtain centric occlusion that coincides with the centric relation.
3. Flange overextensions/ underextensions and posterior palatal seal areas should be corrected.

4. The tissue surface should be reduced to accommodate the tissue-conditioning material. The tissue surface of the denture is dried and tissue-conditioning material is placed. It should flow evenly as a thin layer to cover the entire impression surface of the denture and its borders
 5. Next, the denture is inserted and the patient's mandible is guided to centric relation in order to stabilize the denture and the material is allowed to set. Once it sets, the impression is removed and excess material is trimmed. Overextensions and voids are corrected.
 6. Unsupported areas in the dentures will show the overflow of the liner and poor recording of the borders.
 7. After making the corrections, the dentures are inserted with the material and the patient is dismissed. After 3 to 5 days, dentures are examined for denuded (depressed) areas, which should be relieved. Areas of underextension are corrected by adding more material.
- The material should be renewed periodically (once a week) till the tissue healing is complete.
8. Once the tissues are normal, impression is made with ZnOE or a light bodied elastomer over the tissue conditioner material and a cast is poured immediately.
 9. The tissue conditioner material undergoes some physical changes during its use, which help the dentist use it for different purposes. In its plastic and elastic stages it is used as tissue conditioner, whereas in its firm stage it is used as reline impression material. Hence, for relining procedures, it should be left in place for about 10 -14 days to allow them to become firm and then reline procedure is carried out (**Veeraiyan et al., 2003**).

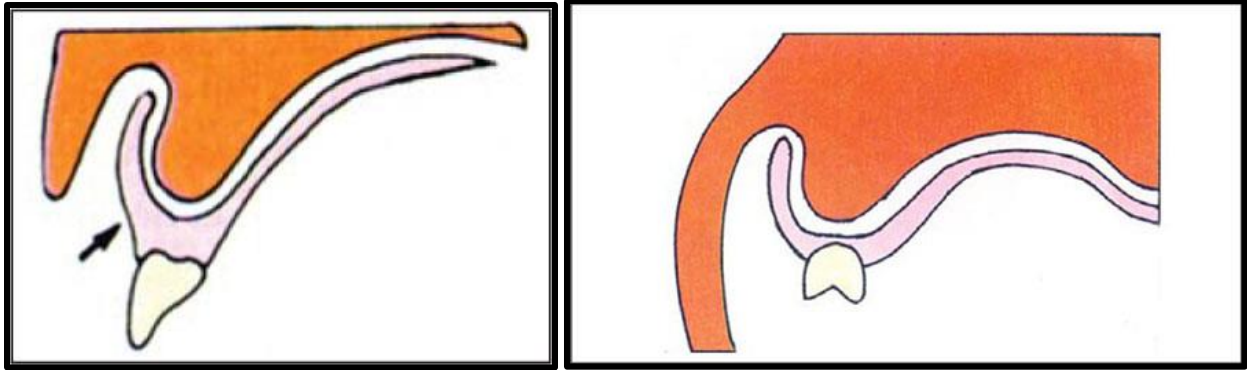


Figure 1.9 Reducing the tissue surface of the denture prior to functional method (Veeraiyan et al., 2003)

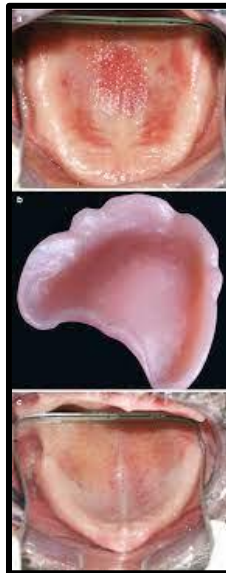

Figure 1.10 Taking the tissue conditioner impression (Veeraiyan et al., 2003)

1.4.1.3 Direct Chairside Relining Technique

Several attempts had been made to produce an acrylic or other plastic material that could be added to the denture and allowed to set in the mouth to produce an instant chairside reline/rebase Done completely by Dentist (Soratur, 2006), (Zarb et al., 2013).

Soft lining materials that polymerize at room temperature can be applied with the direct method. The lining materials are applied on the tissue surface of the acrylic base and left to polymerize intraorally (**Özkan, 2018**). In this technique there are time and cost savings with the chairside method, but the materials used have significant disadvantages (**Knechtel and Loney, 2007**). The relining procedure can be done directly in the patient's mouth using self-cure acrylic resin. Petroleum jelly is applied to the tissue surface and acrylic is lined on the tissue surface of the denture and stabilized in the mouth. The denture with the relining acrylic material is retrieved before the acrylic completely sets in order to prevent the damage to the oral tissues due to the heat generated. The relined denture is trimmed to remove any excess material followed by finishing and polishing of the borders (**Zarb et al., 2013**).

Direct Chairside technique disadvantages:

1. Material produces a chemical burn in oral mucosa, the reactions most frequently found in the mucosa are redness, erosion in the oral mucosa, and burning in the mucosa and tongue.
2. Material is porous and develops a bad odour.
3. Poor colour stability
4. Some materials may exhibit cytotoxicity
5. Material may become distorted if the relined denture is removed from the patient's mouth before complete polymerization
6. If the denture is not positioned correctly the material cannot be easily removed in order to start again..
7. Some materials exhibit greater dimensional change during polymerization than is the case for processed materials (**Veeraiyan et**

al., 2003), (Knechtel and Loney, 2007), (Zarb et al., 2013), (Meister et al, 2015).

1.4.2 Laboratory Procedures of Relining and Rebasing

Laboratory procedures for relining include articulator method, jig, and flask methods. It is common for both relining and rebasing except for a few differences (Veeraiyan et al., 2003). The laboratory steps are required in the indirect techniques of relining using heat cured acrylic (Yankova et al., 2019).

1.4.2.1 Jig Method

Here the impression is boxed and a cast is poured. A reline jig is used in this method (Veeraiyan et al., 2003).

Procedure:

1. Make a conventional reline impression in the denture to be corrected.
2. Pour a cast using the denture/impression, and trim the base. Do not separate the cast from the denture/ impression.
3. Place a bead of stiff vinyl polysiloxane material over the occlusal and incisal surfaces of the teeth of the denture
4. Invert the cast, and place in mounting stone on the bottom half of the reline jig
5. Capture the denture cast with mounting stone, and secure it to the top half of the reline jig, the cast at the top of the jig is coated with a resin separator.
6. Separate the reline jig after the mounting stone is set. Recover the

denture from the cast.

Remove the impression material from the denture, and one layer of the basal surface of the denture is trimmed, a fresh resin surface is exposed, and this is coated with a resin primer, after which autopolymerizing resin is built up.

7. Replace the denture in the reline jig, and add another layer of vinyl polysiloxane material, place separating medium on the definitive cast surfaces.

8. Complete the reline process by mixing a flowable mass of autopolymerizing acrylic and apply the resin over the prepared surface of the denture. Secure the reline jig back together, and tighten the retaining nuts

9. Recover the processed denture, trim the newly added acrylic, and polish for placement (**Rahn and Heartwell, 1993**), (**Plummer and Hall, 2004**), (**Shiga et al., 2007**).

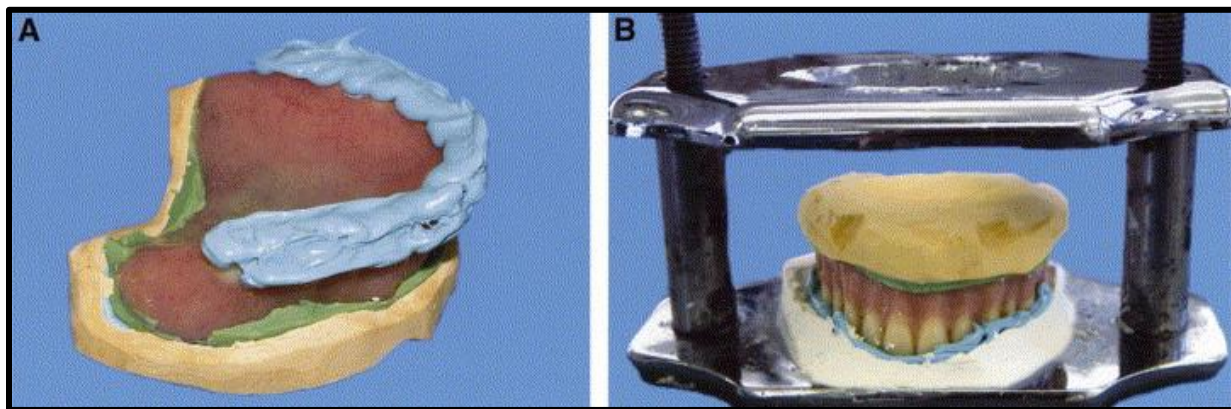


Fig. 1.11 Jig Method. **A.** Vinyl polysiloxane material added to occlusal and incisal edges of denture teeth. **B.** Denture/impresion/cast secured to bottom half of reline jig (**Plummer and Hall, 2004**)

1.4.2.2 Flask Method

Procedure:

1. After boxing, plaster is poured onto the impression surface and a cast is made.
2. Excess impression material at the margins is removed and corrections are made with wax.
3. After the ground surface of the denture base is coated with a plaster separator, the denture is placed in a flask,
4. The two halves of the flask are separated and impression material on the basal surface of the denture is removed.
5. Tin foil or sheet wax is affixed to flabby gums or bone tonus, and a relief is made.
6. The cast is coated with a resin separator, or a silicone mould material is painted over the denture prior to investing the body. This is done to create a flexible mould.
7. One layer of the basal surface of the denture is removed, a fresh surface is exposed, and this is coated with a resin primer, after which autopolymerizing resin is built up.
8. The upper and lower halves of the flask are combined, excess resin is removed, and the dentist waits for the resin to harden (once curing is complete, dentures are remounted on an articulator and occlusal adjustments are made).
9. Adjustments are made to sites needing morphological correction and relief, and polishing is done (**Veeraiyan et al., 2003**), (**Shiga et al., 2007**).

1.4.2.3 Articulator Method

Procedure:

1. Once the impression is received, a cast is poured immediately. Maxillary cast is mounted on a semi adjustable articulator with the help of a face-bow transfer.
2. With an acrylic bur in a handpiece, remove a thin layer of resin from the interior of the denture to freshen the surface. Reduce the borders 2 to 3 mm with a bur.
3. Paint the cast with tin foil substitute
4. Mix autopolymerizing resin and add resin to the interior of the denture, place additional resin on the cast, taking care to fill the borders
5. Seat the denture into the indentations, and close the articulator, expressing the excess resin
6. Cure the relined denture in a pressure container to minimize porosity (**Veeraiyan et al., 2003**).

1.5 Rebasing

Rebasing involves replacing the entire acrylic base (**Panchevska et al.,2017**). The essential objective of any rebasing technique, is to establish a new basal seat. This is a procedure in which as much as possible of the denture base material is removed and replaced with new base material (**Soratur,2006**). A rebase prescription may be regarded as an inferior clinical alternative to the more expensive and time-consuming provision of new dentures (**Zarb et al., 2013**).

Rebasing Procedure

Irrespective of the methods used, rebasing differs from relining only in denture trimming prior to wax-up. This is the only step where rebasing differs from relining. After articulating or flasking the cast the denture is removed from the cast and the entire denture base is trimmed leaving just 2 mm of acrylic around the porcelain teeth. The acrylic is retained to preserve the positions of the denture teeth. After trimming the denture wax up is done over all the supporting structures of the cast (**Veeraiyan et al., 2003**).

The overall procedural Rebasing steps are the following :

1. At the chair side, impression with ZOE paste is made using old denture as a tray.
2. Make a stone cast from this impression.
3. Trim the cast, the cast with the denture is mounted on the articulator.
4. Plaster index is made on the opposing member of the articulator
5. Remove the denture from the cast.
6. Remove as much as possible of the old denture base.
7. Replace on the plaster register
8. Place a roll of soft wax on the remaining shallow strip of resin. Close the articulator to the correct relationship.
9. Complete the wax-up.
10. Invest, De-wax, pack the new resin, and cure, finish and polish. (**Soratur, 2006**).

CHAPTER TWO
CONCLUSION

CHAPTER TWO: CONCLUSION

As a closure to the literature review, relining and rebasing procedures are intended to enhance the tissue surface of complete and partial denture. In addition to being an economic alternative to denture reconstruction, these procedures have multiple clinical implications and applications.

It is worth emphasizing that to reach complete and partial prosthesis relining success, it is necessary to have sufficient knowledge of the indications, contraindications, advantages, disadvantages, characteristics and types of relining materials.

Several materials and different methods are applicable for relining and rebasing procedures, each has its benefits and drawbacks which are governed by each material's physical and biochemical characteristics.

REFERENCES

References

A

- Al Rifaiy, Mohammad Q., (2012); "Shear Bond Strength Between Light Polymerized Hard Reline Resin And Denture Base Resin Subjected To Long Term Water Immersion", The Saudi Dental Journal, 24(1) ;23-27
- Anusavice, Kenneth J, Ralph W. Phillips, Chiayi Shen, and H R. Rawls. (2013); "Phillips' Science of Dental Materials". Elsevier/Saunders, 492-494.
- Aquino AR, Barreto AO, de Aquino LM, Ferreira ÂM, Carreiro Ada F. :(2011); "Longitudinal clinical evaluation of undercut areas and rest seats of abutment teeth in removable partial denture treatment". J Prosthodont.; 20(8):639-42

B

- Baat C, Kalk W, Hof M. (1993): "Factors connected with alveolar bone resorption among institutionalized elderly people" Community Dentistry and Oral Epidemiology. ; 21(5):317-320.
- Babu K, Perisetty D, Kumar Y, Gunaranjan T, Venkatesh A, Lavanya T et al. (2019) : "A Beginners guide for soft liners- Mini review". Journal of Pharmaceuticals Science and Research. 11(12):3802-3805.

C

- Carr, Alan B., and David T. Brown, (2011): "Mccracken's Removable Partial Prosthodontics". 12th ed., Elsevier Mosby; 300-302
- Christensen, Gordon J., (1995) : "RELINING, REBASING PARTIAL AND COMPLETE DENTURES", The Journal Of The American Dental Association, 126, 503-506 .
- Chaves, Carolina & Machado, Ana & Vergani, Carlos & de Souza, Raphael & Giampaolo, Eunice (2012): "Cytotoxicity of denture base and hard chairside reline materials: A systematic review". The Journal of prosthetic dentistry. 107(2), 114-127.

- Chladek G, Żmudzki J, Kasperski J. (2014): “Long-Term Soft Denture Lining Materials. Materials”. *Materials*;7(8):5816-5842.

D

- D. L. S, Hussain Z, Uthkarsh.(2007): “Textbook of complete denture prosthodontics”. 1st ed. New Delhi, India: Jaypee Brothers/Medical Publishers;

F

- Falatehan, N. and Gandhanya, R. (2018): “One-visit relining procedure in patient with loss of vertical dimension: Case report”. *Scientific Dental Journal*, 2(3), 115.

J

- Jemli Safa, Mahfoudi AlaEddine, Jaouadi Jamila, (2021): “Rebasing as a Problem-Solving in Complete Dentures”. *Saudi J Oral Dent Res*. 6(6):227-233. 227.

K

- Kranjčić, Josip & Stunić, Maja & Celebić, Asja & Komar, Daniel & Mehulic, Ketij & Vojvodić, Denis. (2013): “Denture relining as an indicator of residual ridge resorption”. *Medicinski glasnik : official publication of the Medical Association of Zenica-Doboj Canton, Bosnia and Herzegovina*, 10(1) 126-32.
- Kubo Sawamura, Cinthia, Amaral Reskalla, Fabrício, Edson Alves de Campos, (2014): “Relining of removable dentures: a literature review”. *RSBO Sul-Brasileira de Odontologia Magazine*; 11 (2): 192-198.
- Knechtel, Mark & Loney, Robert, (2007): “Improving the Outcome of Denture Relining”. *Canadian Dental Association*. 73(7); 587-591.

L

- Lechner SK, Champion H, Tong TK. (1995): “Complete denture problem solving: a survey”. *Aust Dent J.*; 40(6):377-80.
- Leinfelder, Karl F., Douglas A. Terry, and Mark E. Connelly, (2007): “The Art Of Denture Relining”, *Inside Dentistry*, 3(5).

M

- Manappallil, John J, (2010) “Basic Dental Materials”, 2nd ed. (New Delhi: Jaypee Brothers Medical Publishers; 133-137.
- Mahalaxmi, S, (2013): “Materials Used In Dentistry” ,1st edn Wolters Kluwer Health,; 168-172
- McCabe, John F, and Angus W. G Walls, (2008): “Applied Dental Materials”, 9th ed. Oxford, UK: Blackwell Publishing, 124-129
- Meister, Lissandra & Kovalik, Ana & CV, Pellissari & Bail, Michele & EB, Campagnoli & Jorge, Janaina & Campanha, Nara, (2015): “Effect of post-polymerization heat treatment on a denture base acrylic resin: histopathological analysis in rats”. *International Journal of Dentistry and Oral Science*, v. S1, n. 001;1-7.

N

- Noort, Richard van, and Michele E Barbour, (2013) “Introduction To Dental Materials” , 4th ed Elsevier Mosby;180-182.

O

- Özkan, Yasemin K, (2018): “Complete Denture Prosthodontics”, 1st edn Springer International Publishing; 213-220.

P

- Phoenix, Rodney D, David R Cagna, and Charles F DeFreest, (2008):“Stewart's Clinical Removable Partial Prosthodontics” , 4th ed Quintessence Publishing Co.; 932-941.
- Prakash, Vijay, and Ruchi Gupta, (2017): “Concise Prosthodontics- E Book” , 2nd edn ,Elsevier; 535-540.
- Prasad D. A, Prasad B, Shetty V, Shastry C, D. K. (2014): “TISSUE CONDITIONERS: A REVIEW”. Journal of Health and Allied Sciences NU.;04(02):152-157.
- Plummer K, Hall G. (2004): “Simplifying the use of a reline jig”. The Journal of Prosthetic Dentistry;91(4):399-400.

R

- Rahn AO, Heartwell CM Jr. (1993): “Textbook of complete dentures”. 5th ed. Baltimore: Lippincott, Williams and Wilkins; 425-428.
- Rathi Shraddha, Verma Ankit (2018): “Resilient liners in prosthetic dentistry: An update”. International Journal of Applied Dental Sciences; 4(3): 34-38

S

- Shiga, Hiroshi & Terada, Yoshihiro & Ikebe, Kazunori & Akagawa, Yasumasa & Hirai, Toshihiro & Inoue, Hiroshi. (2007) “Guideline for Relining”. Prosthodontic Research & Practice. 6(4); 209-216.
- Soratur, S. (2006): “Essentials of Prosthodontics”. 1st ed. Jaypee Brothers Medical Publishers; 75-77.

V

- Veeraiyan, D., Ramalingam, K. and Bhat, V. (2003): “Textbook of Prosthodontics”. 1st ed. Jaypee Brothers Medical Publishers;238-248.

Y

- Yankova, M., Yordanov, B., Dimova-Gabrovska, M. and Apostolov, N., (2019): “RESILIENT LINING MATERIALS FOR REMOVABLE DENTURES: TYPES, COMPOSITION AND TECHNOLOGY”. Journal of IMAB - Annual Proceeding (Scientific Papers), 25(3);2632-2639.

Z

- Zarb, George A, and Aaron H Fenton, (2013): “Prosthodontic Treatment For Edentulous Patients”, 13th ed. Mosby; 144 -149.