

Ministry of higher education and scientific research

University of Baghdad College of Dentistry



Xerostomia in Complete Denture

By: Ayat Walid Khalid

SUPERVISED BY: DR. NOOR FALAH

قال تعالى:

يُزَفِّعُ اللَّهُ الَّذِينَ آمَنُوا مِنْكُمْ وَالَّذِينَ

أُوتُوا الْعِلْمَ كَرَجَاتٍ

صدق الله العظيم

سورة المجادلة - الآية 11

Declaration

This is to certify that the organization and preparation of this research has been made by the graduate student **Ayat Walid Khalid** under my supervision at the College of Dentistry, University of Baghdad in partial fulfillment of the requirement for the degree of Bachelor of Dental Science.

(Supervisor): **Dr.Noor Falah**

B.D.S., M.Sc

Signature:

Dedication

I dedicate this research to my family who have always believed in me and supported me throughout my life. Last but not least, I would like to thank my great supervisor **dr.Noor Falah** for all her help.

Ayat

List of contents

Title No.	Title	Page no.
	List of content	5
	List of figures	6
	List of tables	7
	List of abbreviation	7
	Introduction	8
	Aim of the review	9
	Chapter One. Review of literature	10
1.1	Background	10
1.2	Diagnosis of xerostomia	14
1.3	etiology	19
1.3.1	Drug Induced Xerostomia	19
1.3.2	Toxicity Related to Cancer Radiotherapy and chemotherapy.	20
1.3.3	Physiological or Disease-Related Aging.	22
1.3.4	Autoimmune Disease.	22
1.3.5	Other Conditions.	22
1.4	signs and symptoms of Xerostoma	25
1.5	Dental Implications of Xerostomia	25
1.6	xerostomia effect on complete denture	26
1.7	Treatments:	27
1.7.1	Patient education	27
1.7.2	Preventive therapies	28
1.7.3	strategies for relieving dry mouth health-	29
1.7.4	oral health specific recommendations	29

1.8	prosthetic therapy	30
1.8.1	denture reservoir	30
	Chapter two: Conclusions	31
2.1	Conclusions	31
	References	32

List of figures:

Figure No	Figure title	
1	salivary glands	14
2	Xerostomia	15
3	Cone beam computed tomography (CBCT) sialography.	16
4	by photographic appearance of the tongue	18
5	antidepressant	19
6	causes of xerostomia	21
7	Sjögren syndrome	23
8	Dental Implications of Xerostomia	26
9	treatment of xerostomia	27
10	Amifostine Injection.	28
11	denture reservoir	30

list of tables:

Table No.	Table Title	Page No.
1	Saliva components and functions	11
2	Salivary glands secretions and components	12
3	Medicines and drugs with side effects on salivary secretion.	20

List of abbreviations

AIDS	Acquired immunodeficiency syndrome
CMC	carboxymethylcellulose
HIV	human immunodeficiency virus
OTC	over the counter
hSSPCs	human salivary stem/progenitor cells
PAL	palatal secretion
PAR	parotid secretion
SJS	Stevens-Johnson syndrome
TENS	transcutaneous electrical nerve stimulation

INTRODUCTION

Saliva is one of the most versatile, multifunctional substances produced by the body and has a critical role in the preservation of the oropharyngeal health. It comprises a serious and mucinous component and is secreted by the major salivary glands, the mucins in the saliva serve to protect and lubricate the hard and soft tissues of the mouth, protecting them from chemical and mechanical damage. [**cruze *etal.*, 2016**].

Composition: It is composed of 98% water, the rest 2% is composed of mucus, glycoproteins, enzymes, antibacterial as secretory IgA and lysoenzyme and bacterial component. [**Narh *et al.*, 2008**].

Saliva is a complex mixture of fluids that provides several protective functions, including cleansing the oral cavity, facilitating speech and swallowing, protecting oral tissues (including teeth) against physical and microbial insults, and maintaining a neutral PH. [**Pedersen andBelstrøm,2019**].

Reduced salivary flow can cause difficulties in tasting, chewing, swallowing, and speaking; it can also increase the chance of developing dental caries, demineralization of teeth, tooth sensitivity, and/or mucosal infections.[**Plemonsetal.,2015**].

Xerostomia is a relatively common complaint that can make the wearing of the dentures extremely uncomfortable for the affected edentulous patients. To overcome this problem, various techniques have been proposed including the preventive measures, management of symptoms, measures to increase the salivary flow, use of saliva substitutes and reservoir dentures [**Chandu and Hombes, 2011**] .

Aim of the Review

The goals of treating Xerostomia include identifying the possible causes relieving discomfort, and preventing complications (e.g: Candida, halitosis).

CHAPTER ONE: REVIEW OF THE LITERATURE

1. Background

Xerostomia is the dryness of the mouth which is due to the changes in the composition of saliva or reduced salivary flow. Patients may have increased susceptibility to periodontal diseases, opportunistic infections like oral candidiasis, chemical, mechanical and biological injuries. The lack of adequate saliva may have negative impact in denture wearing patients resulting in difficulty during mastication and swallowing of food. Reduced retention of dentures may also drive the patients to compromised emotional wellbeing and reduced quality of life. **[Sandra et al., 2003]**

Severity of dry mouth symptoms ranges from mild oral discomfort to significant oral disease that can compromise the patient's health, dietary intake, and quality of life. Estimates of xerostomia prevalence in the general population vary widely depending on case definitions used and differences in study samples (e.g., age range, health status. **[Terrie, 2016]**

Previous studies have reported xerostomia prevalence estimates ranging from 10 to 26% in men to 10 to 33% in women. **[Furness et al., 2013].**

A 2018 systematic review reported an overall estimated prevalence of xerostomia in approximately 22% of the global population. **[Agostino et al., 2018].**

Xerostomia prevalence is generally higher among older individuals, typically due to polypharmacy and with the onset of various medical conditions over time. Saliva is a mixture of secretions from the major (i.e., parotid, submandibular, sublingual) and minor salivary glands located in the oral mucosa. [Cohen-Brown and Ship, 2008].

A summary of the Saliva components and functions can be seen in the table:[Leeetal.,2011].

Table (1). Saliva components and functions.

Functions	Components
Digestion	Amylase, lipase, ribonucleases, proteases, water, mucins
Phonation	Water, mucin
Taste	Water, gustin
Lubrication	Proline rich glycoprotein IgA
Cleansing	water
Preparing food for swallowing	Water, mucin, Amylase
Maintaining mucosa integrity	Water, mucin, electrolyte

The salivary glands in mammals are exocrine glands that produce saliva through a system of ducts. Humans have three paired major salivary glands (parotid, submandibular, and sublingual), as well as hundreds of minor salivary glands. Salivary glands can be classified as serous, mucous or seromucous (mixed). In serous secretions, the main

type of protein secreted is alpha-amylase, an enzyme that breaks down starch into maltose and glucose, whereas in mucous secretions the main protein secreted is mucin, which acts as a lubricant as below when we see in the table 2 and figure 1 .[*Martini et al.,2012*; ; *Al-Quran et al. , 2011*]

In humans, between 0.5 and 1.5 liters of saliva are produced every day, the secretion of saliva (salivation) is mediated by parasympathetic stimulation; acetylcholine is the active neurotransmitter and binds to muscarinic receptors in the glands, leading to increased salivation. [*Edgar et al.,2012*].

Table (2) Salivary glands secretions and components

Gland	Secretion type	componetes
parotid	serous	Amylase Proline-rich proteins Agglutinins Cystatins Lysozymes Extraparotid glycoproteins Na, ca, Cl, P04, K IgA
sublingual	mucous	Mucins: MG1 MG2 Lysozymes Na, ca, Cl, P04, K IgA
submandibular	mixed	MG1

		Mucin Cystatins Lysozymes Na, ca, Cl, P04, K IgA
palatine	mucous	Amylase Na, K, ca, Cl, P04 Cystatins IgA

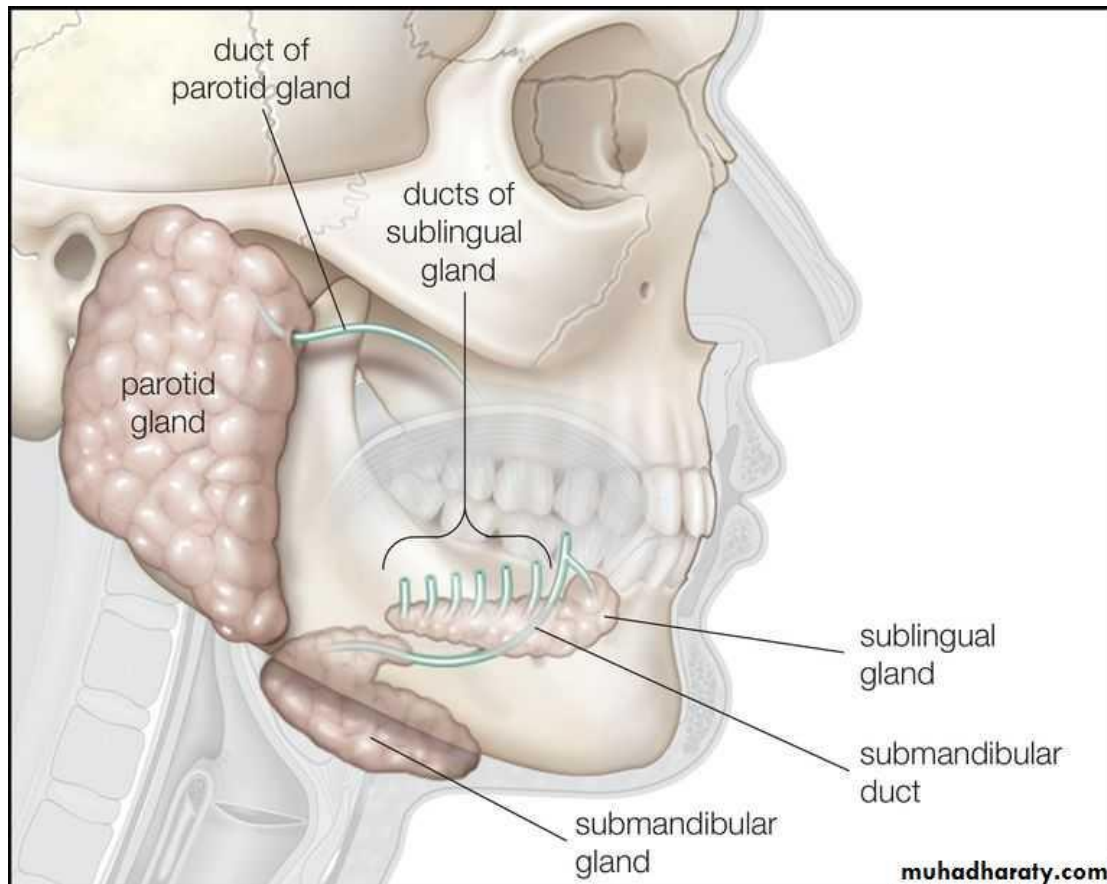
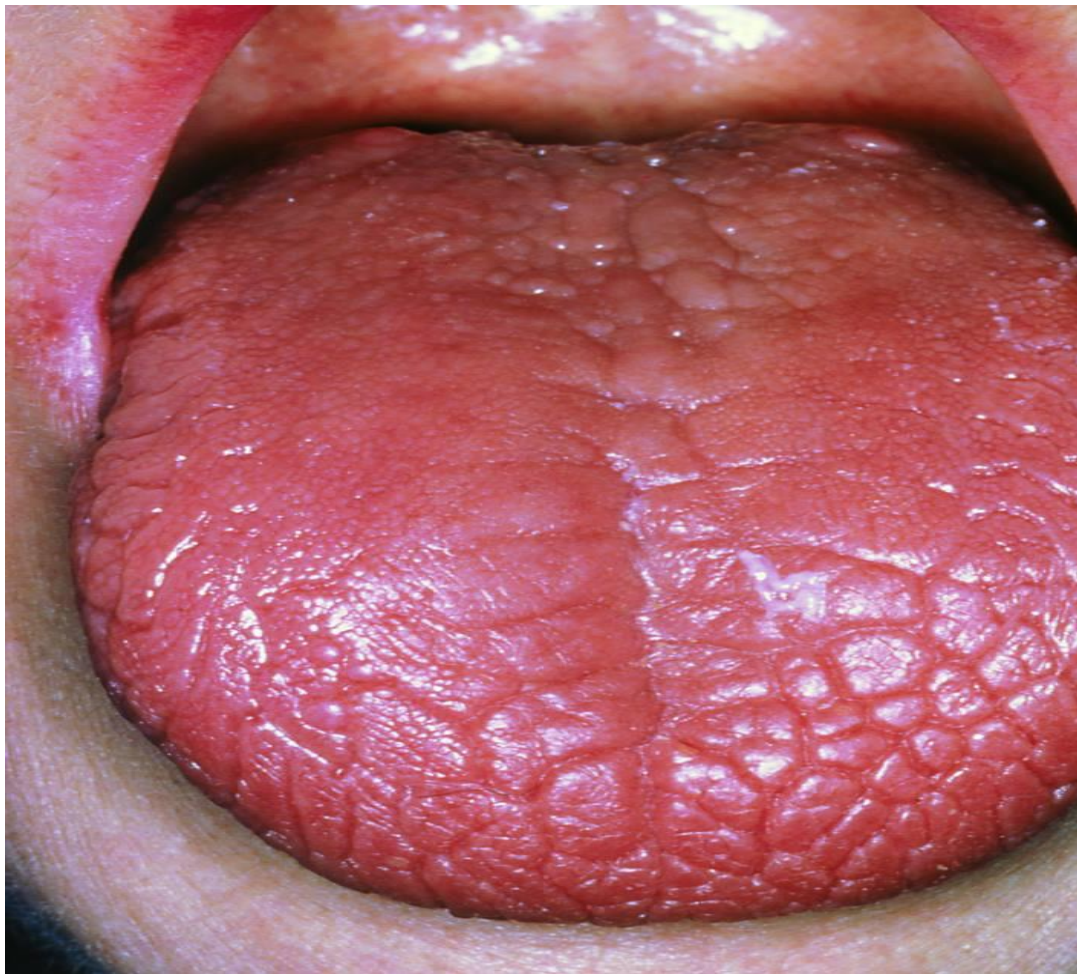

Figure (1) salivary glands

1.2. Diagnosis of xerostomia

The objective of the diagnosis is to provide treatment as early as possible, thus minimizing side effects in patients suffering from xerostomia. In order to establish a diagnosis of xerostomia, a clinical history is essential to identify the possible etiological factors, It is necessary to investigate its causes. Thus, three orders of factors need to be known: the occurrence of systemic diseases, medication, and the history of radiation therapy. Questions are asked to the patient, trying to find out if he feels the dry mouth sensation, whether he needs to wet his mouth, if he can eat a wafer without drinking water, if the tongue chews the food and clings to the teeth, and the daily water intake daily among other issues [Tschoppe., etal.,2011; Chan *etal.*,2012].



Figure(2):Xerostomia

The qualitative clinical diagnosis of xerostomia is made through the observation of clinical signs such as palpation of the salivary glands, observation of the oral mucosa and its hydration, cracked lips, saliva under the tongue, appearance and texture of saliva, the identification of caries, candidiasis and burning sensation, and others, Several methods have been developed to evaluate the level of dryness of the mouth, the discomfort being the most used: sialography, sialo chemistry, sialometry and scintigraphy, salivary gland biopsy, ultrasound, magnetic resonance, and computed tomography [Visvanathan and Nix ,2016].

Sialography is a technique of imaging that involves the injection of a retrograde form of radiopaque material into the salivary duct system in order to define the anatomy of the glands. This test is very important to demonstrate the presence of nodules or sialectasis, but it has its disadvantages, such as: the difficulty of the technique, since it is invasive and the patient can react acutely or chronically with the contrast material. The biopsy of the major or minor salivary glands allows the detection of inflammatory infiltrations, acinar destruction and dilation of salivary channels with thick mucus, and sometimes fibrosis [Ugga *etal.*,2017;].

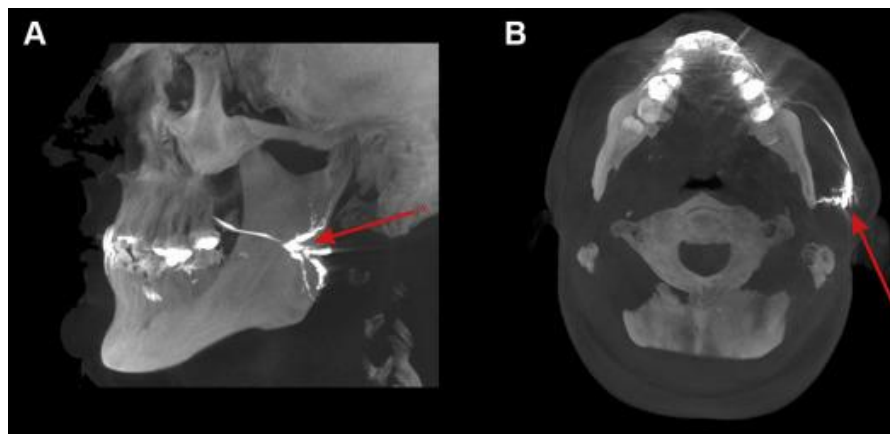


Figure (3): Cone beam computed tomography (CBCT) sialography

Ultrasound, magnetic resonance, and computed tomography are tests that may also contribute to the diagnosis of diseases of the salivary glands, to establish the condition of the symptom or to evaluate a possible salivary glandular dysfunction [**Singh and Tonk ,2012**].

the determination of salivary flow rate. Sialometry and scintigraphy (an imaging diagnostic method of nuclear medicine that allows the study of the physiology of the various organs) are complementary tests that must be performed in order to evaluate the involvement of the salivary glands in patients with xerostomia. Sialometry is a relatively common procedure in normal clinical practice and include determination of stimulated salivary flow rate (s-SFR), unstimulated salivary flow rate (u-SFR), palatal and parotid secretion (PAL)and(PAR).[**Chambersetal.,2004**].

These measurements are the simplest methods of evaluating the salivary glandular function. It is essential to measure the salivary flow, that is, the amount of saliva produced per unit of time. Very low unstimulated and stimulated salivary flow rates or hypo salivation are defined as <0.1 and <0.7 mL/min, respectively [**Delli, 2014**].

At rest, secretion ranges from 0.25 to 0.35 mL/min and is mostly produced by the submandibular and sublingual glands, Under stimulation, the parotids account for 50% of salivary volume. Determining the stimulated and unstimulated salivary flow is a procedure to measure the amount of saliva it produces a person at a given time. Generally, the stimulated salivary flow is measured for 5 min and unstimulated salivary flow is measured for 15 min [**McMillan and Tsang, 2005**].

This kind of measuring has the advantage of being easily implemented, low-cost, and could be available to most of the population at risk, the diagnosis of salivary gland dysfunction is based on data derived from the symptoms reported by the patient, clinical examination leading to verification of the clinical signs and determination of stimulated salivary flow.[Foxetal.,1987].

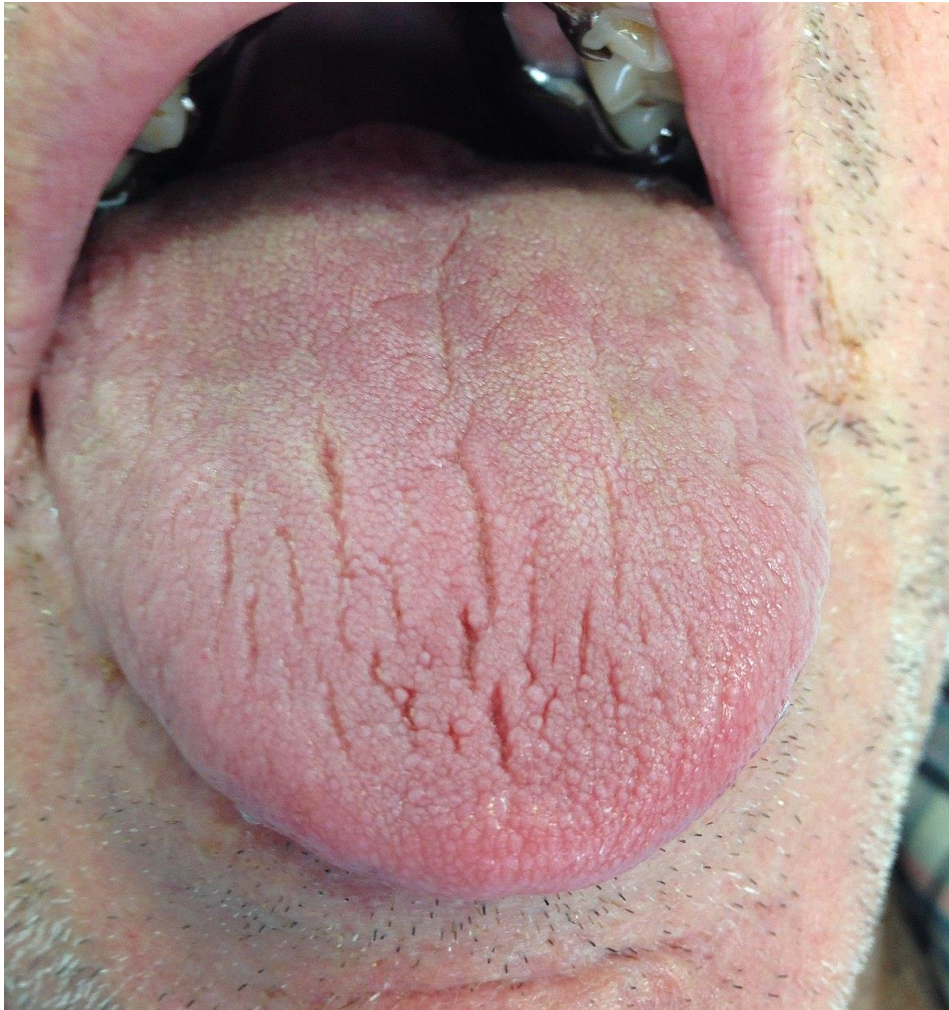

Figure (4) : picture is about an oral dryness by photographic appearance of the tongue and show in this appearance.

1.3. ETIOLOGY

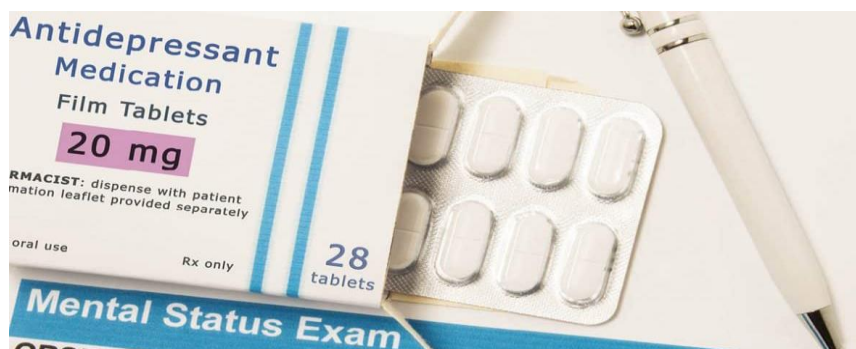1.3.1 Drug Induced Xerostomia

The most frequent cause of hypo salivation is use of certain medications, A systematic review in 2017 concluded that urologic medications, antidepressants and psycholeptics were associated with dry mouth in older adults. .[Villa *et al.*, 2015]

Another systematic review reported that many medications had strong to moderate evidence of being associated with salivary gland dysfunction like antidepressants and antimuscarinic, antihistamines decongestants, pain medications, diuretics, muscle relaxants, and antidepressants. [Jouhhjky , 2018]

The most common types of medications causing salivary dysfunction have anticholinergic effects, e.g., tricyclic antidepressants, antihistamines, antihypertensive medications, and anti seizure/antispasmodic drugs. [Ship. ,2007]

Drug substitutions may help reduce the dry mouth effects of certain medications (e.g., selective serotonin-reuptake inhibitor antidepressants tend to cause less dry mouth than tricyclic antidepressants).[Scully.,2003]



figure(5):antidepressant

The therapeutic and controlled doses of medications do not damage the salivary gland structure. For that reason, drug-induced xerostomia is reversible. The discontinued use of these drugs can restore salivary flow and these some drugs with side effect on salivary gland in the table [Batistaetal.,2014].

Table (3). Medicines and drugs with side effects on salivary secretion.

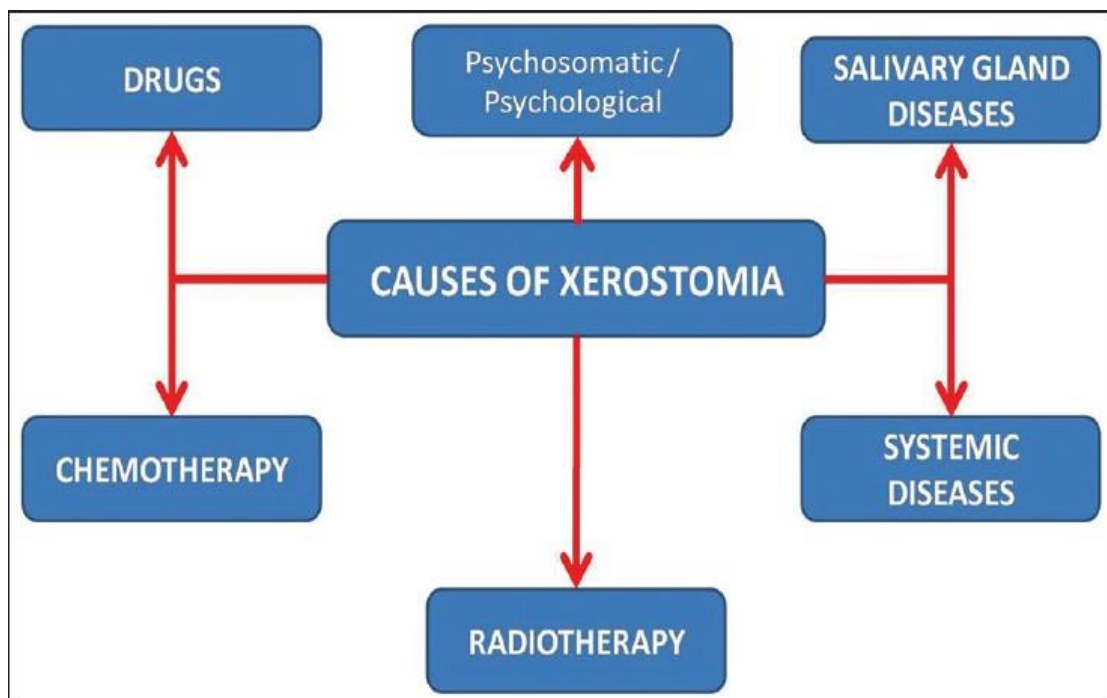
Medicine group	Examples
Anxiolytics	Lorazepam, diazepam
Anorectic	Fenfluramine
Anticonvulsants	Gabapentin
Antidepressants—tricyclic	Amitriptyline, imipramine
Antidepressants —SSRI	Sertraline, fluoxetine
Antihistaminics	Loratadine
Bronchodilators	Ipratropium, albuterol
Diuretics	Spironolactone, furosemide
Muscle relaxants	Baclofen
Sedatives	Flurazepam
Antihypertensive	Prazosin hydrochloride
Antiarthritic	Piroxicam

1.3.2 Toxicity Related to Cancer Radiotherapy and chemotherapy:

Oral complications of cancer chemotherapy or head and neck cancer radiotherapy. can be acute or chronic. [Dodds, 2002]

These therapies can cause xerostomia/salivary gland hypo function via direct toxicity to salivary glands and oral tissues or indirect damage due to regional or systemic toxicity. Generally, cancer chemotherapy causes acute toxicities that resolve following discontinuation of therapy and healing of damaged tissue, whereas radiation therapy can cause acute oral toxicity, as well as induce permanent tissue damage that can put patients at lifelong risk. [Ship, 2007]

Xerostomia can also occur following hematopoietic stem-cell transplantation and as part of salivary gland graft-versus-host disease. Sialadenitis, or infection of the salivary gland, is another potential acute oral toxicity associated with chemo/radiotherapy. Radioactive iodine, which is used to treat some thyroid cancers, can damage salivary glands (primarily the parotid glands) in a dose-dependent fashion [Bailyn, 1928].



Figure(6): Causes of xerostomia

1.3.3 Physiological or Disease-Related Aging.

Xerostomia affects 30% of patients older than 65 years and up to 40% of patients older than 80 years; this is primarily an adverse effect of medication(s), although it can also result from comorbid conditions such as diabetes, Alzheimer's disease, or Parkinson's disease. [Stein and Aalboe, 2015]

Xerostomia, while common among older patients, has been found to be twice as likely to occur in adult patients who take one of more drugs daily when compared with medication-free individuals. Xerostomia prevalence is also higher among individuals with an intake of more than four daily prescription medication, the exact mechanisms whereby some drugs determine xerostomia or hypo salivation are still unknown. Salivary dysfunction associated to drugs may occur through anticholinergic, cytotoxic action, sympathomimetic, or by damaged ion transport pathway in the acinar cell [Yellowitz and Schneiderman, 2014; Devan, 1999]

1.3.4 Automation Disease:

Sjögren disease (formerly known as Sjögren syndrome) is the second most common autoimmune connective-tissue disease and is the systemic condition most frequently associated with salivary dysfunction and xerostomia. Sjögren's syndrome (SjS, SS) is a long-term autoimmune disease that affects the body's moisture-producing (lacrima and salivary) glands, and often seriously affects other organs systems, such as the lungs, kidneys, and nervous system. Primary symptoms are dryness (dry mouth and dry eyes, pain and fatigue. Other symptoms can include dry

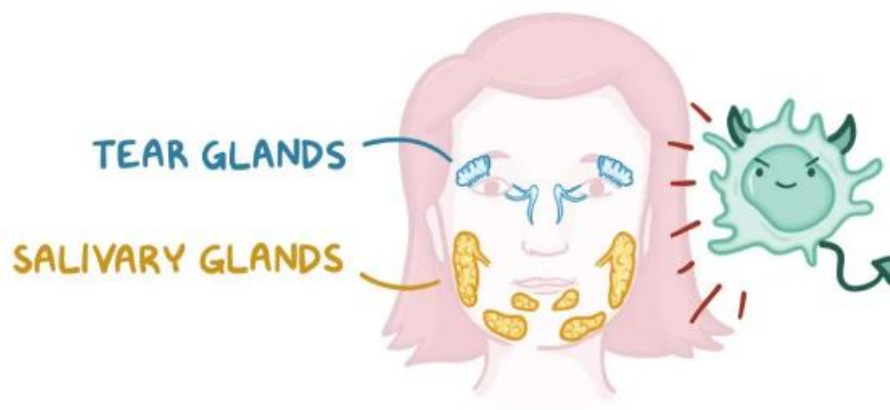
skin, vaginal dryness, a chronic cough, numbness in the arms and legs, feeling tired, muscle and joint pains, and thyroid problems. Those affected are also at an increased risk (15%) of lymphoma. [John H., Klippel,2012;•Aida,2006]

SJOGREN SYNDROME

* AUTOIMMUNE DISORDER

↳ TYPICALLY OCCURRING in WOMEN

↳ IMMUNE CELLS ATTACK EXOCRINE GLANDS



Figure(7):Sjögren syndrome

1.3.5 Other Conditions.

Other conditions associated with dry mouth include: [Terrie,2016].

- Cystic fibrosis
- Graft-versus-host disease
- Hepatitis C virus infection

- **HIV infection/AIDS**
- **Hormonal changes (e.g., pregnancy or menopause)**
- **Lymphoma**
- **Nerve damage from a head or neck injury**
- **Poorly controlled diabetes**
- **Psychogenic causes**
- **Salivary gland agenesis or aplasia**
- **Uncontrolled hypertension**

Potential lifestyle causes of xerostomia include the use of alcohol or tobacco use, or the consumption of excessive caffeine or spicy food.

1.4. Signs and symptoms of Xerostomia:

- a sticky, dry, or burning feeling in the mouth
- trouble chewing, swallowing, tasting, or speaking
- altered taste or intolerance for spicy, salty, or sour foods or drinks
- a dry or sore throat
- cracked, peeling, or atrophic lips
- a dry, rough tongue
- mouth sores
- an infection in the mouth (e.g., oral candidiasis)
- hoarseness of the voice
- halitosis (bad breath)
- inability to retain dentures or otherwise poorly fitting removable prostheses.

[Fox and Ship, 2008]

Xerostomia symptoms may also worsen at night because salivary output reaches its lowest circadian levels during sleep, and the problem can be exacerbated by mouth breathing. [**Turner and Ship ,2007**].

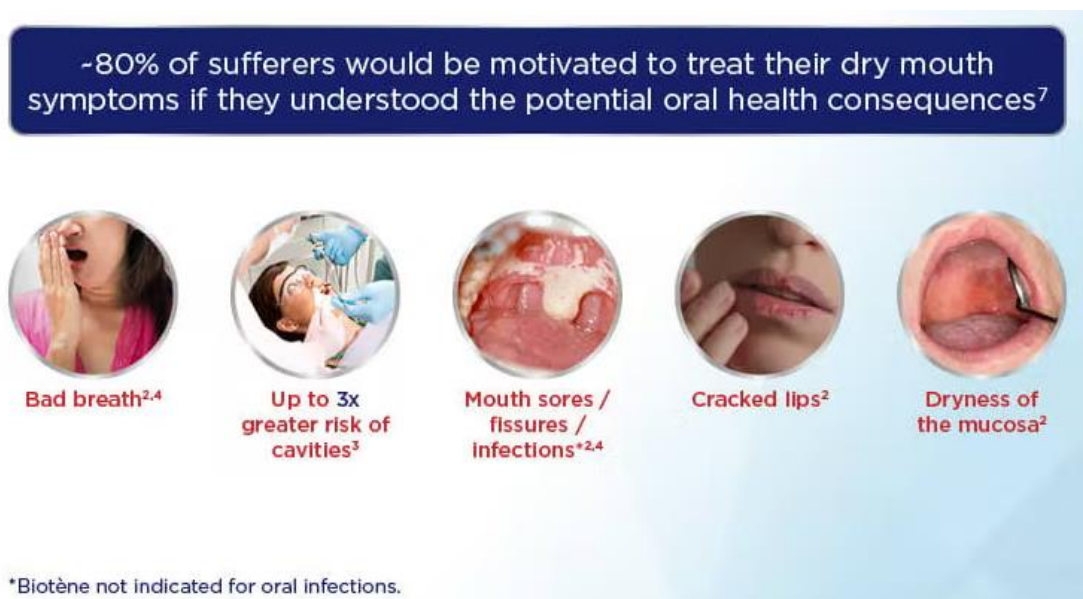1.5. Dental Implications of Xerostomia:

Patients with complaints of dry mouth should undergo a detailed medical and dental history to help with early detection and identification of potential underlying causes. [**Ying and Thomson, 2015**]

In patients with xerostomia or salivary gland hypo function, oral examination may reveal dry and friable oral mucosa and the tongue may appear dry and fissured. Patients may commonly have dental caries (especially root, cervical, or incisal/cuspal tips), plaque accumulation, gingivitis, and/or periodontitis.

Infections (e.g., oral candidiasis) and enlargement of salivary glands from sialadenitis may also be present. Other oral manifestations evident on examination may include angular cheilitis, mucositis, traumatic oral lesions, and/or difficulty in wearing/retaining oral prostheses.

[Agostini et al., 2018].



figure(8): Dental Implications of Xerostomia

1.6 xerostomia effect on complete denture:

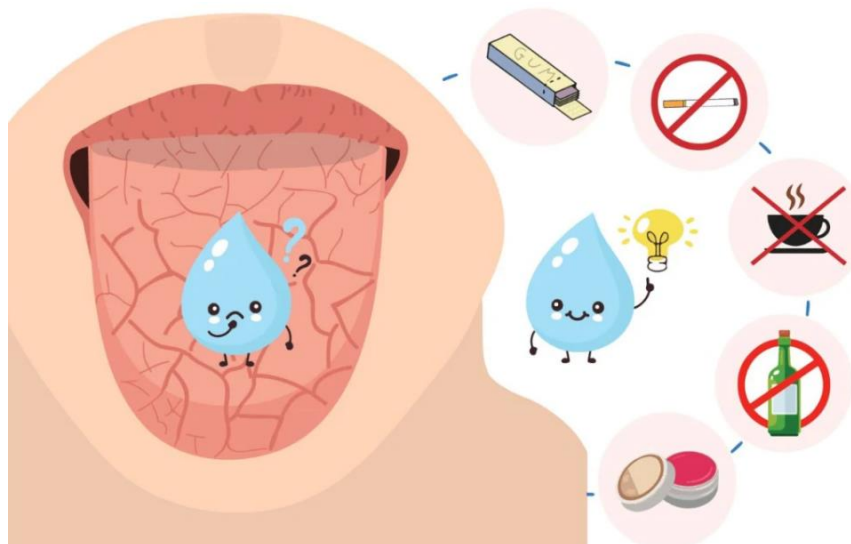
xerostomia, is likely to cause problems with all the functions of saliva (Denture retention, lubrication, cleansing and antimicrobial) so that a general, and significant, reduction in the quality of life results. Reduced retention of dentures is a particular problem for edentulous patients.

There may also be an increased susceptibility to denture trauma resulting in complaints of pain and in some case the burning mouth syndrome.

1.7. Treatments:

1.7.1. Patient education

Patients should receive detailed information about the potential causes of dry mouth and the potential sequelae of impaired salivary secretion, such as dental caries, candidiasis, and mucosal complications. Therefore, patients should be encouraged to have preventive oral health care such as dental hygiene habits and regular dental visits, Another palliative action to minimizing symptoms and preventing oral complications is water intake, drinking water frequently, and remaining hydrated is an important treatment for symptoms of dry mouth. [Fossaluzza,2008; • Devishree *etal.*,1981].



figure(9):treatment of xerostomia

1.7.2.Preventive-therapies:

Amifostine has been approved for prevention of xerostomia, in head and neck squamous cell carcinoma patients undergoing radiotherapy, A recent systematic review that included randomized controlled trials suggested that the drug amifostine prevents the feeling of dry mouth in people receiving radiotherapy to head and neck (with or without chemotherapy) in the short- (end of radiotherapy) to medium-term (3 months after radiotherapy),However, amifostine has adverse effects such as nausea, vomiting, hypotension, transient, hypocalcemia, and allergic reactions [Khurshudian,2003; Seinfeld *et al.*,2002]

Then, the benefits of amifostine should be weighed against its high cost and side effects and this a picture to the injection in figure (11) below:

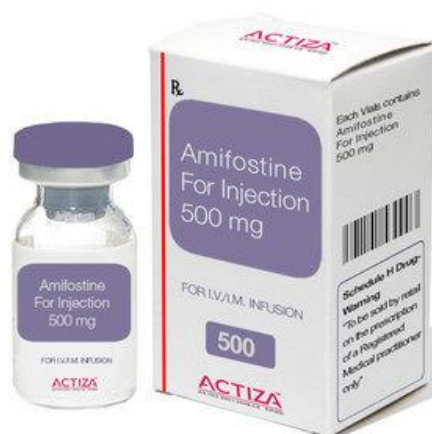

Figure (10) Amifostine Injection.

1.7.3.Strategies for relieving dry mouth:

These include: [Navazesh,2012; Kumar *et al.*,2009]

- sipping water or sugarless, caffeine-free drinks
- sucking on ice chips
- using lip lubricants frequently (e.g., every two hours)
- chewing sugar-free gum or sucking on sugar-free candy
- avoiding salty or spicy food or dry, hard-to-chew foods
- avoiding sticky, sugary foods
- avoiding irritants such as alcohol (including alcohol-containing mouthrinses²⁰), tobacco, and caffeine
- Drinking fluids while eating carefully
- using a humidifier at night

1.7.4 Oral health-specific recommendations:

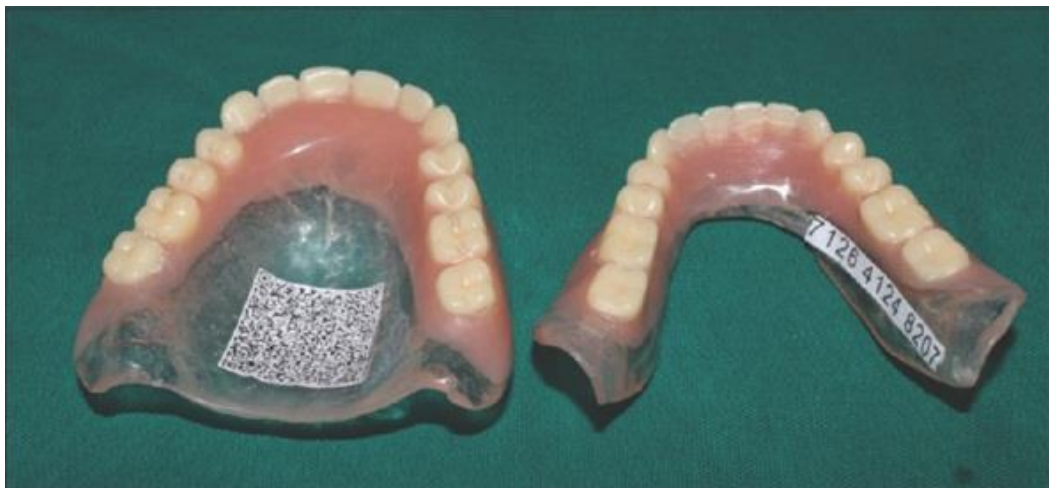- include the following for patients with dry mouth: [Hayes Met al., 2016]
- brush teeth gently at least twice a day with fluoridated toothpaste
- floss teeth every day
- schedule dental visits at least twice a year (with yearly bitewing radiographs)
- use of a prescription-strength fluoride gel (0.4% stannous fluoride, 1.1% sodium fluoride) daily to help prevent dental decay
- prompt treatment of oral fungal or bacterial infections
- application of 0.5% fluoride varnish to teeth

- dental soft- and hard-tissue relines of poorly fitting prostheses and use of denture adhesives

1.8. Prosthetic therapy

1.8.1 Denture reservoir

a particular method for prosthetic rehabilitation, the so-called "reservoir" denture, is presented. A complete denture is produced with conventional techniques but has a small container for artificial saliva. For mandibular dentures the container is sub-divided into 3 inter-communicating chambers and is situated in the lingual flange; for maxillary dentures, a single chamber is situated in the palatine concavity. [R Branchi et al., 2003], The reservoir of the upper denture functiones satisfactorily, this was found to effective in reducing the discharge of saliva substitute from the reservoir below in figure (11) the dental resviior in lower arch. [M Hirvikangas et al., 1989]



figure(11): denture reservoir.

CHAPTER TWO

2.1 CONCLUSION

1. Association of the perception of dry mouth among denture wearers with oral symptoms and function. Xerostomia is significantly associated with increased age and smoking. Xerostomia adversely affects oral functions and overall satisfaction with dentures. Dry mouth [Xerostomia] may lead to loose dentures, irritations, sores and possible infection for denture wearers. Clinician needs to identify the possible cause for the xerostomia condition and provide the patient with appropriate treatment.
2. It is important to have an appropriate comprehension of diverse causes of xerostomia to develop a systematic approach that includes collaboration with physicians to facilitate interdisciplinary patient care.
3. A comprehensive management of xerostomia is also necessary and it should incorporate patient education, lifestyle modifications, and adequate pharmacological and non-pharmacological therapies to improve the patient's quality of life.
4. Since most of the successful therapies are depending on the parenchymal gland affection, it is essential to know new therapeutic approaches to fully recover in vivo the gland's function or to develop new bioengineered salivary tissues.
5. Wearing complete dentures can be an extremely uncomfortable experience for the people with Xerostomia. Various treatment modalities have been suggested in the literature to overcome the problem of xerostomia in complete denture patients. Incorporating reservoirs containing salivary substitutes, into dentures, is one of these treatment

modalities. This new split denture technique resulted in a reservoir denture that provided good lubrication of the oral tissues, was easily cleaned by the wearer and was produced from routine denture materials.

References

A

- Agostini B.A., Cericato G.O., Silveira E.R.D., *et al.* (2018) How common is dry mouth? Systematic review and meta-regression analysis of prevalence estimates. *Braz Dent J*;29(6):606-18.

B

- Batista MJ, Lawrence HP, Sousa MLR. (2014) Impact of tooth loss related to number and position on oral health quality of life among adults. *Health Qual Life Outcomes*; 12: 165 10.1186/s12955-014-0165-5
- Baum BJ, Alevizos I, Zheng C, Cotrim AP., *etal.*, (2012) Early responses to adenoviral-mediated transfer of the aquaporin-1 cDNA for radiation induced salivary hypo function. *Proceedings of the National Academy of Sciences of the United States of America.*;109:19403-19407. DOI: 10.1073/pnas.1210662109
- Brandt J.E., Priori R., Valesini G., *etal.*, (2015). Sex differences in Sjögren's syndrome: A comprehensive review of immune mechanisms. *Biology of sex differences*; 6:19-19.

C

- Carr A. B. and Brown D. T., (2015). McCracken's Removable Partial Prosthodontics 13th ed. Mosby, p 4–20.
- Chambers M.S., Garden A.S., Kies M.S., (2004). Radiation-induced xerostomia in patients with head and neck cancer: Pathogenesis, impact on quality of life, and management. *Head & Neck.*;26:796-807. DOI: 10.1002/hed.20045
- Chiappelli F. (2012) No strong evidence that any topical treatment is effective for relieving the sensation of dry mouth. *Evid-based Dent*;13(1):16-17.
- Cohen-Brown G., Ship J.A., (2004). Diagnosis and treatment of salivary gland disorders. *Quintessence Int*;35(2):108-23

D

- Davies, Andrew N; Thompson, Jo (2015). "Parasympathomimetic drugs for the treatment of salivary gland dysfunction due to radiotherapy". *Cochrane Database of Systematic Reviews* (10)
- Dawes C., Pedersen A.M., Villa A., *et al.* (2015) The functions of human saliva: A review sponsored by the world workshop on oral medicine vi. *Arch Oral Biol.*
- Delli K., Spijkervet F.K., Kroese F.G(2014). Xerostomia. Monographs in

□ Dhiman RK Col, Roy Chowdhury SK, (2009). Midline Fracture in Single Complete Acrylic Vs Flexible Dentures. *Mjafi*. (2009). 65:141–145.

E

- Edgar M., Dawes L., Colin K. (2012). *Saliva and oral health* (4th ed.). Stephen Hancocks. p. 1.
- Eyigor S. (2013) Dysphagia in rheumatological disorders. *World Journal of Rheumatology*. F
- Fossaluzza V. (1984). Bromhexine in symptomatic treatment of Sjogren syndrome. *Klinische Monatsblätter für Augenheilkunde*.
- Fox P.C., Ship J.A. (2008) Salivary gland diseases. *Burket's oral medicine, diagnosis & treatment: People's Medical Publishing House USA Ltd (PMPH)*. p. 191-222.
- Furness S., Birchenough S, McMillan R. (2011) Interventions for the management of dry mouth: Topical therapies. *Cochrane Database Syst Rev* (12): Cd008934.
- Furness S., Bryan G., McMillan R., *etal.*, (2013) Interventions for the management of dry mouth: Non-pharmacological interventions. *Cochrane Database Syst Rev*. (9): Cd009603.

G

- Gad, M.M., (2017). Removable partial denture designing: variation of hard and soft tissue anatomy and maxillary major connector selection. *Int. J. Dentistry Oral Sci*. 4, 457–463. H
- Han P, Suarez-Durall P, Mulligan R. Dry mouth: A critical topic for older adult patients. *Journal of Prosthodontic Research* (2015).
- Hayes M., Da Mata C., Cole M., *etal.*, (2016). Risk indicators associated with root caries in independently living older adults. *Journal*.

I

- Idowu AT. Al-Shamrani SM. (1995) Pattern of tooth loss in a selected population at King Saud University College of Dentistry. *The Saudi Dental Journal*.
- Intraoral electrostimulator for xerostomia relief: A long-term, multicenter, open-label, uncontrolled, clinical trial. *Oral Surgery, Oral Medicine, Oral Pathology, Oral Radiology*. J
- Jablonski R.Y., Barber M.W., (2015) Restorative dentistry for the older patient cohort. *Br Dent J*;218(6):337-42.

K

- Kawara M., Kaomiyama D., Kimoto S. (1998): distortion behavior of heat cured acrylic in long low temperature and conventional processing method. *J Dent Res*, 1998, 77(6):1446-1453

L

- Lone, M.A., Shah, S.A. and Mir, S., (2019). Pattern of partial edentulism based on Kennedys classification among dental patients in Kashmir: retrospective study.
- Lowe L.G., (2004). Flexible denture flanges for patients exhibiting undercut tuberosities and reduced width of the buccal vestibule: a clinical report. *J Prosthet Dent*.
- Lynge Pedersen A.M., Belstrøm D. (2019) The role of natural salivary defences in maintaining a healthy oral microbiota. *Journal of Dentistry* 2019;80: S3-S12.

M

- Madhankumar S, Mohamed K., (2015) Prevalence of partial edentulousness among the patients reporting to the Department of Prosthodontics Sri Ramachandra University Chennai, India: An epidemiological study. *J Pharm Bioallied Sci.*;7(Suppl 2): S643–7.
- Mahabadi M.S., Hoshang K.A. and Chiman D.T., (2013). Incidence of partial edentulism and its relation with age and gender. *Zanco Journal of Medical Sciences* 2013. 17(2) 463-470
- Martini, Frederic H.; Nath, J.L., *et al.*, (2012). *Fundamentals of anatomy & physiology* (9th ed.). Pearson Benjamin Cummings.
- Mese H., Matsuo R., (2007) Salivary secretion, taste and hyposalivation. *J Oral Rehabil*;34(10):711-23.

- Miranda-Rius J., Lahor-Soler E., Farre M., (2015) Salivary secretory disorders, inducing drugs, and clinical management. *Int J Med Sci*.

N

- Nallaswamy D. *Textbook of prosthodontic. Glossary of Prosthodontic Terms*.
- Nascimento S., Frazão P., Bousquat A., *et al.* (2013) Condições dentárias entre adultos brasileiros de 1986 a 2010. *Rev Saude Publica*.
- Neurohr F. (1939) *Partial Dentures: A System of Functional Restoration*. 1st ed.

- Newton JP, Mcmanus FC, Menhenick S. (2004) Jaw muscles in older overdenture patients. Gerodontology.

P

- Parisis D., Chivasso C., Perret J., (2020). Philadelphia, PA: Lea & Febiger; p. 120-37.
- Phoenix R.D., Mansueto M.A., and Ackerman N.A., (2004): Evaluation of mechanical and thermal properties of commonly used denture base resins. J Prosthodont.
- Plemons JM, Al-Hashimi I, Marek C.L. (2014), American Dental Association Council on Scientific A. Managing xerostomia and salivary gland hypofunction: Executive summary of a report from the American Dental Association Council on Scientific Affairs. American Dental Association (2014).
- Plemons JM, Al-Hashimi I, Marek C.L. (2015) Managing xerostomia and salivary gland hypofunction: A report of the American Dental Association Council on Scientific Affairs. American Dental Association. February 2015. [Note: This report was retired effective June 16.
- Pratt M, Stevens A, Thuku M, et al. Benefits and harms of medical cannabis: A scoping review of systematic reviews. Syst Rev (2019).

R

- Raj, B.J.R., (2016). Attitude of patients towards the replacement of tooth after Extraction. Journal of pharmaceutical sciences and research, 8(11), p.1304.
- Roessler DM. Complete denture success for patients and dentists. Int Dent J (2003).

S

- Scully C. (2003). Drug effects on salivary glands: Dry mouth. Oral Dis.
- Shigeyama C., Ansai T., Awano S., *etal.*, (2008) Salivary levels of cortisol and chromogranin A in patients with dry mouth compared with age-matched controls. Oral Surgery, Oral Medicine, Oral Pathology, Oral Radiology, and Endodontics;106:833-839.
- Ship J.A., (2002) Diagnosing, managing, and preventing salivary gland disorders. Oral Dis;8(2):77-89.
- Stafford GD, Huggett R, MacGregor AR, Graham J, (1986). The use of nylon as denture base material. Dent. (1986).

- Stein P., Aalboe J., (2015) Dental care in the frail older adult: Special considerations and recommendations. J Calif Dent Assoc.
- Steinfeld S.D., Demols P., Appelboom T. (2002) Infliximab in primary Sjogren's syndrome.

T

- Tan E.C.K., Lexomboon D., Haasum Y., *etal.*, (2018). Medications that cause dry mouth as an adverse effect in older people: A systematic review and metaanalysis. Journal of the American Geriatrics Society;66(1):76-84.
- Tanaka A.K.S. (2021). Xerostomia and patients' satisfaction with removable denture performance: Systematic review.;52(1):46-55.
- Terrie Y.C. (2016) Dry mouth: More common and less benign than thought. Pharmacy Times. February (2016).
- Tschoppe P., Wolf O., Eichhorn M., *etal.*, (2011). Design of a randomized controlled double-blind crossover clinical trial to assess the effects of saliva substitutes on bovine enamel and dentin in situ.
- Turner M.D., Ship J.A., (2007) Dry mouth and its effects on the oral health of elderly people. J Am Dent Assoc;138 Suppl:15S-20 S.

U

- Ugga L., Ravanelli M., Pallottino A.A., *etal.*, (2017) Diagnostic work-up in obstructive and inflammatory salivary gland disorders. Acta Otorhinolaryngology Italica.

V

- Villa A., Abati S., (2011) Risk factors and symptoms associated with xerostomia: A cross-sectional study. Australian Dental Journal.
- Villa A., Connell C.L., Abati S., (2015) Diagnosis and management of xerostomia and hyposalivation. Ther Clin Risk Manag.
- Villa A., Wolff A., Narayana N., (2016) et al. World workshop on oral medicine vi: A systematic review of medication-induced salivary gland dysfunction. Oral Dis.

38

W

- Williams, R.J., Bibb, R., Eggbeer, D., *etal.*, (2006). Use of CAD/CAM technology to fabricate a removable partial denture framework. *The Journal of prosthetic dentistry*, 96(2), pp.96-99.
- Wolff A, Joshi RK, Ekström J, et al. A guide to medications inducing salivary gland dysfunction, xerostomia, and subjective sialorrhea: A systematic review sponsored by the World Workshop on Oral Medicine VI. *Drugs R D* 2017;17(1):1-28.
- Wu, Katherine J. (2020). "Doctors May Have Found Secretive New Organs in the Center of Your Head"

Y

- Yang G., Lin S., Wu Y., *etal.*, (2017) Auricular acupressure helps alleviate xerostomia in maintenance hemodialysis patients: A pilot study. *Journal of Alternative and Complementary Medicine.*;23:278-284.
- Yellowitz J.A., Schneiderman M.T. (2014) Elder's oral health crisis
- Ying Joanna N.D, Thomson W.M. (2015) Dry mouth - an overview. *Singapore Dent J* (2015).
- Young H., Carolyn A; Ellis C., *etal.*, (2011). "Treatment for sialorrhea (Excessive saliva) in people with motor neuron disease/Amyotrophic lateral sclerosis".

39

Z

- Zarb G.A., John H., Steven N., *etal.*, (2013). Prosthodontic Treatment for Edentulous Patients 13th Edition, Mosby ;9-10.
- Zarb, G.A., Bolender, C.L., Hickey, T.C. (1990): Boucher's prosthodontic treatment for edentulous patients, 10* ed., Mosby, St. Louis; 8, 77.
- Zero D.T., Brennan M.T., Daniels T.E., (2016). Clinical practice guidelines for oral management of Sjögren disease: Dental caries prevention. J Am Dent Assoc.
- Zoidis P, Papathanasiou I, Polyzois G, (2016). The Use of a Modified Poly-Ether Ether-Ketone (PEEK) as an Alternative Framework Material for Removable Dental Prostheses. A Clinical Report. J Prosthodont. (2016).