

Republic of Iraq
Ministry of Higher Education
and Scientific Research
University of Baghdad
College of Dentistry



Bite Raisers in Orthodontics – A Review

A Project Submitted to
The College of Dentistry, University of Baghdad, Department of
Orthodontics in Partial Fulfillment for the Bachelor of Dental
Surgery

By:
Nabaa Qais Raisan

Supervised by:
Assistant Professor
Dr. Mohammed Nahidh
B.D.S., M.Sc.

May, 2022

Certification of the Supervisor

I certify that this project entitled "**Bite Raisers in Orthodontics- A Review**" was prepared by **Nabaa Qais Raisan** under my supervision at the College of Dentistry/University of Baghdad in partial fulfillment of the graduation requirements for the Bachelor degree in dentistry.

Assistant Professor

Dr. Mohammed Nahidh

B.D.S., M.Sc. (Orthodontics)

The supervisor

22-5-2022

DEDICATION

I dedicate this work to

My Brilliant Mother and Father

My Supporting Generous Brothers

and Sisters

and to

The Department of Orthodontics

College of Dentistry, Baghdad University

Nabaa

Acknowledgement

First, I thank "**Allah**" almighty for granting me the will and strength to accomplish this project and I pray that his blessings upon me may continue throughout my life.

I offer my sincere gratitude to **Prof. Dr. Raghad A. Al-Hashimi**, the Dean of the College of Dentistry, University of Baghdad, for continuously supporting the undergraduate students.

My great thanks to **Assistant Prof. Dr. Yassir A. Yassir**, the Chairman of Orthodontic Department for his help and support during the orthodontic course.

I would like to acknowledge the efforts of my supervisor, **Assistant Prof. Mohammed Nahidh**, for his inspiration and continuous valuable scientific suggestions throughout the preparation of this project.

Deep thanks and gratitude to all teaching staff in the orthodontic department for their help and support throughout the theoretical and practical courses.

Table of Contents

| Title | Page No. |
|--|----------|
| Certification of the Supervisor | i |
| Dedication | ii |
| Acknowledgment | iii |
| Table of contents | iv |
| List of tables | vii |
| List of figures | vii |
| List of abbreviations | vii |
| Introduction | 1 |
| Aims of the study | 2 |
| Chapter one: Review of literature | 3 |
| 1.1. Definitions | 3 |
| 1.2. Nomenclatures | 3 |
| 1.3. Historical Development of Bite raisers | 3 |
| 1.4. Indications of Disarticulation | 4 |
| 1.5. Complications of Disarticulation | 5 |
| 1.6. Classification of Bite Raisers | 5 |
| 1.6.1. Anterior Bite Raisers | 6 |
| 1.6.1.1. Fixed Anterior Bite Raisers | 6 |
| A. Lingual Brackets | 6 |
| B. Metal Bite Turbos | 6 |
| C. Bite Builder/ Bite Jump | 7 |
| D. BiTurbo | 7 |
| E. Button Bite Turbo | 8 |
| F. Anterior Resin Turbos | 8 |
| G. Modified Nance Palatal Button or Fixed Anterior Acrylic Bite Plate | 9 |
| 1.6.1.2 Removable Anterior Bite Raisers | 10 |
| A. Hawley Anterior Bite Plate | 10 |

| | |
|---|----|
| B. Sved Bite Plane | 11 |
| C. Bite Plate with Expansion Screw | 11 |
| D. Anterior Inclined Bite Plane | 11 |
| E. Catalan's Appliance | 11 |
| F. Elastomeric Ligature with Guard | 12 |
| 1.6.2. Posterior Bite Raisers | 12 |
| 1.6.2.1. Fixed Posterior Bite Raisers | 12 |
| A. Temporary Crowns Bite Raiser | 12 |
| B. Nano Bite Plane | 13 |
| C. Posterior Resin Turbos | 14 |
| D. Güray Bite Raiser | 15 |
| E. Bonded Posterior Bite Plane with Expansion Screw | 16 |
| F. Spring Loaded Posterior Bite Blocks | 16 |
| G. Rapid Molar Intruder (RMI) | 17 |
| H. Magnetic Bite Blocks | 17 |
| I. Implant Supported Bite Blocks | 17 |
| J. Bonded Mandibular Posterior Bite Plane | 18 |
| K. Two Separate Posterior Bite Plates | 18 |
| 1.6.2.2. Removable Posterior Bite Raiser | 19 |
| A. Hawley Posterior Bite Plane | 19 |
| 1.6.2.3. Semi-Fixed Posterior Bite Raise | 20 |
| 1.7. Advantages of Bite Turbos | 20 |
| 1.8. Disadvantages of Bite Turbos | 21 |
| 1.9. Disadvantages of Removable Bite Plane | 21 |
| 1.10. Disadvantages of Bonded Bite Plane | 21 |
| 1.11. Material Choices | 22 |
| 1.12. Application of Bite Raisers | 24 |
| 1.13. Biomechanics | 25 |
| 1.13.1. Effect of bite plane on incisor inclination when anterior bite blocks are placed in patient's mouth | 25 |

| | |
|--|----|
| 1.13.2. Effect of bite plane on molar inclination when posterior bite blocks are placed in patient's mouth | 26 |
| 1.14. Effects of Bite Raisers on the Masticatory Functions and Electromyography | 26 |
| 1.15. Effects of Bite Raisers on the Condylar Position | 27 |
| 1.16. Factors Influencing the Choice of Bite Raisers' Location | 27 |
| 1.17. Delivery of Removable Bite Raisers | 28 |
| 1.18. Instructions to the Patient | 29 |
| Chapter Two: Discussion/ Comments | 30 |
| Chapter Three: Conclusions and Suggestions | 31 |
| 3.1. Conclusions | 31 |
| 3.2. Suggestions for further studies | 31 |
| References | 32 |

List of Tables

| Tables | Page No. |
|---|----------|
| Table 1: Different materials used in fabricating bite raisers | 23 |

List of Figures

| Figures | Page No. |
|---|----------|
| Figure 1: Anterior fixed bite raiser | 9 |
| Figure 2: Anterior removable bite raiser | 12 |
| Figure 3: Posterior fixed bite raisers | 19 |
| Figure 4: Hawley posterior bite plane | 20 |
| Figure 5: Semi-fixed posterior bite raiser | 20 |
| Figure 6: Types of bite raisers and their component materials | 22 |
| Figure 7: Effect of bite raiser on incisal inclination | 26 |
| Figure 8: Effect of bite raiser on molar inclination | 26 |

List of abbreviations

| | |
|-------|---------------------------------------|
| BIBRE | Bonded Inclined Bite Raisers Elastics |
| i.e. | That is |
| mm | Millimeter |
| PMMA | Poly Methyl Methacrylate |
| RMI | Rapid Molar Intrusion |
| TMJ | Tempromandibular joint |

INTRODUCTION

Bite opening is a procedure frequently needed over the course of fixed orthodontic treatments to eliminate unexpected occlusal contacts, which can cause the shearing of the mandibular brackets. Bite opening also allows easy tooth movement, which can be hindered by deep bites, telescopic bites, buccal non-occlusions, anterior crossbites, and posterior crossbites **(Ceen, 2002)**.

Orthodontic bite raiser refers to a synthetic surface particularly fabricated to be positioned anteriorly or posteriorly to provide a plane against which the teeth of the other arch can make contact with during occlusion so that full closure of the jaws is inhibited **(Roy et al., 2013)**.

The first bite plane used was fabricated from wrought silver then vulcanite material that were replaced by acrylic later on. Nowadays, light-cured orthodontic composite materials and band cement can be to the occlusal surfaces of the posterior molars or lingual surfaces of the anterior teeth to act as a bite raiser **(Kravitz et al., 2018)**.

Generally, there are three major types of bite raisers namely the fixed, semi-fixed and removable. The fixed one is hygienic, minimizes bulkiness, reduces interference with speech, and is less intrusive on the tongue space compared to a conventional removable bite plate. In addition, when bite-raising is used in patients with multi-brackets on every tooth, the orthodontic tooth movement is done without interference from the acrylic plate, and is easy to place on the tooth surfaces in one visit **(Pativetpinyo et al., 2018)**.

Although bite raisers offer many advantages, there are many problems associated with using them like the development of traumatic occlusion, teeth mobility and loss of vitality, TMJ disorders and undesirable tooth movements **(Singh et al., 2021)**.

Aim of the study

This study aimed to review the various types of bite raisers used in daily orthodontic practice, their advantages, disadvantages, the materials from which they are fabricated and the biomechanics for each use.

CHAPTER ONE

REVIEW OF LITERATURES

1.1. Definitions

According to **Daskalogiannakis (2000)**, occlusion can be defined as the relationship of the maxillary and mandibular teeth, as they are brought into functional contact, while disarticulation is the separation of the mandible from the maxilla through tooth-guided contacts.

Orthodontic bite raiser refers to an artificial surface specially fabricated to be placed either anteriorly or posteriorly to provide a plane against which the teeth of the opposing arch can contact during occlusion so that complete closure of the jaws is prohibited (**Roy *et al.*, 2013**).

1.2. Nomenclatures

Bite turbos, bite ramps, bite block, bite pillows, bite build-up, bite builder, bite opener, bite jump, bite plane, bite plate, occlusal pad, speed or bite bumps, disarticulator and deprogrammer (**Singh *et al.*, 2021**).

1.3. Historical Development of Bite Raisers

According to **Weinberger (1926)**, the first inclined plane was described by John Hunter in 1771 which was fabricated from wrought silver on the lower anterior teeth to correct a lingually blocked out tooth. Then, in 1803, Fox made a posterior bite plane by placing blocks of acryl on the posterior teeth in an attempt to remove the force of occlusion before moving teeth.

Henry Clay Quinby in 1883 illustrated a form of maxillary bite plate to take pressure off the back teeth so as to allow them to elongate. He also concluded that this reduction of anterior overbite would provide room for the lingual movement of the upper incisors.

W. G. Bonwill in 1889 illustrated and described a maxillary bite plate. The intent was not only to drive the inferior incisors up into their sockets but also to

allow the bicuspid and molars to come down and antagonize before the plate was removed.

N. W. Kingsley's bite plane, described in 1892, was the first maxillary inclined plane to be described in literature for the purpose of jumping the bite. This device was to be used to cause the mandible to move forward bodily from a posterior Class II to a normal Class I relationship. Kingsley mentioned the bite plane in 1879, but failed to elaborate on it at that time. Although not mentioned by him, his bite plane certainly would have had the effect of decreasing overbite, as does the flat maxillary plane (**Kingsley, 1892**).

Dr. Edward Angle used a plane and spur for the retention of cases in which the bite was jumped using the Kingsley bite plate (**Angle, 1907**).

In **1915**, **Suggett** summarized various uses of inclined plane in managing different cases of malocclusion.

Grieve (**1927**) described a buccal inclined plane in conjunction with a pin appliance to be used as a mandibular growth stimulator.

In **1997**, **Joe Mayes** of Ormco Corporation created a metal bite turbo as an alternative to the acrylic bite plate. Mayes's design was a simple modification of a lingual upper incisor bracket.

Güray (1999) developed a temporary bite raiser that is made of 0.040 inch stainless steel wire that was adapted to the occlusal surface of the maxillary first molar.

1.4. Indications of Disarticulation

Singh et al. (2021) listed down the main indications of disarticulation:

1. Protecting brackets from debonding and teeth from attrition due to the use of ceramic brackets.
2. Treating certain types of malocclusions affecting the three planes of space.
3. To unlock occlusion for antero-posterior or transverse correction.

4. To prevent certain undesirable tooth movement.
5. To manage some temporomandibular disorders.
6. Anchorage reinforcement.
7. Stopping functional shift (due to premature contact).
8. Aids in treating occlusal cant and asymmetry.

1.5. Complications of Disarticulation

As there are many indications for disarticulation, there are many complications or disadvantages (**Singh et al., 2021**):

1. Discomfort (eating /speech problems).
2. Traumatic occlusion, periodontal problem, mobility of teeth.
3. Wear and breakages.
4. Loss of teeth vitality.
5. Undesired teeth movements like intrusion, extrusion and lingual inclination.
6. Space opening.
7. Occlusal cant.
8. Bruxism.
9. Functional shift.
10. Temporomandibular disorder symptoms.

1.6. Classification of Bite Raisers

Generally, bite raisers can be classified into two broad categories according to their location into anterior and posterior bite raisers. Also they could be classified into fixed, removable and semi-fixed, moreover according to their function there are two subtypes, the flat or passive type and the inclined or functional type (**Singh et al., 2021**). The full description of each type will be presented below.

1.6.1. Anterior Bite Raisers

An anterior bite plane is generally given when disocclusion and changes in posterior dentition are required; in deep bite cases that are a result of infra-eruption of posterior teeth and decreased lower facial height or when disengagement of posterior contact is required to correct posterior crossbite and maxillary expansion (**Kravitz *et al.*, 2018**).

1.6.1.1. Fixed Anterior Bite Raisers

A. Lingual Brackets

Fine (1991) used the orthodontic lingual brackets as a bite raiser by bonding them on the palatal surface of the maxillary incisors. This technique has proven to be simple, as well as time- and cost-effective, for both patient and practitioner (Figure 1A). Patients have reported rapid adaptation to the lingual brackets with minimal alteration of masticatory function.

B. Metal Bite Turbos

In **1997**, **Mayes** of Ormco Corporation created metal bite turbos (Figure 1B). It was a simple modification of a lingual upper incisor bracket used by Fine.

Mayes listed down the advantages of his metal turbos:

1. Simple and durable.
2. Brackets can be placed on the lower anteriors earlier.
3. The posterior occlusion is freed up, allowing more rapid orthodontic movement.
4. The mandible is freed up to unlock occlusal interference inhibiting mandibular growth.
5. Both intra- and extracapsular muscular and disk problems may be aided with the deprogramming.
6. Removal is as simple as removal and cleanup of a lingual bracket or a stainless steel crown.

Sometimes it was difficult to place because of the variability of upper incisor palatal anatomy and also there were lispings and intolerable tooth vibrations, moreover; it could be broken and it was not adjustable.

In a recent randomized clinical trial evaluating the efficiency of reverse curve of Spee archwire and metal anterior bite turbos in treating deep overbite cases, the results showed that both means are effective in deep overbite correction, with less proclination and intrusion of lower anteriors, shorter treatment time and increase in the lower facial height in anterior bite turbos group (**Al-Zoubi et al. 2022**).

C. Bite Builder/ Bite Jump

It is made from tooth colored polyurethane material which has curved base optimizing its lingual placement (Figure 1C). It is designed to open deep bites about 5 mm with immediate results while protecting bare enamel. It can be bonded palatally to upper incisors to eliminate occlusal interference and reduce bond failure on lower brackets (**Orthotechnology product catalogue, 2022**). Some types are provided with guiding tip to facilitate the bonding and this can be removed easily (**Speed Dental product catalogue, 2022**).

D. BiTurbo

The first BiTurbo was developed in 2014 with a groove in the long-axis of the bondable bite opening device (to permit the use of a periodontal probe or other instrument to position and press-bond the BiTurbo to the enamel more efficiently and accurately) that was also curved to establish anterior guidance early in treatment (Figure 1D). It was manufactured as a one-piece bracket. Then **Voudouris et al. (2022)** improved the first generation (BT1) and developed the second generation (BT2) as a four-piece unit and included:

1. Bracket body with vertical groove (split), with incisal surface curvature
2. Braze (for flexibility).
3. Curved bonding pads to complement and adapt to the curved palatal anatomy of the upper central incisor for improved bond strength

4. Separate 80-gauge mesh for greater bond strength.

E. Button Bite Turbo

Here orthodontic buttons are fixed on the palatal surface of the upper anterior teeth on the dental models using dental wax. A 3 mm thickness of cold cure acrylic is placed over the waxed-up lingual buttons and after curing, the button bite turbo is retrieved and dewaxed, finished and polished and directly bonded before bonding of the appliance as shown in Figure 1E (**Prakash *et al.*, 2018**).

F. Anterior Resin Turbos

Because of the shortcomings with metal turbos, another type of turbos was introduced i.e. resin turbos (Figure 1F). Different materials like acrylic gels, band cement, bracket adhesives, and lingual retainer adhesive can be used to make turbos (**Kravitz *et al.*, 2018**). They can be fabricated chair-side via direct or indirect method or may be 3D customized (**Philippe, 1996; Tong *et al.*, 2020**).

Anterior resin turbos are indicated in low-angle patients, though anterior turbos should be used with caution in high-angle cases because of the risk of undesirable posterior extrusion (**Singh *et al.*, 2021**).

The most common site for anterior resin turbos is on the palatal aspect of the upper central incisors. Both central incisors are bonded to distribute the occlusal forces. Upper lateral incisors are rarely used because of their shorter roots, although this could be an alternative location if the patient develops a lisp. The deeper the bite, the more incisal be the turbo fabrication. They should be long enough for lower arch not to slip behind it or move it gingival towards a thicker part of the tooth and to allow for more forward path of closure (**Kravitz *et al.*, 2018**).

To reduce the risk of fracture of long turbos, they can be placed on maxillary cuspids initially, then moved to central incisors as the overjet is reduced. However; this may cause the mandible slide sideways, condylar position will be asymmetric, and the patient will be prone to temporomandibular joint pain.

Turbos are desired to be used for an average of 6 months, depending on how deep the initial overbite. At the same time, the clinician needs to be vigilant with regard to the periodontal health of the mandibular incisors as well (Singh *et al.*, 2021).

When the turbos are beveled they are known as functional turbos. They are constructed with beveled occluding surfaces that guide the opposing teeth toward the desired positions. Their most common application is in the correction of a mild anterior crossbite. Resin turbo material is bonded to the incisal edges of two or lower incisors and then beveled lingually. Upon contacting the beveled surface, the upper incisors are nudged forward and the lower jaw is directed posteriorly (Figure 1G). The dental crossbite will usually be corrected in about three months (Kravitz, 2019).

G. Modified Nance Palatal Button or Fixed Anterior Acrylic Bite Plate

A modified version of the Nance appliance or palatal acrylic button is that which incorporates a bite plate (Figure 1H). This appliance is invaluable as a treatment accelerator because it allows immediate placement of brackets on the lower anterior teeth yet the problem of oral hygiene is critical with this appliance (Pratiwi *et al.*, 2020).

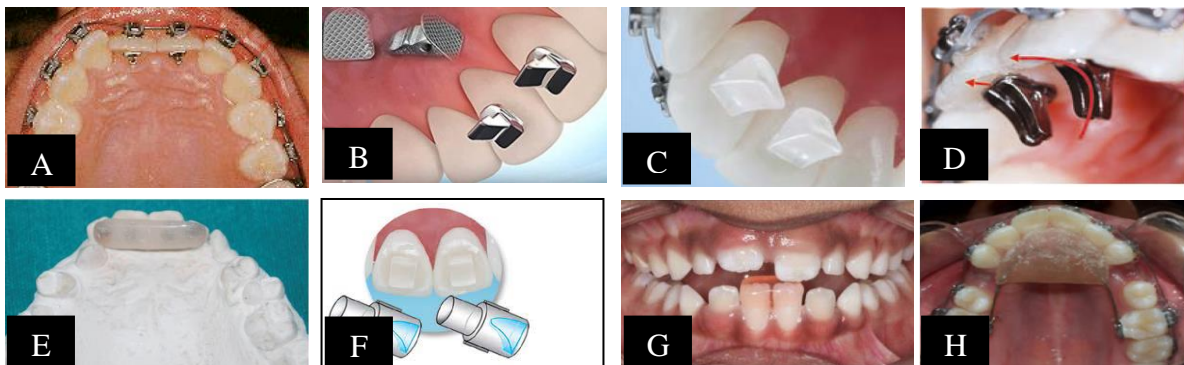


Figure 1: Anterior fixed bite raisers

A: Lingual bracket as a bite raiser (Fine, 1991), **B:** Metal bite raiser (Mayes, 1997). **C:** Bite builder (Orthotechnology product catalogue, 2022), **D:** BiTurbo (Voudouris *et al.*, 2022), **E:** Button bite turbo (Prakash *et al.*, 2018), **F:** Anterior resin bite turbo (Kravitz *et al.*, 2018), **G:** Anterior functional resin bite turbo (Kravitz, 2019), **H:** Modified Nance Palatal Button (Pratiwi *et al.*, 2020)

1.6.1.2 Removable Anterior Bite Raisers

A. Hawley Anterior Bite Plate

It is a regular Hawley appliance with an added acrylic platform in the anterior region behind upper incisor teeth which is made parallel to the occlusal plane and parallel to the long axes of lower incisors and therefore causes their intrusion (**Singh, 2015**).

The lower incisor bites on this plane leaving a gap between the posterior teeth. This warrants the elongation of posterior teeth which depends on the growth of alveolar bone. The new bone needs to be conditioned to withstand the stresses of mastication by the withdrawal of the bite plate gradually (**Phulari, 2017**).

These bite plane basically causes a differential eruption of posterior teeth causing reduction of deep bite and also cause relative intrusion of anterior teeth (by causing proclination) leading to leveling of curve of Spee. Further, in the case of posterior dental crossbite, the disocclusion of teeth enables easy use of cross elastics for correction. Moreover; in many cases of temporomandibular disorders, relief of pain, clicking and other symptoms of joint have been reported after the use of this plane. This is accredited to unloading of joint, relaxation of lateral pterygoid muscle and other elevators and neuromuscular deprogramming are among other reasons (**Singh, 2015; Phulari, 2017**).

The height of anterior bite plane should not interfere with freeway space and there should be a clearance of 2-3 mm space in posteriors (Figure 2A). Patients might place their tongue in the gap between posteriors if it is of more than 3 mm thus hindering the teeth from freely erupting. At the same time, high anterior bite planes may cause undue pain and trauma to the masticatory muscles, TMJ and lower incisors. This may also cause unfavorable clockwise rotation of the mandible, which may not be desired (**Singh et al., 2021**).

B. Sved Bite Plane

Another type of bite plane was introduced by **Sved (1944)** to reduce the side effect of upper anterior teeth proclination (Figure 2B). In this appliance, acrylic plate was extended up to the incisal edge of upper anteriors which prevented forward component of force and thus reducing the proclination of the incisors.

C. Bite Plate with Expansion Screw

The use of a removable appliance with a jackscrew and anterior bite plate (Figure 2C) was shown to be beneficial in the correction of deep bite for those with transverse deficiency in mixed dentition stage (**Singh, 2015**).

D. Anterior Inclined Bite Plane

It looks like a flat anterior bite plane, the difference is the incorporation of the anterior incline plane to engage lower incisors and cause the mandible to slide anteriorly (Figure 2D). The appliance with a reverse incline is useful in growing children with a mild superior protrusion, deep bite and mandibular retrusion. It is also used as a retention appliance after active functional therapy like twin block (**Emami et al., 2007**).

The upper anterior incline plane favors the forward movement of mandibular teeth from distal occlusion into neutral occlusion. To 'lock' the lower incisors in a desired forward position of the mandible, incisal edge indentations of lower incisors can be incorporated in the bite plane (**Singh, 2015; Phulari, 2017**).

E. Catalan's Appliance

It was introduced 150 years ago. In Catalan's appliance, lower inclines are used to correct the anterior crossbite. It causes the opening of a bite by the eruption of posterior teeth (Figure 2E). It is used during the eruptive stages of incisors. The incline of 45 degrees guides the lingually erupting incisor into proper occlusion. It is worn a maximum of 3 weeks but if it is worn for a long time, it leads to anterior open bite due to over-eruption of posterior teeth (**Tiwari et al., 2020**).

F. Elastomeric Ligature with Guard

It is developed by 3M Unitek Company with an external diameter of 3.1 mm (Figure 2F). It is latex free and designed to reduce the occlusal contact with the ceramic brackets in the mandible (3M Unitek catalogue, 2022). It is not readily available in many countries and its effectiveness is not studied yet.

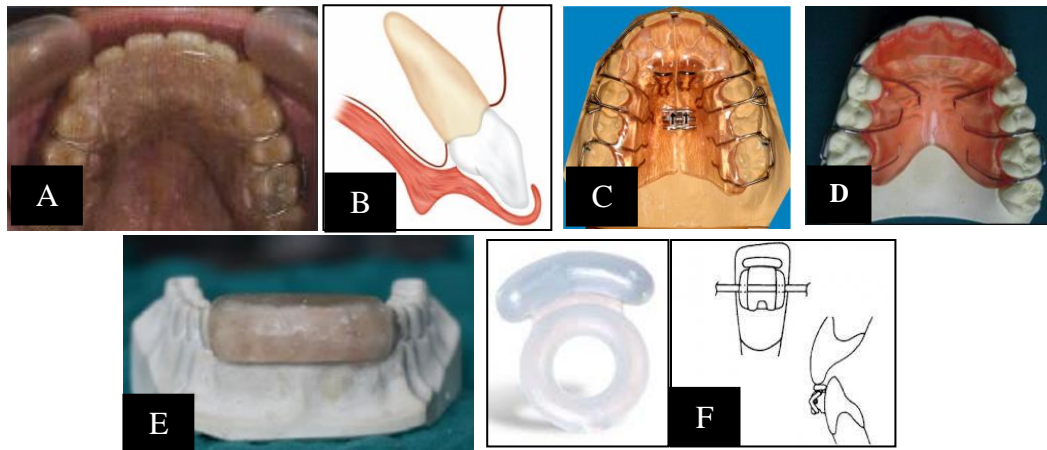


Figure 2: Anterior removable bite raisers

A: Hawley anterior bite plate (Singh, 2015), **B:** Sved plate (Phulari, 2017), **C:** Bite plane with expansion (Singh, 2015), **D:** Anterior Inclined Bite Plane (Emami *et al.*, 2007), **E:** Catalan's appliance (Singh *et al.*, 2021), **F:** Elastomeric Ligature with Guard (3M Unitek catalogue, 2022)

1.6.2. Posterior Bite Raisers

A posterior bite plane extends from the first premolar posteriorly to disocclude anterior teeth for correction of anterior crossbite. They have also been used for correction of open bite because of the vertical intrusive forces on the posterior segments. By intruding posterior teeth, along with correction of an anterior open bite, the mandible also rotates anti-clockwise and thus decreases lower anterior facial height (Singh, 2015; Phulari, 2017).

1.6.2.1. Fixed Posterior Bite Raisers

A. Temporary Crowns Bite Raiser

These are crowns fabricated bilaterally on molars with self-cure acrylic and cemented onto teeth with glass ionomer cement (Figure 3A). Care must be taken to ensure proper occlusal contact bilaterally. They act as temporary bite raisers and help in the correction of anterior crossbite. They have the advantage of being less bulky and thus lesser speech impairment (Vibhute *et al.*, 2006).

Stainless steel crown usage in orthodontics has been on the increase for bite-jumping, space maintenance and bite-opening therapy (Mayes, 1997). Ormco introduced its line of crowns with the orthodontist in mind which have several advantages:

1. Correct gingival contouring and reduced height eliminate or reduce the need for trimming.
2. Flatter interproximal walls take up less arch space than the more rounded, bulbous-shaped crowns that are popular for pediatric dentistry.
3. Broad, relatively flat occlusal surface accommodates tooth crown anatomy without necessitating reduction of the occlusal surface of the tooth.

The use of steel crowns is little now because they are cost effective and need stocks with different sizes and the presence of resin and metal turbos with simple technique in application encourage orthodontists to leave the crowns.

B. Nano Bite Plane

It is fixed type that consisted of a molar band with a well adapted zig-zag shaped 0.019×0.025 inch archwire that soldered at just two points to provide sufficient bond strength and minimize the bulkiness of the appliance, leaving the buccal side of the band free for other attachments if needed. The wire frame is covered by acrylic that is adjusted to the required height (Figure 3B).

It is considered simple, reliable, and effective in either arch, especially useful in uncooperative patients and in high-angle cases. To prevent overeruption of adjacent posterior teeth in vertically growing patients, the bite plane should be modified to include more of the posterior teeth if it must be used for more than four weeks. Both adults and adolescents tolerate the bite plane well, usually requiring only a few days to adapt in speech and chewing (Prasad *et al.*, 2008).

C. Posterior Resin Turbos

Posterior resin turbos are indicated in average-angle cases. Posterior resin turbos are usually placed on the supporting cusps of the mandibular first molars.

They can be placed on mandibular second deciduous molars in preadolescent patients (**Kravitz *et al.*, 2018**).

Some clinicians prefer them to be placed on maxillary molars or premolars for the ease of fabrication as isolation is better. However, posterior turbos are less effective in providing clearance for lower anterior brackets and may require excessive thickness in low-angle patients (Figure 3C).

They can be extended over bracket pad for added bracket retention. According to **Melson and Fiorelli (2013)**, anchorage loss can be prevented by built-up composite onlay on mandibular posterior teeth, providing deep intercuspation.

El-Bokle and Abbas (2020) and **El-Bokle (2021)** utilized a functional bite turbos that operate like a bonded Twin Block appliance (Figure 3D). They can also be placed on premolars to improve disarticulation in Class II patients, so that the mandible is disarticulated and repositioned as the occluding premolars slide along the beveled surfaces. These bonded inclined bite raisers are used in conjunction with full-time light short Class II elastics (i.e., bonded inclined bite raisers elastics [BIBRE]).

In addition, the use of bite raisers resulted in disocclusion, which facilitates sagittal correction by removing the effect of intercuspation that may impede forward mandibular growth or dentoalveolar correction.

The BIBRE can be placed at the beginning of fixed appliance treatment, in conjunction with light leveling archwires, unlike most fixed functional appliances that require at least 6 months of leveling and alignment until heavy archwires are placed. Thus, no time is wasted if the patient is at the end of the growth spurt. The BIBRE also has a versatile action on overbite correction. In open bite cases, the raisers are placed posteriorly on the molars to effect posterior intrusion and anticlockwise rotation of the mandible. In low angle cases, they can be placed more forward on the first premolars to enhance bite opening and increase of lower facial height.

The same technique can be applied in aligner patients by adding unfilled rectangular attachments to the occlusal surfaces of the aligners (**Kravitz *et al.*, 2018**).

D. Güray Bite Raiser

The Güray bite raiser is a prefabricated temporary bite raiser. It is made to be inserted into the headgear tubes and then adapted over the occlusal surface of the molars (Figure 3E). It is secured with ligature wire or elastomer and is available in two different sizes for children and adults (**Güray, 1999; Gokalp and Uslu, 2008**).

This type has the following advantages:

1. It can be placed or removed easily and quickly without patient discomfort or the need for special instruments.
2. The patient's bite relationship can be assessed as often as necessary by removing the ligature and hinging the device out of occlusion.
3. No laboratory procedures are required.
4. Patient acceptance has been comparable to that of other bite opening appliances.
5. The stainless steel appliance is adjustable and designed for use with either occlusally or gingivally placed headgear tubes.

Moreover the following disadvantages have been reported:

1. It may not allow headgear or auxiliary wires to be placed simultaneously.
2. It also should not be used in cases where anterior bite planes are required.
3. Long-term wear might produce some molar intrusion, which could be reversed with appropriate wire bending.

E. Bonded Posterior Bite Plane with Expansion Screw

Bonded hyrax is often used for maxillary crossbite correction in hyperdivergent patients. Bonded posterior bite plane disoccludes posteriors for unhindered expansion and when kept for long intervals will result in intrusion of molars (Figure 3F).

For best results, the bite is raised 3-4 mm beyond freeway space. A unilateral cross-bite is often the outcome of convenient shift of the mandible due to bilateral maxillary constriction. A maxillary expansion appliance with posterior bite plane would disengage the mandible from its laterally locked position and enhance maxillary expansion. Posterior bite plane is also useful in bilateral posterior cross-bite with similar benefits (**Singh, 2015; Phulari, 2017**).

F. Spring Loaded Posterior Bite Blocks

The spring-loaded block was described by **Woodside and Linder-Aronson (1986)**. These bite blocks cover the occlusal surface of posterior teeth and consist of helical springs made with 0.9 mm high strength stainless steel wires, the ends of which are embedded into the acrylic blocks. The helices are activated to deliver forces (Figure 3G).

The bite blocks can be connected bilaterally with 1 mm stainless steel wires or acrylic plates which can be extended up to the cingulum or can cap incisors to prevent their overeruption, They are activated from time to time, supplying additional force within the neuro-muscular system, besides the forces of the masticatory muscles. Because of its peculiar design, it was thought that the same appliance could also act as a habit-breaking appliance. With this appliance, the patient must apply active force to close his mouth, and this acts as a distraction therapy (**Doshi and Bhad, 2012**).

G. Rapid Molar Intruder (RMI)

The rapid molar intruder was used by **Carano et al. (2005)** to treat non-compliant patients with open bites. The device is fixed to the maxillary and mandibular molars with the help of bands. It consists of elastic modules and coil springs which help in the active intrusion of molars.

On occlusion, a force of 800grams is exerted on the teeth which is reduced to 450grams by the end of the first week and 250grams by the end of the second week. One drawback to treatment with RMI is buccal tipping of the crown as the line of action of the force is lateral to the center of resistance of molars. This can

be counterbalanced by using transpalatal and lingual arches. The RMI can be modified to be used with bite blocks instead of molar bands. Tubes can be added to the buccal side of the blocks and the RMI inserted into it. This has the added advantage of distributing the force of RMI to the entire block instead of concentrating all the force solely on the molars (**Carano *et al.*, 2005; Cinsar *et al.*, 2007**).

H. Magnetic Bite Blocks

Dellinger was the first to use magnets for the correction of open bite. He called the appliance the active vertical corrector (**Dellinger, 1986**). Repelling magnets are utilized in opposing arches to intrude teeth (Figure 3H).

Samarium cobalt magnets are used. Since this is a reactive material, it needs to be sealed in the oral environment meant as saliva can act as an electrolyte. The magnets can be embedded in acrylic and used. This would prevent both corrosion and leakage of potentially harmful products. Later on, another device was introduced in which neodymium iron boron magnets (three times stronger than samarium-cobalt magnets) coated with stainless steel were used. This appliance provides both lateral shearing forces and vertical forces.

I. Implant Supported Bite Blocks

The intrusion of posterior teeth with the help of posterior bite blocks combined with skeletal anchorage is a relatively newer technique. The use of coil springs or elastics along with temporary anchorage devices compounds the effect of posterior bite blocks and allows for enmass intrusion with good stability in non-growing patients.

It however is a comparatively invasive technique requiring incisions for the placement of the implant. Buccal flaring is controlled with transpalatal arch. Hooks are incorporated into the acrylic blocks to facilitate easy application of the elastics (**Doshi and Bhad, 2012**).

J. Bonded Mandibular Posterior Bite Plane

It consists of a 1mm stainless steel wire that adapted to the lingual surface of the lower anterior teeth (above the cingulum) extending from the lower first premolar to that in the other side and self-cure acrylic that extends on the mandibular posterior teeth from the first premolar to the second molar on both sides to form the posterior bite plane (Figure 3I). The acrylic should cover half of the buccal and lingual surface of the posterior teeth on both sides avoiding the extension to the gingival margins of the teeth (Sumathi, 2012).

K. Two Separate Posterior Bite Plates

It consisted of two acrylic bite blocks with stainless steel tubes (16-gauge needle) incorporated into the blocks (Figure 3J). Ligature wire extended through out the tube with one end below and the other above the contact aiding in fixation of the block in addition to glass ionomer cement (Ahmad *et al.*, 2014).

This technique has been found to be reliable and convenient, especially since it avoids the loosening of the bite block before patient's visit and keeps the bite open as desired. Moreover, the bite block can be given unilaterally without any chance of swallowing it, because it is tied with the help of ligature/brass wire. Patient compliance with the appliance is also found to be excellent.

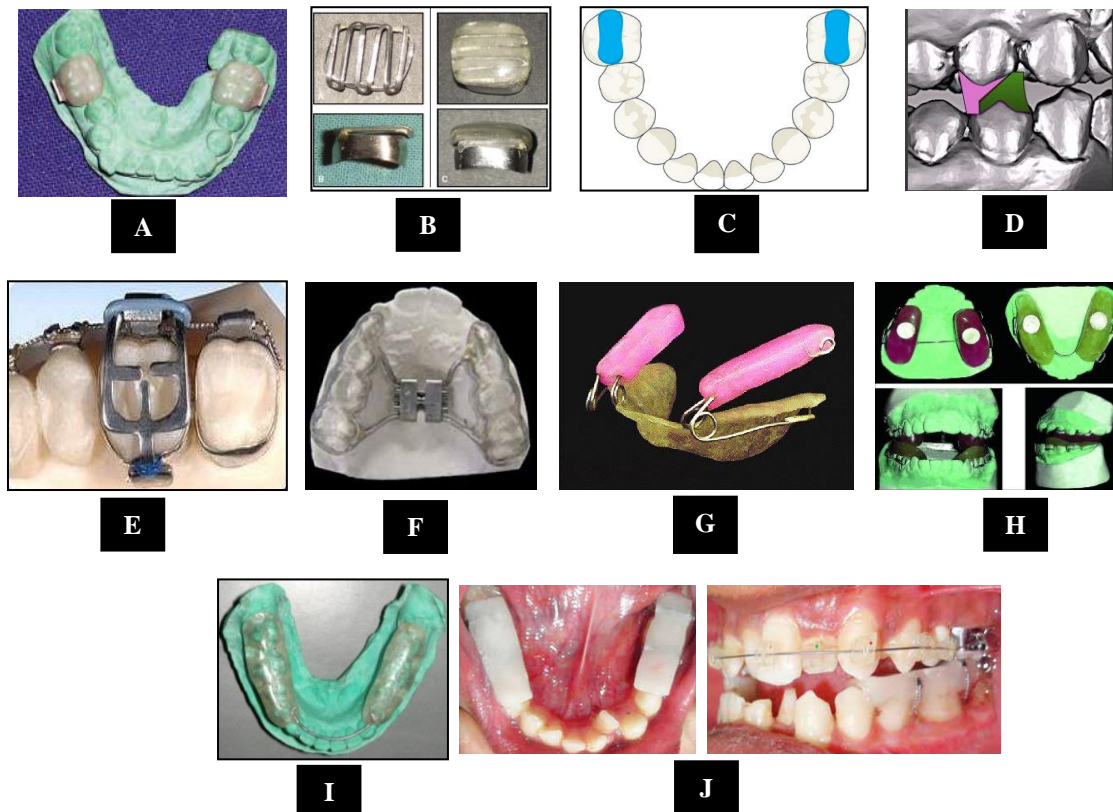


Figure 3: Posterior fixed bite raises

A: Temporary crowns bite raiser (Vibhute *et al.*, 2006), **B:** Nano Bite Plane (Prasad *et al.*, 2008), **C:** Posterior resin turbo (Kravitz *et al.*, 2018), **D:** Bonded inclined bite raisers (El-Bokle and Abbas, 2020), **E:** Güray bite raiser (Güray, 1999), **F:** Bonded posterior bite plane with expansion screw (Phulari, 2017), **G:** Spring Loaded Posterior Bite Blocks (Doshi and Bhad, 2012), **H:** Magnetic bite blocks (Dellinger, 1986), **I:** Bonded mandibular posterior bite plane (Sumathi, 2012), **J:** Two separate posterior bite plates (Ahmad *et al.*, 2014)

1.6.2.2. Removable Posterior Bite Raiser

A. Hawley Posterior Bite Plane

It is a removable posterior bite plane covering the occlusal surface of posterior teeth, hinging the mandible open by 3-4 mm approximately beyond its rest position (Figure 4).

They have the advantage in applying essentially vertical forces, thereby causing decrease in the posterior dentoalveolar height, relative extrusion of anterior teeth and mandible rotates upward and forward. This helps in correction of openbite. In cases of scissor bite, a ramp or inclined plane can be incorporated in the direction of desired tooth movement. Along with Z-spring or mid-palatal

jack screw, it is used in crossbite correction in removable appliance therapy (Singh, 2015; Phulari, 2017).

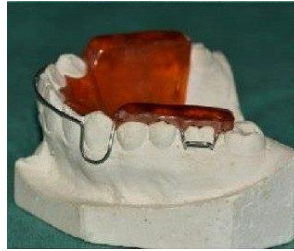

Figure 4: Hawley posterior bite plane

1.6.2.3. Semi-Fixed Posterior Bite Raiser

It is two pieces posterior bite blocks, comprised zig-zag loops of 2 mm width from 0.017×0.025 inch stainless steel wire covered by acrylic that extended from first premolars to first molars on both the sides. The distal end of the wire was inserted in either slot (main or auxiliary) with a 90 degrees bend (bends may be adjusted according to need) from the occlusal surface and another bend of 90 degrees at the level of the slot to be inserted (Figure 5). Wire can also be inserted from mesial side according to convenience (Sharma *et al.*, 2016).

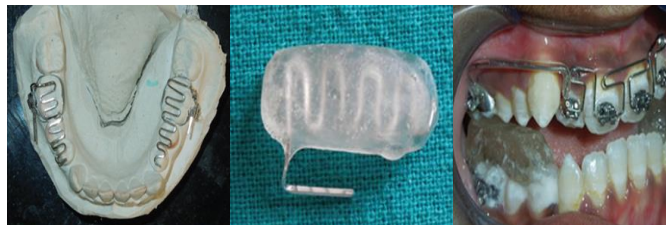

Figure 5: Semi-fixed posterior bite raiser

1.7. Advantages of Bite Turbos (Singh *et al.*, 2021)

1. Hygienic.
2. Required less chair side time.
3. Relatively comfortable as they minimize bulkiness.
4. Reduce interference with speech.
5. Less intrusive on the tongue space when compared to the conventional acrylic plates.

1.8. Disadvantages of Bite Turbos (Singh *et al.*, 2021)

1. Anterior teeth mobility and loss of vitality.
2. It may cause intrusion of posterior teeth leading to posterior open bite.
3. Wearing of the resin materials.
4. Breakage and debonding.

1.9. Disadvantages of Removable Bite Plane (Singh *et al.*, 2021)

1. Largely depended on patient cooperation
2. Required frequent adjustments to account for orthodontic tooth movements.
3. Easily lost or broken and sometimes swallowed by the patient as well.
4. They may also lead to the creation of plaque accumulation areas resulting in poor oral hygiene and high risk of dental caries.
5. Gagging due to over-extended bite plates.
6. It may cause ulcers in the oral cavity due to sharp ends.
7. Affect the speech.
8. Candidal infection.

1.10. Disadvantages of Bonded Bite Plane (Singh *et al.*, 2021)

1. Can cause soft-tissue irritation.
2. Contraindicated in mixed dentition with exfoliating deciduous teeth and the permanent teeth in various stages of eruption.
3. Not indicated in patients with a very short clinical crown height due to frequent dislodgement.
4. Not indicated in patients with poor oral hygiene.
5. Prevents early tooth movement (specially the mandibular one) as it cover the occlusal surfaces of posterior teeth.
6. Affect the speech.
7. Difficulty in eating.

1.11. Material Choices

The types of bite raiser according to materials from which are fabricated are shown in Figure 6.

Many materials have been proposed for bite raisers including acrylic resin, acrylic gels, band cements, bracket adhesives, and lingual retainer adhesives.

Each has advantages and disadvantages related to its color, placement and removal techniques, and glass filler content as shown in Table 1 (Kravitz *et al.*, 2018; Zafar 2020; Weissheimer *et al.*, 2020).

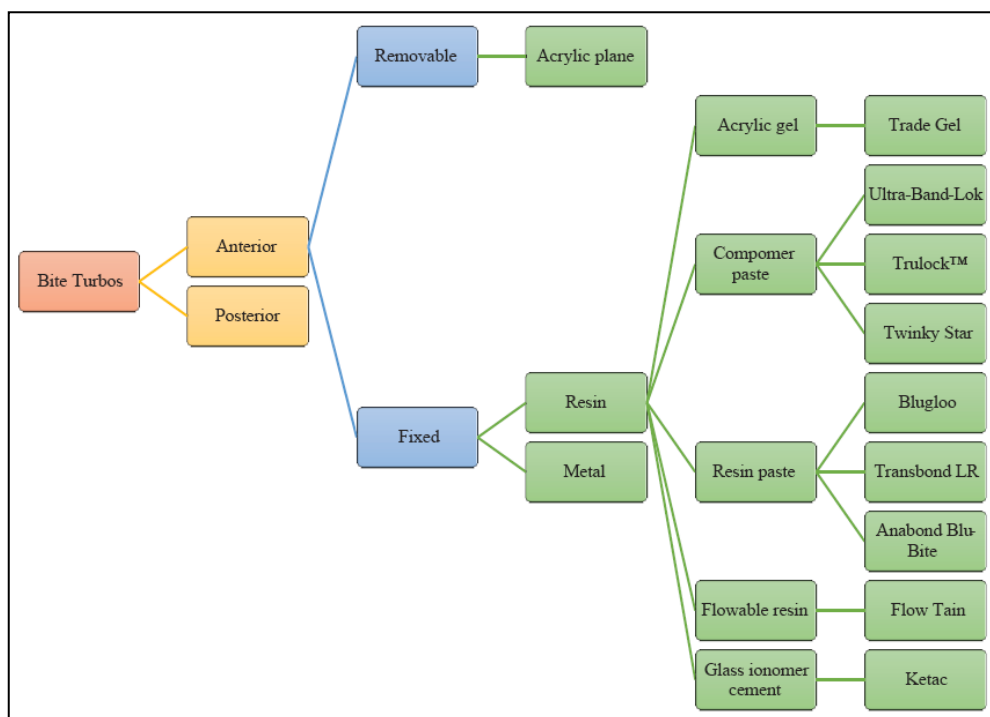


Figure 6: Types of bite raisers and their component materials

Table 1: Different materials used in fabricating bite raisers (Modified from Kravitz *et al.*, 2018)

| Products | Original Purposes | Type | Advantages | Disadvantages |
|---|---|--------------------------------------|--|---|
| Vulcanite | Denture base material, bite plate | Soft rubber sulfur compound | Cost-effective dimensionally stable, comfortable, low density, light weight, and is easily fabricated | Poor esthetics |
| Acrylic | Fabricating custom trays and provisional partial dentures, denture repair and bite plates | Cold-cured PMMA | Better dimensional stability and adaptation resulting in minor polymerization shrinkage | Low strength and hardness due to poor degree of polymerization, monomer leaching and inferior mechanical properties, and poor color stability and discoloration due to the oxidization of the amine initiators with time. |
| Triad Gel | Bite plates, cast modification | Acrylic gel | Soft, light color | Polymerization shrinkage, hyperemia |
| Ultra Band-Lok | Band cement | Compomer paste | Bonds to metal, distinct color | Casts a blue shade |
| TruLock Light Cure Band Adhesive | Band cement | Compomer paste | Bonds to metal, distinct color, fluoride releasing | Casts a blue shade |
| Ketac | Band cement, permanent restorations | Glass ionomer cement | Moisture insensitive, fluoride releasing | Difficult to remove |
| Blugloo, Greengloo | Bracket adhesive | Resin paste | Color change | Potential for wear |
| Transbond LR | Lingual retainer adhesive | Resin paste | Bond strength | Potential for wear |
| Flow Tain | Lingual retainer adhesive | Flowable resin | Easy application | Potential for wear |
| Twinky Star | Pediatric restorations | Compomer paste | Easy application, distinct color | Potential for wear |
| Fermit | Temporary inlay restorations | Composite resin with high elasticity | Easy application and removal, remain flexible after curing so it is accepted by patients, esthetic, compatible with both lingual and labial appliances | - |

An attempt to test some mechanical and physical properties of injectable polymer materials (namely M10 and Acrilato) acting as substitutes for cold cure acrylic was performed and the findings indicated that the good properties of these materials make them suitable alternatives to Orthocryl but the major issue is the cost and the availability of the required softening device in dental laboratories (**Albo Hassan *et al.*, 2019**).

On the other hand, two studies have been conducted to test the shear bond strength and the wear resistance of different adhesive materials used as a temporary bite raiser. In the first study three types of adhesive were tested namely Transbond XT, Light Cure Adhesive, Transbond Plus, Light Cure Band Adhesive, and Transbond Supreme LV, Low Viscosity Light Cure Adhesive from 3M Unitek and the findings showed that there was no statistically significant difference among their bond strength values. All of three materials can be used as temporary bite openers (**Kılınc and Sayar, 2018**).

In the second study, the wear resistance of Transbond LR (lingual retainer), Transbond Plus from 3M and Triadgel from Dentsply were tested and the findings showed that all bite turbo materials wore more than natural enamel but caused equal or less wear to opposing enamel than tooth-tooth contact. The bite turbo material used may be selected based on preference for longevity (**Feagin *et al.*, 2021**).

1.12. Application of Bite Raisers

Generally, bite planes made from acrylic are fabricated in the laboratory. Metal and tooth colored bite turbos are bonded directly on the palatal surface of the maxillary central incisors. On the other hand, resin bite turbos can be bonded on the teeth surface directly or by using special mini-molds (especially in the anterior region). Customized tray for indirect bonding has been used for more simplicity and accuracy (**Tong *et al.*, 2021**).

Alsheikho and Jomah (2021) described a simple, less expensive, and fast method of fabricating mini-molds with their holders utilizing the insulin injection syringe, bond brush holder, acrylic tooth, disc separator and at home silicone gun so that the desired length can be cut and used as a substitute for the ready made mini-mold.

1.13. Biomechanics

It helps the clinician to visualize the direction of expected tipping and plan the proper position thickness and length of the bite plane. It should be noted that the following effects of bite raisers are only applied when fixed orthodontic treatment i.e. brackets or wire are not bonded to the teeth. As the mechanics of bite raisers differs when used with fixed orthodontic treatment and has been briefly explained (**Singh *et al.*, 2021**);

1.13.1. Effect of bite plane on incisor inclination when anterior bite blocks are placed in patient's mouth

- a) When maxillary and mandibular incisors are almost upright the intrusive forces passes slightly labial to centre of resistance of mandibular incisor, while for maxillary incisor the intrusive forces passes through the centre of resistance. Therefore, there will be some amount of proclination of mandibular incisors only.
- b) When the maxillary incisors are upright and mandibular incisors are proclined the intrusive forces will pass lingually to centre of resistance of maxillary incisors and labial to centre of resistance of mandibular incisors, thus causing more retroclination of maxillary incisors and more proclination of mandibular incisors.
- c) When both maxillary and mandibular incisors are proclined, the intrusive forces will pass labially to centre of resistance of both maxillary and mandibular incisor, thus causing proclination of both segments (Figure 7).

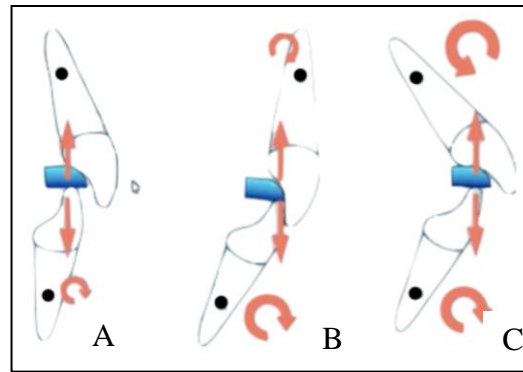


Figure 7: Effect of bite raiser on incisal inclination (Singh *et al.*, 2021)

1.13.2. Effect of bite plane on molar inclination when posterior bite blocks are placed in patient's mouth

- a) When force is directed onto the distal cusp of molar, which is distal to its centre of resistance. Therefore; it will result in distal tipping of that molar.
- b) Whereas if the molar is already mesially tipped, the force will be very slightly distal to its centre of resistance, so there will not be a big moment generated to correct the mesially tipped molar: Therefore the bite turbo is extended more distally so as to produce intrusive forces more distally to centre of resistance resulting in uprighting of mesially tipped molar (Figure 8).

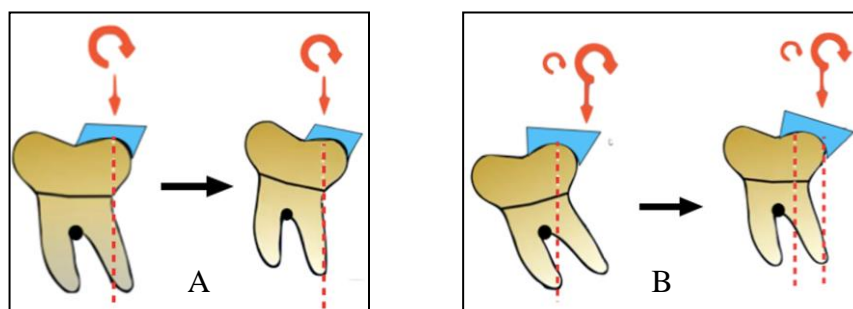


Figure 8: Effect of bite raiser on molar inclination (Singh *et al.*, 2021)

1.14. Effects of Bite Raisers on the Masticatory Functions and Electromyography

The effect of bite raisers on the masticatory functions and electromyography (EMG) activity have been studied in different researches. **Pativetpinyo *et al.* (2018)** studied the immediate effects of light-cured orthodontic band cement on

the superficial masseter and anterior temporalis EMG activity in healthy adults and found an altered neuromuscular behavior during clenching and chewing of these muscles. **Sankaranarayanan and Subramanian (2021)** reached to the same conclusions when used the light cured orthodontic band cement and the traditional acrylic bite plane.

Changsiripuna and Pativetpinyo (2020) evaluated the effect of light-cured orthodontic band cement on the masticatory function and found it will be immediately reduced, both objectively and subjectively yet it did not perceived by the individuals.

1.15. Effects of Bite Raisers on the Condylar Position

Only one study by **Herrera-Guardiola *et al.* (2020)** assessed the changes in the condylar position that occur three-months after treatment with posterior bite turbos. The findings indicated non-significant changes in condylar position during this period with well-tolerance by the patients.

1.16. Factors Influencing the Choice of Bite Raisers' Location

There are several factors affecting the choice of the bite raisers (**Kravitz *et al.*, 2018; El-Bokle and Abbas, 2020; Singh *et al.*, 2021**):

1. Facial type or the direction of mandibular growth

As dolicocephalic type tends to have backward mandibular rotation that needs molar intrusion, posterior bite raiser is required to intrude the molars and reduce the open bite. On the other hand, for the brachycephalic type, anterior bite raiser is required to open the bite posteriorly allowing extrusion of the premolars and molars also allowing the anterior teeth intrusion. For the mesocephalic, it can be placed on the premolars near the center of jaw rotation.

2. The Sagittal Jaw Relation

In case of class II relation, placing of inclined bite raiser on the premolars aid in advancing the mandible forward i.e. just like the action of twin block. On the other hand, in class III, it can be placed on the lower incisors either to open the

bite or to treat the negative overjet as the functional bite turbos can procline the upper incisors.

3. The amount of Overjet

With an increase overjet, inclined bite raiser can be placed on the premolars to reduce the amount of overjet. In cases of deep bite, the best location of the bite raiser is the maxillary central incisors but if the case is associated with increase overjet, it can be placed on the canine first and after marked overjet reduction, it can be placed on the central incisors.

4. Presence of Cross bite

With the presence of arch constriction and developing of cross bite and long face, expansion of the maxillary arch can be performed with bonded Hyrax.

1.17. Delivery of Removable Bite Raisers

At the time the bite raiser delivery, a number of things should be checked (Singh, 2015; Phulari, 2017):

1. Prior to placing the removable appliance, clinician should check for any minute pimples due to blow holes in the cast that could irritate the mucosa and the free edges should be rounded and smooth.
2. The base plate may need some trimming while fitting the appliance in the mouth.
3. Show the patient in a mirror how to insert and remove the appliance.
4. The bite plane is checked for occlusal wear or breakage due to masticatory forces. The clearance between the maxillary and mandibular anterior teeth is checked in cases where anterior cross bite has to be corrected so that sufficient space is available for the tooth in cross bite to jump the bite.
5. Bite adjustment must be done using articulating paper to ensure equal bite.

1.18. Instructions to the Patient

The success of any removable appliance is certain if the patient follows the instructions carefully (Singh, 2015; Phulari, 2017):

1. The patient and parent should be adequately counseled verbally and it should be reinforced with a written list of 'do's and don'ts'.
2. Patient should be instructed to wear the removable appliance for 24 hours a day and to remove the appliance only while brushing and also during contact sports and swimming.
3. A high standard of oral hygiene should be insisted upon to avoid the possibility of enamel decalcification or fungal infection.
4. The patient should be instructed to clean the appliance by brushing it with soap and water. Care should be taken while cleaning so as not to bend/distort any component.
5. The patient might encounter problems with speech due to encroachment of tongue space. This will settle down in about approximately one week.
6. Eating may be difficult for a few days after cementation as the upper teeth occludes on the acrylic platform of the mandibular bite plane. The patient will get accustomed to it with time.
7. In case of pain or appliance damage, patient must be told to report immediately to the clinic.
8. Patients should be instructed not to leave the appliance out of the mouth for a long period of time as it enhances chances of it getting damaged or distorted or bracket debonding might occur.
9. Care should also be taken to keep the appliance away from pet animals and children when the appliance is not being worn.

CHAPTER TWO

DISCUSSION/ COMMENTS

In general bite raisers are important part of treatment with Damon system as well as with conventional labial and lingual orthodontic appliances. The selection of the types, materials and locations are influenced by the experience, availability of the materials and the case itself (**Kravitz *et al.*, 2018**).

Some of the simple cases of anterior cross bite can be corrected easily within three months using functional anterior bite turbos placed on the mandibular incisors (**Kravitz, 2019**). This can be considered as a part of interceptive orthodontics aiming to prevent further problems associated with anterior cross bite.

One of the main strategies of treatment with Damon system is using light intermaxillary elastics from day one in conjunction with bite turbos. The role of these turbos is to disarticulate the teeth allowing easy and rapid movement and enhancing the effect of early use of elastics (**Pitts and Duncan, 2017**).

Developing new method for correcting the sagittal jaw relation using the bonded inclined bite raisers and elastics BIBRE is considered as a treatment of choice as these inclined bite raisers enforced the mandible to be in a forward position so that the correction of the sagittal discrepancy will be treated from day one without the need for completing the alignment stage (**El-Bokle, and Abbas, 2020**).

The choice of the materials used to fabricate the bite raiser other than of the acrylic is merely orthodontist's preference as there are metal and clear bite raisers which are ready made and bondable just like the brackets. On the other hand, posterior bite turbos are fabricated from different adhesive materials like flowable composite, band cements, and acrylic gel and here the availability and the applicability of the material is the major factor. Light cure band cements with different colors can be bonded and removed easily with low cost.

CHAPTER THREE

CONCLUSIONS AND SUGGESTIONS

3.1. Conclusions

1. Disarticulation is a valuable tool in orthodontic therapy.
2. Many methods of bite raising have been explained.
3. The choice of bite raiser depends on the case and patients cooperation.
4. Using bite raisers enhanced early bonding of lower anterior brackets and correction of deep bite and cross bite cases.
5. A good understanding of their action, methods of fabrication and uses are essential to avoid the iatrogenic effect.
6. The variability and availability of different materials enable orthodontists to choose the best material with fewer side effects.
7. Fixed bite turbos are preferred over the removable plane as patients' cooperation is ensured.

3.2. Suggestions for Further Studies

1. Further studies are needed to assess the shear bond strength of metal and tooth colored bite raisers.
2. More studies are required to evaluate the wearing effects of metal and tooth colored bite raisers in comparison with resin turbos.
3. Randomized clinical trial is needed to test the skeletal and dental effect of bonded inclined bite raisers elastics (BIBRE).

REFERENCES

A

- Ahmad, N., Ansari, A., Gera, A. and Kaur, G. (2014) A new method to retain the posterior bite blocks for anterior crossbite correction. *Journal of Indian Orthodontic Society*, 48(2), 139-140.
- Albo Hassan, A.F., Jameel, A., Nahidh, M. and Hamid, D. (2019) Evaluation of some mechanical and physical properties of different types of injectable polymer materials used as a base for removable orthodontic appliances. *Journal of Stomatology*, 72(5), 215-221.
- Alsheikho, H.O. and Jomah, D. (2021) A simple technique to fabricate bite turbos. *Journal of Indian Orthodontic Society*, 55(3), 331–335.
- Al-Zoubi, E.M. and Al-Nimri, K.S. (2022) A comparative study between the effect of reverse curve of Spee archwires and anterior bite turbos in the treatment of deep overbite cases: A randomized clinical trial. *Angle Orthodontist*, 92(1), 36–44.
- Angle, E.H. (1907) *Treatment of malocclusion of teeth*. 7th ed. Philadelphia: S.S White Dental manufacturing Co.

C

- Carano, A., Machata, W. and Siciliani, G. (2005) Noncompliant treatment of skeletal open bite. *American Journal of Orthodontics and Dentofacial Orthopedics*, 128(6), 781-786.
- Ceen, R.F. (2002) Bite opening with the Güray bite raiser. *Journal of Clinical Orthodontics*, 36(11), 639–40.
- Changsiripun, C. and Pativetpinyo, D. (2020) Masticatory function after bite-raising with light-cured orthodontic band cement in healthy adults. *Angle Orthodontist*, 90(2), 263–268.

- Cinsar, A., Algha, A.R. and Akyalçin, S. (2007) Skeletal open bite correction with rapid molar intruder appliance in growing individuals. *Angle Orthodontist*, 77(4), 632-639.

D

- Daskalogiannakis, J. (2000) *Glossary of orthodontic terms*. 1st ed. Berlin: Quintessence Publishing Co.
- Dellinger, E.L. (1986) A clinical assessment of the active vertical corrector-A nonsurgical alternative for skeletal open bite treatment. *American Journal Orthodontics*, 89(5), 428-436.
- Doshi, U.H. and Bhad, W.A. (2011) Spring-loaded bite-blocks for early correction of skeletal open bite associated with thumb sucking. *American Journal of Orthodontics and Dentofacial Orthopedics*, 140(1), 115-120.
- Doshi, U.H. and Bhad, W.A. (2012) Implant-supported bite blocks for open bite correction in adults. *Journal of Indian Orthodontic Society*, 46(2), 86-92.

E

- Elastomeric ligature with guard. 3M Unitek.
<https://www.orthodepot.de/ORTHO--OrthoDepot-/Elastomers/Elastic-ligatures/Elastomeric-Ligature-With-Guard-Ligature--3M-Unitek-.html?language=en> accessed in 20-4-2022
- El-Bokle, D. (2021) Posterior functional bite turbos for sagittal correction. *Journal of Clinical Orthodontics*, 55(7), 435-436.
- El-Bokle, D. and Abbas, N.H. (2020) A novel method for the treatment of Class II malocclusion. *American Journal of Orthodontics and Dentofacial Orthopedics*, 158(4), 599-611
- Emami, M.S., Jamilian, A. and Showkatbakhsh, A. (2007) The effect of anterior inclined plane treatment on the dentoskeletal of Class II division 1 patients. *Journal of Indian Society of Pedodontics and Preventive Dentistry*, 25(3), 130-132.

F

- Feagin, K., Kwon, S.J. and Farheen, F. (2021) In vitro comparison of wear of three orthodontic bite materials and opposing enamel. *International Orthodontics*, 19(3), 494-499.
- Fine, H.A. (1991) A fixed labial/lingual technique for rapid bite opening. *Journal of Clinical Orthodontics*, 25(10), 606-607.
- Fiorelli, G. and Melsen, B. (2013) Occlusion management in orthodontic anchorage control. *Journal of Clinical Orthodontics*, 47(3), 188-197.

G

- Gokalp, H. and Uslu, O. (2008) Treatment of class III anterior crossbite using Güray bite raisers. *Journal of Clinical Orthodontics*, 42(5), 297-300.
- Grieve, G.W. (1927) Buccal inclined planes, in conjunction with the pin appliance, for stimulation of growth of the mandible (clinic). *International Journal of Orthodontics, Oral Surgery and Radiography*, 13(10), 883-885.
- Güray, E. (1999) Temporary bite raiser. *Journal of Clinical Orthodontics*, 33(4), 206-208.

H

- Herrera-Guardiola, S., Puerta-Salazar, G.E., and Martínez Cajas, C.H. (2020) Condylar position changes after three months of treatment with posterior bite turbo. *Rev Fac Odontol Univ Antioq*, 32(1), 18-25.

K

- Kılınç, D.D. and Sayar, G. (2018) Comparison of shear bond strength of three different adhesives used as temporary bite raiser in daily orthodontic practice. *International Orthodontics*, 16(3), 440-449.
- Kingsley, N.W. (1892) Adenoid growths, mouth breathing and thumb sucking in their relation to deformities of the jaws and irregular teeth. *Dental Cosmos*, 34(1), 16-22.
- Kravitz, N. (2019) Interceptive orthodontics with resin turbos for pseudo-class III malocclusions. *Case Reports in Dentistry*, 2019, Article ID 1909063.

- Kravitz, N., Jorgensen, G., Frey, S. and Cope, J. (2018) Resin bite turbos. *Journal of Clinical Orthodontics*, 52(9), 456-461.

M

- Mayes, J.H. (1997) Bite turbos: New levels of bite-opening acceleration. *Clinical Impression*, 6(1), 15-17.

O

- Orthotechnology product catalogue 2022. <https://www.orthotechnology.com> › 2022/02.

P

- Pativetpinyo, D., Supronsinchai, W. and Changsiripun, C. (2018) Immediate effects of temporary bite-raising with light-cured orthodontic band cement on the electromyographic response of masticatory muscles. *Journal of Applied Oral Sciences*, 26, e20170214.
- Philippe, J. (1996) Treatment of deep bite with bonded biteplanes. *Journal of Clinical Orthodontics*, 30(7), 396-400.
- Phulari, B.S. (2017) *Orthodontics Principles and Practice*. 2nd ed. New Delhi: Jaypee Brothers Medical Publishers (P) Ltd.
- Pitts, T. and Duncan, B. (2017) I.L.S.E. Immediate, Light, Short, Elastics with Disarticulation. *Protocol*, 6, 8-16.
- Prakash, A., Chaturvedi, N., Balani, R. and Bharti, C. (2018) Button bite turbo. *Journal of Indian Orthodontic Society*, 52(3), 217-218.
- Prasad, V., Sharma, V.P., Tandon, P. and Singh, GP. (2008) A New fixed biteplane. *Journal of Clinical Orthodontics*, 42(11), 661-662.
- Pratiwi, D. and Purwanegara, M.K. (2020) Deep bite correction with an anterior bite plate in a growing patient. *Scientific Dental Journal*, 4(3), 129-133.

R

- Roy, A.S., Singh, G.K., Tandon, P. and De, N. (2013) An interim bite raiser. *International Journal of Orthodontics Milwaukee*, 24(2), 63-64.

S

- Sankaranarayanan, R.R. and Subramanian, A.K. (2021) Effect of temporary bite raising with light cured orthodontic band cement and acrylic bite plane on the electromyographic response of masticatory muscles. *Annual of Dental and Oral Health*, 4(1), 1036.
- Sharma, V.K., Yadav, K., Shastri, D. and Chaturvedi, TP. (2016) An efficient semi-fixed bite raiser. *Journal of Indian Orthodontic Society*, 50(3), 194-195.
- Singh, G. (2015) *Textbook of orthodontics*. 3rd ed. New Delhi: Jaypee Hights Medical Pub Inc.
- Singh, G., Gupta, H., Rathi, A, et al. (2021) The use of bite raisers in orthodontic treatment –A review of literature. *Acta Scientific Dental Sciences*, 5(4), 219-228.
- Speed Dental product catalogue. <https://www.dentalspeed.com/catalogos/catalogo-de-produtos>.accessed in 20-4-2022.
- Suggett, A.H. (1915) Some uses of the inclined plane. *International Journal of Orthodontics*, 1(5), 243-246.
- Sumathi, F.A. (2012) Bonded mandibular posterior bite plane: Fabrication, insertion and uses. *Tanazaia Dental Journal*, 17(2), 56-60.
- Sved, A. (1944) Changing the occlusal level and a new method of retention. *American Journal of Orthodontics*, 30(10), 527-535.

T

- Tiwari, N., Tiwari, S. and Sharma, D. (2020) Management of anterior cross bite in mixed dentition using Catlan's appliance. *Acta Scientific Dental Sciences*, 4(2), 106-109.
- Tong, H., Lee, R. and Weissheimer, A. (2020) Indirect bonding trays with bite turbo and orthodontic auxiliary integration. US Patent No. 2020/0275996 A1. Swift Health Systems Inc.

V

- Vibhute, P.J., Srivastava, S. and Hazarey, PV. (2006) Temporary bite-raising crowns. *Journal of Clinical Orthodontics*, 40(4), 224-230.
- Voudouris, J.C., Gaveglia, V., Poulos, J.J. BiTurbo2 (BT2) system for rapid deep overbite correction. DW Journal. <https://dentalworld.hu/biturbo2-bt2-system-for-rapid-deep-overbite-correction/> accessed in 20-4-2022.

W

- Weinberger, B.W. (1926) *Orthodontics; a historical review of its origin and evolution, including an extensive bibliography of orthodontic literature up to the time of specialization*. St. Louis: The C.V. Mosby.
- Weissheimer, A., Lee, R., Tong, H. and Pham, J. (2020) Flexible bite turbos for lingual appliances. *Journal of Clinical Orthodontics*, 54(10), 631-632.
- Woodside, D.G. and Linder-Aronson, S. (1986) Progressive increase in lower anterior face height and the use of posterior occlusal bite-block in its management, In: Graber, L.W. (ed.), *Orthodontics: State of the Art, Essence of the Science*. St Louis: CV Mosby Co. pp. 200-221.

Z

- Zafar, M.S. (2020) Prosthodontic applications of Polymethyl Methacrylate (PMMA): An Update. *Polymers*, 12, 2299.