Republic of Iraq
Ministry of Higher Education
and Scientific Research
University of Baghdad
College of Dentistry

The Effect of Orthodontic Force on Dental Pulp

A Project submitted to
The college of Dentistry, University of Baghdad,Department of Orthodontics, in partial Fulfillment for the Bachelor of Dental Surgery

By:
Teba Hashim Abd Almuhsin

Supervised by:
Assist. Prof. Dr. Shaymaa Shaker Taha

B.D.S, M.Sc. Orthodontics

May,2023

بسم الله الرحمن الرحيم

فَدَعَا رَبَّهُ

أَنِّي مَغْلُوبٌ

فَانتَصِرْ

صَدَقَ اللهُ العَظِيمُ

Certification of the Supervisor

I certify that this project entitled “ The Effect of Orthodontic force on dental pulp” was prepared by fifth-year student Teba Hashim Abd Almuhsin under my supervision at the College of Dentistry/ University of Baghdad in partial fulfillment of the graduation requirements for the Bachelor degree in Dentistry.

Supervisor’s name:

Assist. Prof.

Dr. Shaymaa Shaker Taha

May,2023

Dedication

To the center of my life, the reason for my existence, my eternal love, to **my God**.

My strength, my support, my reason for being in this place after God to **my father**.

To my beloved, dispersing my anxiety, believing in me and supportive of my steps, to **my mother**.

To all my **brothers** and **loved ones** who support me.

Finally, I dedicate this success to rewarding **myself** and thanking her for being patient and determined despite all the difficulties.

# Acknowledgment

First of all I would like to present my thanks to “**Allah**” for everything.

I would like to thank **Prof. Dr. Raghad Al- Hashimi**, Dean of my college of Dentistry, university of Baghdad, for supporting the students.

Grateful thanks are expressed to **Prof. Dr. Dheaa Hussein** the head of the Department of Orthodontic Dentistry, for this scientific support and encouragement.

My deep thanks to my supervisor **Assist. Prof. Dr. Shaymaa Shaker Taha** for her unlimited cooperation, encourage and advise me always to right way throughout this research.

Table of contents

List of figures

List of Abbreviations

Abbreviations	Meanings
PDL	Periodontal ligament
SP	Substance P
PGE2	Prostaglandin E2
RANKL	Receptor Activation of Nuclear Factor Kappa-B Ligand
IL-1β	Interleukins 1β
IL-6	Interleukins-6
TNF-a	Tumor necrosis factor alpha
CGRP	Calcitonin gene-related peptide
NKA	Neurokinin A
GP	Gutta-Percha
Gm/g	Gram
Sq	Square
Cm	Centimeter
%	Percentage

Introduction

Orthodontics is a field of dentistry that corrects the malposition of the jaw bones and teeth in order to optimize occlusion for functional and aesthetic purposes **(Alves *et al*., 2013)**.

Orthodontic forces are often followed by the biological response of dental pulp. The pulp's sensory role is important, but it has other roles as well **(Bicakci *et al*., 2010)**.

The pulp functions to formation and nutrition of the dentin, as well as the innervation and defense of the tooth. When the nerve tissue is damaged, often bacteria begin to multiply in the pulp chamber, leading to infection. In fact, dental pulp maintains the biological and physiological vitality of the dentin **(Abbassy *et al*., 2015)**.

In addition, it has a highly responsive sensory nervous system that generates unbearable pain when the tooth is inflicted by mechanical trauma. Considering that, dental pulp insures many vital functions; it is legitimate to seek answers for the relationship between pulpal health safety and orthodontic forces.Rarely, pulpal side effects may appear during an orthodontic treatment. They involve pulpal necrosis and pulpal obliteration by secondary dentin. Pulpal oxygenation rates and blood flow are reduced in the early stages of the application of orthodontic forces **(Lazzaretti *et al*., 2014)**.

The relation between orthodontic force application and dental pulp tissue has been the subject of studies in the recent years. However, there is no conclusive evidence on the effect of orthodontic forces on pulpal tissue, and therefore, the issue has been studied for many years in human **(Andreasen and Andreasen**, **2007**).

Proffit *et al*., (2007) reported that light continuous forces have little or no effect on dental pulp.

On the other hand, the reaction of dental pulp to orthodontic forces has been reported to vary from mild hyperemia to complete necrosis in the literature.Type of the force application, duration and dimension of the force, age of the patients, and size of the apical foramen are among the contributory factors.More pulpal changes have been observed in response to intrusive orthodontic force. Furthermore, higher incidence of irreversible pulpal reactions is usually expected in teeth with complete root formation **(Ersahan and Sabuncuoglu, 2015).**

Aims of the study

To review the influence of orthodontic force on human dental pulp.

Chapter one

Review of literature

1.1 Pulp Structure

The pulp mass is a highly vascularized and innervated mass of connective tissue that resides within a spaced called the pulp chamber. Various cell types characterize this tissue, including fibroblasts, odontoblasts, histiocytes, macrophages, mast cells, and plasma cells. It also contains an extracellular matrix composed of collagenous fibers and ground substance. Given that the pulp forms the layer of dentin evenly in every direction, it effectively shapes itself into miniaturization of the tooth and reflects the external form of the enamel **(Yu and Abbott, 2007)**.

There are two main regions of pulpal architecture:

1) central.
2) peripheral.

On the periphery of the pulp, the area adjacent to the calcified dentin exists a series of different structural layers. At the interface of the dentin-pulp complex exists a layer of columnar odontoblast cells, whose primary function is the development of dentin. Here, many dentinal tubules, channels created by the odontoblasts, extend through the dentin from the pulp to the enamel border **(Yoshida and Ohshima, 1996)**.

Each one of these tubules contains an odontoblast process, a cellular extension of an odontoblast used to form the dentin, as well as dentinal fluid. Like enamel, dentin is avascular, and these tubules are crucial for providing an entryway for nutrients in the interstitial fluid that originated from capillaries in the pulp. Beneath the odontoblastic layer is the cell-free zone, or zone of Weil, an area rich in both capillaries and nerve networks. The peripheral compartment closest to the central zone is the cell-rich zone, a layer rich in fibroblasts and undifferentiated mesenchymal cell that functions in supporting the population of odontoblasts by proliferation and differentiation. This cell layer can also differentiate into fibroblasts and macrophages. The central pulp zone's perimeter is outlined by the edge of the cell-rich layer. This body of tissue is the main support system for the peripheral region and contains large vessels and nerves that extend out into the periphery. Similar to the cell-rich zones, it also contains many fibroblasts **(Shi and Gronthos, 2003)**.

1.2 Orthodontic tooth movement

The orthodontic tooth movement could be defined as the results of tooth biological system response to the application of an externally force, all the biological responses that take place after force application lead to bone remodeling that is necessary for orthodontic tooth movement **(Anastasi *et al*., 2008; Militi *et al*., 2019)**.

The size of the biological response depends on the application time, force magnitude and force distribution. in fact, different force distribution patterns could determine different type of tissue reactions. By that, several studies focused on evaluating tissue reaction to force appliance and iatrogenic sequelae to orthodontic force have been detected **(Cutroneo *et al*., 2015)**.

The prolonged force appliance could determine dental pulp alterations that may culminate in a loss of vitality due to pulpal blood flow alterations **(Abtahi *et al*., 2016)**. The characteristics of applied orthodontic forces, such as magnitude, appliance time and distribution, could contribute to blood flow disturbance and make the alteration reversibly or irreversibly **(Lazzaretti *et al*., 2014)**.

The literature shows conflicting results about the correlations of pulp changes incident to orthodontic force. Some reports suggested permanent damage to pulpal tissue from orthodontic force as tissue calcification and vascular alteration with vascular stasis and pulp necrosis but others supported no significant long-lasting effects of dental pulp **(Tripuwabhrut *et al*., 2010)**.

There are many theories proposed regarding orthodontic tooth movement.

The pressure-tension theory proposed by Schwartz in 1932 is the simplest theory describing tooth movement on mechanical loading.On the pressure side, the biological events are as follows: disturbance of blood flow in the compressed PDL, cell death in the compressed area of the PDL (hyalinization), resorption of the hyalinized tissue by macrophages, and undermining bone resorption by osteoclasts beside the hyalinized tissue, which ultimately results in tooth movement. On the tension side, blood flow is activated where the PDL is stretched, which promote osteoblastic activity and osteoid deposition, which later mineralizes **(Von and Kuijpers, 2009).**

The fluid flow hypothesis, describing a mechanism by which osteocytes respond to mechanical forces, states that locally evoked strain derived from the displacement of fluid in the canaliculi is very important **(Goulet *et al*., 2008)**.

When loading occurs, interstitial fluid is squeezed through the thin layer of the non-mineralized matrix surrounding the cell bodies and cell processes, resulting in local strain at the cell membrane and activation of the affected osteocytes **(Weinbaum *et al*., 1994)**.

According to piezoelectric theory, there is production of piezoelectric signal on application of orthodontic force, which quickly reduces to zero. On removal of the mechanical force, the piezoelectric signal is again produced, but in the opposite direction. The possible sources of this electric current could be collagen, hydroxyapatite, or the mucopolysaccharide fraction of the ground substance.On application of orthodontic force, the alveolar bone adjacent to the tooth bends and the area of concavity accumulates negative charges, resulting in bone deposition. Areas of convexity are associated with positive charges, resulting in bone resorption. These currents are affected by the nature of the fluid present within the canaliculi. The small voltages thus generated are called “Streaming Potentials” **(Sandy *et al*., 1993)**.

Recently,t has been proposed that the pressure-tension theory is not simple and might involve more complicated biological tissue response, suggesting that bone apposition could be induced by

(1) the load exerted by stretched fibers of the PDL, which may also induce a slight bending of the alveolar wall.

(2) direct resorption by unloading of the alveolar wall in the case of low forces.

(3) indirect resorption as repair due to ischemia following the application of high forces **(Melsen, 2001)**.

1.3 Orthodontic Forces

Orthodontic forces represent a major inducing factor for tooth movement. Such forces are produced by orthodontic appliances and exert on the tooth crown, with the forces transferring to surrounding periodontal tissues through the tooth body, triggering tissue remodeling after cushioning and absorbtion by the periodontal ligament (PDL) **(Kim *et al*., 2010; Lombardo *et al*., 2012)**.

The magnitude of the forces is crucial, where oversized forces may lead to root resorption, or even tooth exfoliation in the worst case scenario **(Hohmann *et al*., 2007; Rohan *et al*., 2015)**.

In addition, orthodontic treatment is almost irreversible, and it is hard to repair failed cases. As a result, serious adverse effects can result from treatment failure. On the other hand, if the forces are too small, the tooth will not move or move at a speed that is too low, extending the treatment period. The willingness and enthusiasm of the patient would likely be reduced at the same time, complicating the effort to realize an ideal orthodontic treatment **(Liao *et al*., 2016).**

1.3.1 TYPES OF ORTHODONTIC FORCES (Phulari, 2011)

Based on the duration of application, force can be divided into the following three types:

1. Continuous force.
2. Intermittent force.
3. Interrupted force

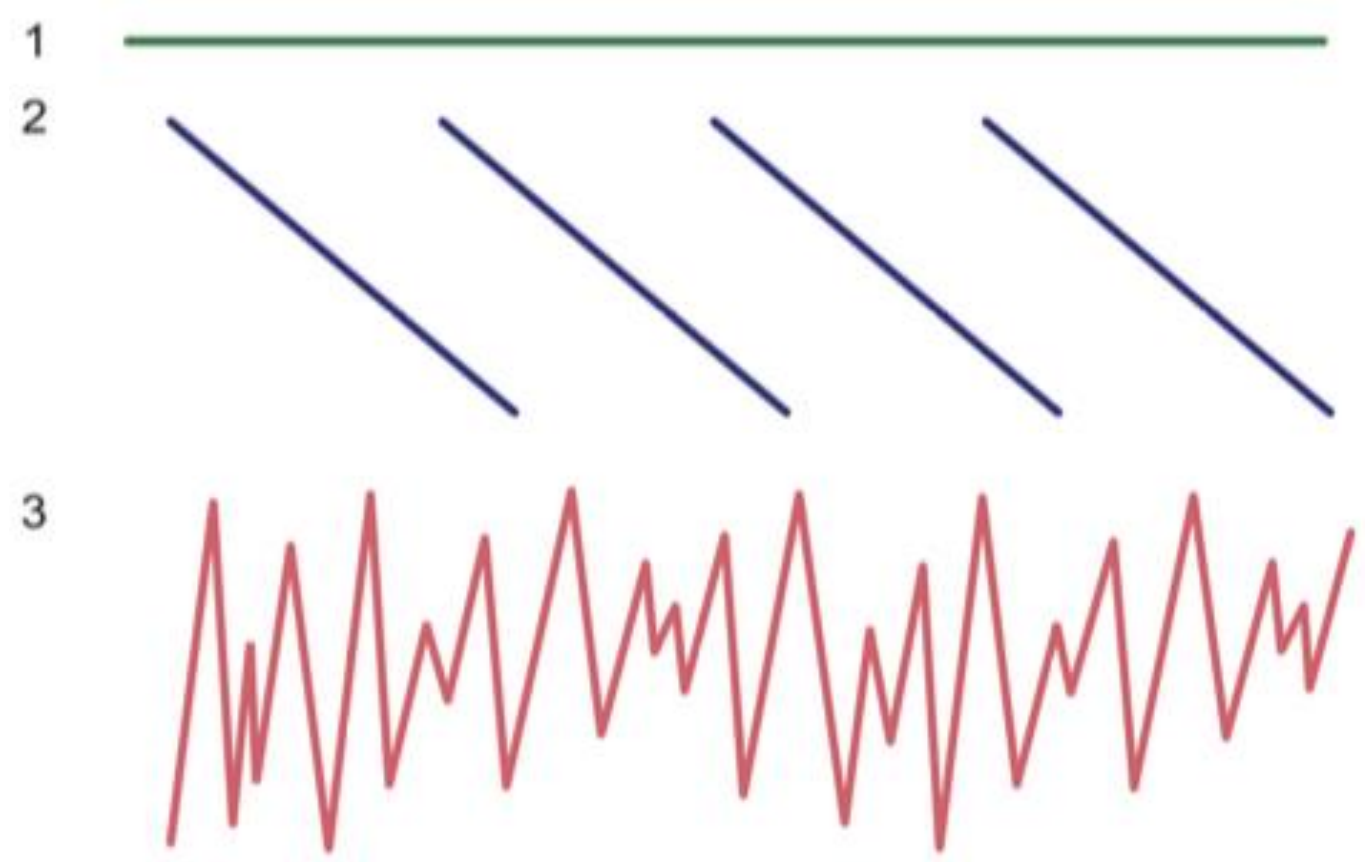

Figure 1.1: Types of orthodontic forces **(Phulari, 2011).**

1.3.2 Continuous Force: (phulari, 2011).

• A continuous force is the one, whose magnitude does not decrease appreciably over time. The force decay is minimal between visits to the clinician.

• Ideally, light and continuous forces are most efficient as they bring about tooth movement mainly by frontal resorption.

•For example, flexible wires and light elastics used in light-wire differential force technique produce continuous forces.

1.3.3 Intermittent Force: (phulari, 2011).

• The force is said to be intermittent when it decays to zero or nearly zero magnitude prior to the next appointment.

•For example, removable appliance with an expansion screw.

•Usually, such intermittent forces are of high magnitude and cause undermining resorption while moving the tooth

•Force will decay to near zero magnitude once the tooth has moved and allows resumption of blood supply in the periodontal ligament tissue.

1.3.4 Interrupted Force: (phulari, 2011).

• Forces applied on the teeth get interrupted when the appliance is inactive (when removed from oral cavity) for an interval of time in a day by the patient

• For example, force exerted by headgears or facemask worn for a particular duration everyday

• Appliances using interrupted forces use forces of heavy magnitude, which do not decrease. Usually such appliances exhibit, long-term specific magnitude-time pattern, for example 200-300 gm of force 14 hours a day to bring about skeletal changes

• Although it appears logical to think that, continuous forces cause continuous tooth movement and an increased amount of tooth movement can be achieved by an increased amount of force, it is not true in reality

• This is because, tooth movement is the combined result of several complex biologic changes occurring in the periodontal tissues at cellular level; which are not completely understood yet.

1.4 Optimum orthodontic force (Iyyer, 2012)

Optimum orthodontic force is one, which moves teeth most rapidly in the desired direction, with the least possible damage to tissue and with minimum patient discomfort. Oppenheim and Schwarz following extensive studies stated that the optimum force is equivalent to the capillary pulse pressure, which is 20-26 gm/ sq. cm of root surface area. From a clinical point of view, optimum orthodontic force has the following characteristics:

a. Produces rapid tooth movement.

b. Minimal patient discomfort.

c. The lag phase of tooth movement is minimal.

d. No marked mobility of the teeth being moved.

From a histologic point of view the use of optimum orthodontic force has the following characteristics:

a. The vitality of the tooth and supporting periodontal ligament is maintained.

b. Initiates maximum cellular response.

c.Produces direct or frontal resorption.

1.5 Pulpal Changes During Application of Orthodontic Forces

The impact of orthodontic forces on the dental pulp tissue has become a matter of interest **(Javed *et al*., 2015)**.

Several studies have evaluated the impact of orthodontic forces on the dental pulp. However, the reported results in the literature are inconsistent and inconclusive, mostly due to the methodological limitations **(Leavitt *et al*., 2002)**.

Some studies have reported short term effects such as changes in tissue respiration, and others have reported long lasting consequences such as necrosis **(Nixon *et al*.,1993)**.

1.5.1 Morphological changes

A wide variety of morphological changes occurring in response to orthodontic force application have been documented throughout the literature, affecting both the inner and outer layers of the pulpal tissue. The majority of these are deleterious in nature, with vacuolization and degeneration of the odontoblast layer being a commonly observed occurrence **(Ramazanzadeh *et al.*, 2009; Villa *et al*., 2005)**.

This degeneration may, however, be compensated for by osteopontin release which stimulates differentiation of new odontoblasts, thereby helping to repair any tissue damage **(Shigehara *et al*.,2006)** .

These deleterious changes appear to be more marked in older patients, possibly due to a reduction in the size of the apical foramen, with concurrent constriction of apical vessels. Younger patients (the most common orthodontic patient cohort) may, therefore, be at less risk. A change in the width of the pre-dentine layer has also been documented as a response to orthodontic force application, however this shows considerable inter-species variation. Whether the pre-dentine width reduces, increases **(Villa *et al*., 2005)** or remains unchanged **(Kayhan *et al*., 2000)** in the human model, however, remains unclear.

Within the core of the pulpal tissue blood vessel congestion and haemorrhage have been observed in human teeth subject to heavy (150gm), intrusive forces, together with an increase in collagen fibre number and width, giving rise to some fibrosis **(Villa *et al*.,2005).**

The extent of fibrosis appears to be proportional to length of time for which force is applied **(Kayhan *et al*., 2000)**.

Very rarely, total obliteration of the pulp space may be observed, with concurrent loss of vitality; this is, however, most likely to occur in teeth that have experienced previous trauma **(Bauss *et al*., 2008)**.

Neuronal changes in the human, there would appear to be minimal effects (both in the long and short-term) on the nerve fibres, as demonstrated clinically, by a continued normal response to thermal stimulation **(Hall and Freer 1998)**.

1.5.2 Angiogenic changes

It has been proposed that, in order to avoid undermining bone resorption, the ideal force for tooth movement be in the order of to 35-60g for tipping movements and 70-120g for bodily movement **(Proffit *et al*. 2007)**.

The effects of these forces upon the pulpal blood supply are contentious, but several studies have found that under these ‘ideal’ conditions, orthodontic forces bring about an initial reduction in vascular flow to the pulp that lasts for approximately 30 minutes, with a corresponding reduction in pulpal respiration rates. Clinically 72 hours after orthodontic force application has commenced normalisation of the blood supply occurs. this corroborating the fact that the pulp acclimatises to force application. However if excessive force is applied the blood flow may not recover, and the resulting ischaemia will lead to tissue necrosis **(Sano *et al*., 2002)**.

1.5.3 Inflammatory changes

As with the documented changes in vascularity, there is discord within the literature as to whether or not orthodontic force application brings about inflammatory pulpal changes. Studies vary from showing no significant inflammatory changes **(Sübay *et al*., 2001)** to some evidence of macrophage infiltration **(Grünheid *et al*., 2007)**, through to possible pulpal injury associated with rapid tooth movement **(Seltzer, 2002)**.

Any inflammatory reaction is likely, in part, to be mediated by fibroblasts. In vitro, substance P, which is known to be present in the human dental pulp, has been shown to stimulate the production of Prostaglandin E2 (PGE2) and Receptor Activator of Nuclear Factor Kappa-B Ligand (RANKL) by cultured dental pulp fibroblasts **(Kojima *et al*., 2006)**.

These then have been shown to produce large amounts of Interleukins (IL): IL-1β, IL-6, and TNF-α **(Yamaguchi *et al*., 2004)** when under cyclic strain **(Lee *et al*., 2008)**.

Orthodontic force application does bring about strain within the pulp tissue, together with upregulation of fibroblast growth factors, and so it could, in theory, give rise to cytokine production by fibroblasts **(Grünheid *et al*., 2007).**

1.5.4 Cellular changes

Changes in cell metabolism take place, followed by tissue degeneration and remodelling. The most significant changes occur in the mid and apical regions of the pulp and increase in a time dependent manner **(Grünheid *et al*., 2007)**.

The odontoblast layer forms the outermost layer of the pulpal organ, and plays an important role in the functional regulation of the pulp. If the pulp of a tooth is exposed, resulting in injury to the odontoblast layer, pulpal cell proliferation may be seen, along with pulpal stromal/mesenchymal differentiation into odontoblast-like cells, thereby allowing formation of new dentine matrix **(Fitzgerald *et al*., 1990)**.

This a process known as reparative dentinogenesis, where, in response to noxious stimuli, newly differentiated odontoblast-like cells lay down tertiary dentine matrix in the area local to the site of injury at an accelerated rate **(Smith *et al*., 1995)**.

If the stimulus is relatively mild (e.g. if a tooth is worn down gradually) pre-existing odontoblasts may lay down new matrix- this is known as reactionary dentinogenesis **(Lesot *et al*., 1994).**

The compositions of the tertiary dentine formed vary between the two processes, suggesting that the activity of the odontoblast/odontoblast-like cells is modulated accordingly. It has been shown that odontoblasts will transmit external stimuli to the pulpal cell layer beneath them, indeed they are ideally situated to enable them to act as receptors to stimuli external to the tooth, due to the localization of their processes within the dentinal tubules **(Ikeda and Suda, 2006)**.

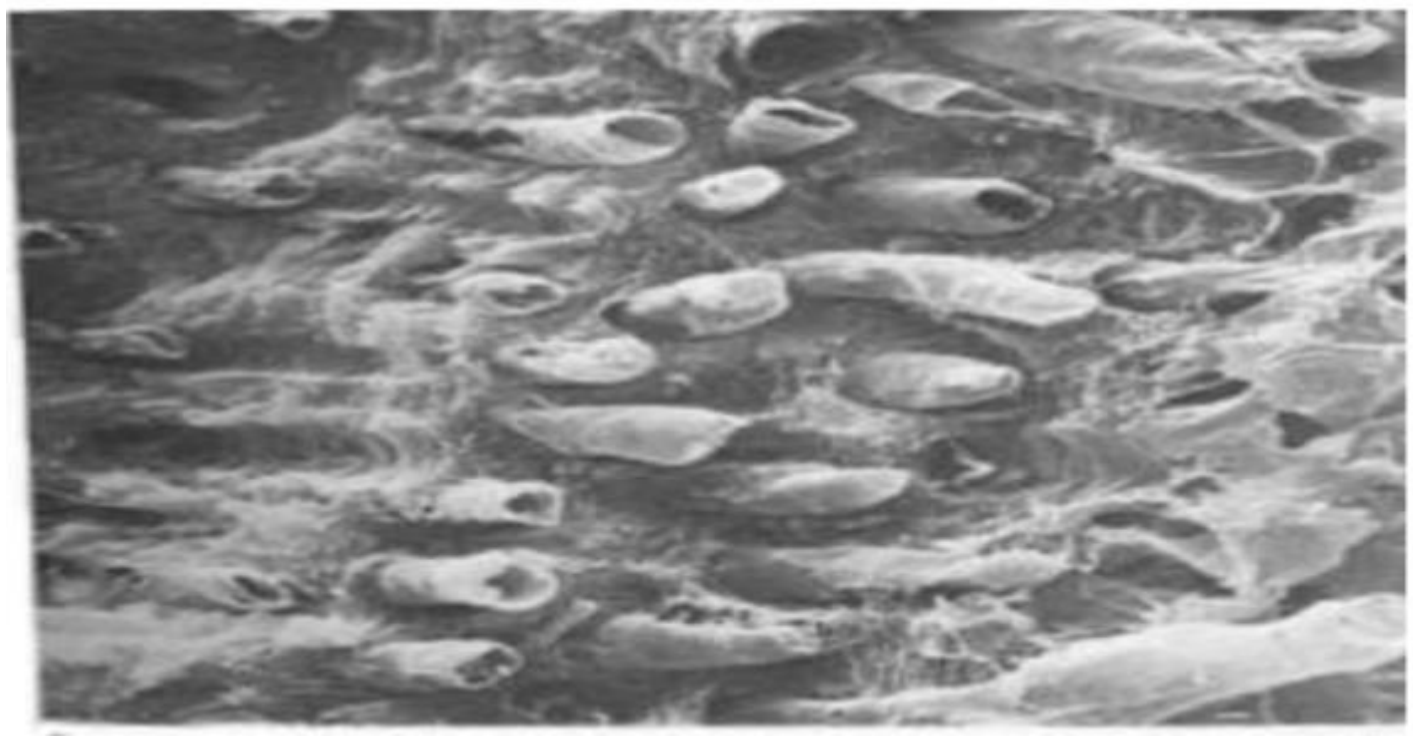

Figure 1.2: Dentine/pulp interface **(Brannstrom *et al*., 1972).**

1.5.5 Pulp Reactions

Application of orthodontic forces to teeth will induce molecular changes on the cells within the periodontium. The peripheral sensory nerve system contributes to the development of acute and chronic inflammatory processes through local release of neuropeptides. When orthodontic appliance is activated, the transient inflammatory response may cause discomfort to patient for few days. The response initiates from acute inflammatory, which includes vasodilatation and leukocyte migration in the PDL **(Krishnan *et al*., 2009)** .

The migratory cells will produce various local biochemical signal molecules and cytokines. After 24 to 48 hours of the force application, chronic inflammation follows and this involves fibroblasts, osteoblasts, endothelial cells, and alveolar bone marrow cells during the process. The leukocytes continue to migrate to periodontal tissues and keep modulating the remodeling process **(Krishnan *et al*., 2006)**.

Interestingly, there is no conclusive evidence on the relation between orthodontic force and pulp tissue in human **(Von *et al*.,2012)**.

Proffit *et al*. (2013) has stated that light continuous force has an impact on the PDL but has little or no effect on the pulp. However, pulp necrosis may occasionally be found during orthodontic treatment. This is usually related to previous dental trauma including severe periodontal injury, large decay, exceeding orthodontic force or dental movement outside the trough of the alveolar process etc. These scenarios may block blood supply entering the chamber of tooth. reported that excessive intrusive/extrusive force magnitude may disturb the circulation of dental pulp and degenerate the odontoblastic layer. These factors will potentially result in pulpal necrosis.

In adolescences, the prevalence of dental pulp damage resulted from orthodontic treatment was about 2%-17% for canal obliteration and 1%-14% for pulpal necrosis. Changes occurred in the pulp are considered to be reversible most of the time unless the pulp had previous damage. The degree of pulpal change may be influenced by the severity of previous violation to the pulp. Sometimes, the pulp tissue health was compromised before the application of orthodontic force. We should be very cautious of moving this type of tooth and monitoring the pulpal status throughout the whole orthodontic treatment period. Although there are very few reports on the loss of tooth vitality related to excessive orthodontic force, it is still assumed that larger orthodontic force may potentially cause pulpal changes and the consequences is much more severe **(Hamilton and Gutmann, 1999)**.

1.6 Orthodontic force and movement in endodontically treated teeth

In some situations, orthodontic force may apply on teeth having had or being under endodontic treatment.

Before moving these teeth, we must evaluate the conditions of tissue repair and the degree of inflammation. According to previous studies, if root canals are cleaned, shaped, and sealed properly, teeth can be moved in the same way as teeth with normal pulps **(Derringer and Linden , 2007)**.

Complete and intake PDL on the radiograph is another sign of success **(Proffit *et al*., 2013)**.

Interestingly, several studies have shown that teeth with well endodontic treatment may have less tendencies of root resorption or remodeling than vital teeth may have during orthodontic tooth movement.

The main theory is that the absence of pulp tissue will result in the less production of neuropeptides, such as substance P (SP), calcitonin gene-related peptide (CGRP), neurokinin A (NKA)etc., which are related to the metabolisms of root resorption **(Bender *et al*., 1997)**.

1.6.1 Teeth without periapical lesion

Teeth may need endodontic treatment because of pulpitis or pulp necrosis. Proper endodontic treatment with well cleaning, shaping, and three-dimensional obturation was the first object before orthodontic movement. After well obturation, 1 month of follow-up is necessary for the exudate and the inflammatory cells to be absorbed and removed. After that, the orthodontic force can be applied and treatment can be commenced. If tooth unfortunately requires root canal treatment during orthodontic movement, it is recommended to clean and shape the root canals thoroughly followed by calcium hydroxide dressing until the end of orthodontic treatment. This protocol reduces the risk of root resorption during tooth movement **(Malmgren and Malmgren , 2007)**.

Moreover, the cavity should be sealed properly with resin or glass ionomer to prevent bacterial leakage. The canals can be obturation with GP and sealer when orthodontic tooth movement has done **(Hamilton and Gutmann, 1999)**.

1.6.2 Teeth with inflammatory periapical lesion

The periapical lesion or disease is associated with the microbial flora present in the canals in which the dental pulp is necrotic due to caries or dental trauma. Endodontic treatment on tooth with acute inflammatory periapical disease usually has good prognosis because there is minimal area of apical root resorption and less microbial flora around the apex. It is easier to eliminate the microbiota and to make the lesion healed. The microbial flora persists longer within the chronic inflammatory periapical diseases, such as chronic apical periodontitis or periapical granuloma etc. This is because the bacteria are allowed to form biofilms and colonize within the dentinal tubules, isthmus, lateral canals and the external part of the apical surface. These areas are not easy to reach while mechanical instrumentation. Complete elimination of the microbial components in these cases sometimes may be difficult, and thus, healing of chronic periapical lesion cannot be assured. Teeth with previous chronic periapical lesions but being well treated can have orthodontic treatment with no problem on repairing. Fifteen to thirty days of follow- up after endodontic treatment can allow the exudate and inflammatory infiltrate to be absorbed from the lesion. Orthodontic tooth movement can be started few days after that. The main reason for the failure of healing is probably due to the limitation of endodontic treatment rather than tooth movement itself **(consolaro, 2013)**.

1.6.3 Aseptic pulp necrosis and dental trauma

The aseptic pulp necrosis usually occurs on previous- traumatized teeth. It is usually unnoticed until sign or symptom was reported from routine radiographic check- up or when tooth discoloration happened. The microbiota on the necrotic pulp presents less aggressiveness and the metabolic activity is lower **(malmgren, 2007**).

Previous-traumatized teeth can have successful orthodontic movement if endodontic treatment can be done properly before orthodontic treatment. The more severe the dental trauma is, the poorer the prognosis could be during the treatment.Therefore, the magnitude of orthodontic force to the traumatized teeth should be reduced and routine follow-up of this tooth is necessary. In addition, the chance of extreme root resorption may largely increase on the traumatized teeth after orthodontic treatment **(consolaro, 2013).**

Chapter two

Discussion

2.1 Discussion

Some studies have reported significant pulpal reactions to orthodontic tooth movement, yet there is no conclusive evidence on the relation between orthodontic forces and pulpal alterations **(Proffit *et al*., 2007)**.

Some studies have demonstrated that most of the pulpal changes are associated with intrusive forces compared to other orthodontic movements **(Villa *et al*., 2005)**.

Ramazanzadeh *et al* study, pulpal reactions to orthodontic forces were investigated 7 days and 1 month after force application to study both the immediate and the late pulpal responses. Some pulpal reactions to intrusive forces have been reported to occur as early as 3 days after force application **(Ramazanzadeh *et al*., 2009)**.

Lazzaretti *et al* study, mild inflammation was observed in adolescents only after 1 month of force application. In contrast, cases with moderate and severe inflammation were found among the adult patients after 7 days. reported no inflammatory cell reactions 3 weeks after intrusion **(Lazzaretti *et al*., 2014)**.

The study group included 12–19-year-old adolescents. On the other hand, we found a significant difference in the amount of chronic inflammation between the adolescents and adults. This emphasizes the importance of applying lighter forces with suitable intervals in the adult patients. Some studies have demonstrated that hemodynamic changes are the first observable signs after orthodontic movements **(Yamaguchi *et al*., 2007)**.

However, there is a large controversy in this issue. The previous researches did not find a significant difference in vascular dilation between adolescents and adults after 7 days and 1 month of intrusion. In addition, no significant difference was observed between the control and intrusive groups. This can be due to the light force application in the study. These results are in line with the **Ramazanzadeh *et al*** study.

Chapter three

Conclusions and Suggestions

3.1 Conclusions

There is insufficient scientific evidence regarding the association between orthodontic forces and human dental pulp. However, a history of dental trauma maybe considered a risk factor for loss of pulp vitality during orthodontic treatment.

3.2 Suggestions for further studies

1. Study the effect of orthodontic force on periodontal tissue metabolism.
2. Study the effect of orthodontic force on salivary levels of alkaline phosphatase enzyme.
3. Study the effect of different types of forces on possible root resorption.

References

(A)

Abbassy, M. A., Sabban, H. M., Hassan, A. H., and Zawawi, K. H. (2015). Evaluation of mini-implant sites in the posterior maxilla using traditional radiographs and cone-beam computed tomography. Saudi medical journal, 36(11), pp. 1336.

Abtahi, M., Eslami, N., Abadi, R. Z. M., and Rezaei, S. P. (2016). The effect of intrusive orthodontic force on dental pulp of adults versus adolescents. Dental Research Journal, 13(4), pp. 367.

Alves Jr, M., Baratieri, C., Mattos, C. T., Araújo, M. T. D. S., and Maia, L. C. (2013). Root repair after contact with mini-implants: systematic review of the literature. The European Journal of Orthodontics, 35(4), pp. 491-499.

Anastasi, G., Cordasco, G., Matarese, G., Nucera, R., Rizzo, G., Mazza, M., Militi, A., Portelli, M., Cutroneo, G., and Favaloro, A. (2008). An immunohistochemical, histological, and electron-microscopic study of the human periodontal ligament during orthodontic treatment. International Journal of Molecular Medicine, 21(4), pp. 545-554.

Andreasen, J.O. and Andreasen, L. (2007). Textbook and Atlas of Traumatic Injuries to the Teeth. 4th ed. Oxford: Blackwell Munksgaard, pp. 848-50.

(B)

Bauss, O., Röhling, J., Rahman, A., and Kiliaridis, S. (2008). The effect of pulp obliteration on pulpal vitality of orthodontically intruded traumatized teeth. Journal of endodontics, 34(4), pp. 417-420.

Bender, I. B., and Seltzer, S. (2002). Seltzer and Bender's Dental Pulp. Quintessence Publishing (IL).

Bender, I. B., Byers, M. R., and Mori, K. (1997). Periapical replacement resorption of permanent, vital, endodontically treated incisors after orthodontic movement: report of two cases. Journal of Endodontics, 23(12), pp. 768-773.

Bicakci, A. A., Kocoglu-Altan, B., Celik-Ozenci, C., Tekcan, M., 10-Babacan, H., and Gungör, E. (2010). Histopathologic evaluation of pulpal tissue response to various adhesive cleanup techniques. American journal of orthodontics and dentofacial orthopedics, 138(1), pp. 12-e1.

Brannstrom, M. (1972). The hydrodynamics of the dentine. Its possible relationship to dentinal pain. Int. dent. J, 22, 219-227.

(C)

Consolaro, A., and Consolaro, R. B. (2013). Orthodontic movement of endodontically treated teeth. Dental Press Journal of Orthodontics, 18, pp. 2-7.

Cutroneo, G., Centofanti, A., Speciale, F., Rizzo, G., Favaloro, A., Santoro, G., and Trimarchi, F. (2015). Sarcoglycan complex in masseter and sternocleidomastoid muscles of baboons: an immunohistochemical study. European Journal of Histochemistry, 59(2).

(D)

De Ponte, F. S., Favaloro, A., Siniscalchi, E. N., Centofanti, A., Runci, M., Cutroneo, G., and Catalfamo, L. (2013). Sarcoglycans and integrins in bisphosphonate treatment: Immunohistochemical and scanning electron microscopy study. Oncology Reports, 30(6), pp. 2639-2646.

Derringer, K., and Linden, R. (2007). Epidermal growth factor released in human dental pulp following orthodontic force. The European Journal of Orthodontics, 29(1), pp.67-71.

Di Domenico, M., D'apuzzo, F. , Feola, A., Cito, L., Monsurrò, A., Pierantoni, G. M., and Perillo, L. (2012). Cytokines and VEGF induction in orthodontic movement in animal models. Journal of Biomedicine and Biotechnology, 2012.

(E)

Ersahan, S. and Sabuncuoglu, F.A. (2015). Effects of magnitude of intrusive force on pulpal blood flow in maxillary molars. American Journal of Orthodontics and Dentofacial Orthopedics, 148, pp. 83-89.

(F)

Fitzgerald, M., Chiego Jr, D. J., and Heys, D. R. (1990). Autoradiographic analysis of odontoblast replacement following pulp exposure in primate teeth. Archives of oral biology, 35(9), pp. 707-715.

(G)

Goulet, G. C., Cooper, D. M. L., Coombe, D., and Zernicke, R. F. (2008). Influence of cortical canal architecture on lacunocanalicular pore pressure and fluid flow. Computer Methods in Biomechanics and Biomedical Engineering, 11(4), pp. 379-387.

Grünheid, T., Morbach, B. A., and Zentner, A. (2007). Pulpal cellular reactions to experimental tooth movement in rats. Oral Surgery, Oral Medicine, Oral Pathology, Oral Radiology, and Endodontology, 104(3), pp. 434-441.

(H)

Hall, C. J., and Freer, T. J. (1998). The effects of early orthodontic force application on pulp test responses. Australian Dental Journal, 43(5), pp. 359-361.

Hamilton, R. S., and Gutmann, J. L. (1999). Endodontic-orthodontic relationships: a review of integrated treatment planning challenges. International endodontic journal, 32(5), pp. 343-360.

Hohmann, A., Wolfram, U., Geiger, M., Boryor, A., Sander, C., Faltin, R., and Sander, F. G. (2007). Periodontal ligament hydrostatic pressure with areas of root resorption after application of a continuous torque moment: a study using identical extracted maxillary human premolars. The Angle Orthodontist, 77(4), pp. 653-659.

(I)

Ikeda, H., and Suda, H. (2006). 'Rapid Penetration of Lucifer Yellow into Vital Teeth and Dye Coupling Between Odontoblasts and Neighbouring Pulp Cells in the Cat', Archives of Oral Biology, 51(2), pp. 123-128.

Iyyer, B. S., Bhalajhi, S. I., & Bhalajhi, S. I. (2012). Orthodontics: the art and science. Arya (Medi) Publ..

(J)

Javed, F., Al-Kheraif, A. A., Romanos, E. B., and Romanos, G. E. (2015). Influence of orthodontic forces on human dental pulp: a systematic review. Archives of oral biology, 60(2), pp. 347-356.

(K)

Kayhan, F., Küçükkeleş, N., and Demirel, D. (2000). A histologic and histomorphometric evaluation of pulpal reactions following rapid palatal expansion. American Journal of Orthodontics and Dentofacial Orthopedics, 117(4), pp. 465-473.

Kim, T., Suh, J., Kim, N., and Lee, M. (2010). Optimum conditions for parallel translation of maxillary anterior teeth under retraction force determined with the finite element method. American Journal of Orthodontics and Dentofacial Orthopedics, 137(5), pp. 639-647.

Kojima, T., Yamaguchi, M., and Kasai, K. (2006). Substance P stimulates release of RANKL via COX-2 expression in human dental pulp cells. Inflammation Research, 55, pp. 78-84.

Krishnan, V., and Davidovitch, Z. E. (2006). Cellular, molecular, and tissue-level reactions to orthodontic force. American Journal of Orthodontics and Dentofacial Orthopedics, 129(4), pp. 469-e1.

Krishnan, V., Park, Y., and Davidovitch, Z. (2009). Biology of orthodontic tooth movement: An overview. In V. Krishnan and Z. Davidovitch (Eds.), Biological mechanisms of tooth movement (pp. 19-43). Chichester, UK: Wiley-Blackwell.

(L)

Lazzaretti, D. N., Bortoluzzi, G. S., Fernandes, L. F. T., Rodriguez, R., Grehs, R. A., and Hartmann, M. S. M. (2014). Histologic evaluation of human pulp tissue after orthodontic intrusion. Journal of Endodontics, 40(10), pp. 1537-1540.

Leavitt, A. H., King, G. J., Ramsay, D. S., and Jackson, D. L. (2002). A longitudinal evaluation of pulpal pain during orthodontic tooth movement. Orthodontics & craniofacial research, 5(1), pp. 29-37.

Lee, S. K., Min, K. S., Jeong, G. S., Lee, S. H., Lee, H. J., Lee, S. I., and Kim, E. C. (2008). Mechanical stress activates proinflammatory cytokines and antioxidant defense enzymes in human dental pulp cells. Journal of endodontics, 34(11), pp. 1364-1369.

Lesot, Herve, Smith, Anthony J., Tziafas, Dimitrios, Begue-Kirn, Catherine, Cassidy, Nigel, and Ruch, Jacques V. (1994). 'Biologically Active Molecules and Dental Tissue Repair: A Comparative Review of Reactionary and Reparative Dentinogenesis with Induction of Odontoblast Differentiation In Vitro', Cells and Materials, 4, pp. 199-218.

Liao, Z., Chen, J., Li, W., Darendeliler, M. A., Swain, M., and Li, Q. (2016). Biomechanical investigation into the role of the periodontal ligament in optimising orthodontic force: a finite element case study. Archives of Oral Biology, 66, pp. 98-107.

Lombardo, L., Stefanoni, F., Mollica, F., Laura, A., Scuzzo, G., and Siciliani, G. (2012). Three-dimensional finite-element analysis of a central lower incisor under labial and lingual loads. Progress in Orthodontics, 13(2), pp. 154-163.

(M)

Malmgren, O., and Malmgren, B. (2007). Orthodontic management of the traumatized teeth. Textbook and color atlas of traumatic injuries to the teeth. 4th ed. Oxford: Blackwell Munksgaard, pp. 699-715.

Mascarenhas, R., Chatra, L., Shenoy, S., Husain, A., Mathew, J. M., and Parveen, S. (2015). A comparative study of forces in labial and lingual orthodontics using finite element method. Journal of Indian Orthodontic Society, 49(1), pp. 15-18.

Melsen, B. (2001). Tissue reaction to orthodontic tooth movement—a new paradigm. The european journal of orthodontics, 23(6), pp. 671-681.

Militi, A., Cutroneo, G., Favaloro, A., Matarese, G., Di Mauro, D., Lauritano, F., and Rizzo, G. (2019). An immunofluorescence study on VEGF and extracellular matrix proteins in human periodontal ligament during tooth movement. Heliyon, 5(10), pp. e02572.

Muraglie, S., Musumeci, G., Loreto, C., and Leonardi, R. M. (2019). Role of ADAMTS4 and ADAMTS5 during early orthodontic tooth movement. Journal of Biological Regulators and Homeostatic Agents, 33(2), pp. 649-655.

(N)

Nixon, C. E., Saviano, J. A., King, G. J., and Keeling, S. D. (1993). Histomorphometric study of dental pulp during orthodontic tooth movement. Journal of Endodontics, 19(1), pp. 13-16.

(P)

Phulari, B. S. (2011). Orthodontics principles and practice. New Delhi: Jaypee Brothers Medical Publishers (P) Ltd.

Proffit, W. R., Fields Jr, H. W., and Sarver, D. M. (2013). Contemporary Orthodontics, 5th ed. Mosby: St. Louis, p. 300.

Proffit, W.R., Fields, H.W., and Sarver, D.M. (2007). Contemporary Orthodontics. 4th ed. St. Louis: Mosby Co., pp. 94pp. 331-48.

(R)

Ramazanzadeh, B. A., Sahhafian, A. A., Mohtasham, N., Hassanzadeh, N., Jahanbin, A., and Shakeri, M. T. (2009). Histological changes in human dental pulp following application of intrusive and extrusive orthodontic forces. Journal of oral science, 51(1), pp. 109-115.

(S)

Sandy, J. R., Farndale, R. W., and Meikle, M. C. (1993). Recent advances in understanding mechanically induced bone remodeling and their relevance to orthodontic theory and practice. American Journal of Orthodontics and Dentofacial Orthopedics, 103(3), pp. 212-222.

Sano, Y., Ikawa, M., Sugawara, J., Horiuchi, H., and Mitani, H. (2002). The effect of continuous intrusive force on human pulpal blood flow. The European Journal Of Orthodontics, 24(2), pp. 159-166.

Shi, S. and Gronthos, S. (2003). Perivascular niche of postnatal mesenchymal stem cells in human bone marrow and dental pulp. Journal of Bone and Mineral Research, 18(4), pp. 696-704.

Shigehara, S., Matsuzaka, K., and Inoue, T. (2006). Morphohistological change and expression of HSP70, osteopontin and osteocalcin mRNAs in rat dental pulp cells with orthodontic tooth movement. The Bulletin of Tokyo Dental College, 47(3), pp. 117-124.

Smith, A.J., Cassidy, N., Perry, H., Bègue-Kirn, C., Ruch, J.V., and Lesot, H. (1995). "Reactionary dentinogenesis." International Journal of Developmental Biology, 39(1), pp. 273-280.

Spoto, G., Fioroni, M., Rubini, C., Tripodi, D., Perinetti, G., and Piattelli, A. (2001). Aspartate aminotransferase activity in human healthy and inflamed dental pulps. Journal of Endodontics, 27(6), pp. 394-395.

Sübay, R. K., Kaya, H., Tarım, B., Sübay, A., and Cox, C. F. (2001). Response of human pulpal tissue to orthodontic extrusive applications. Journal of Endodontics, 27(8), pp. 508-511.

(T)

Tripuwabhrut, P., Brudvik, P., Fristad, I., and Rethnam, S. (2010). Experimental orthodontic tooth movement and extensive root resorption: periodontal and pulpal changes. European Journal of Oral Sciences, 118(6), pp. 596-603.

(V)

Villa, P. A., Oberti, G., Moncada, C. A., Vasseur, O., Jaramillo, A., Tobón, D., and Agudelo, J. A. (2005). Pulp-dentine complex changes and root resorption during intrusive orthodontic tooth movement in patients prescribed nabumetone. Journal of endodontics, 31(1), pp. 61-66.

von Böhl, M., and Kuijpers-Jagtman, A. M. (2009). Hyalinization during orthodontic tooth movement: a systematic review on tissue reactions. The European Journal of Orthodontics, 31(1), pp. 30-36.

von Böhl, M., Ren, Y., Fudalej, P. S., and Kuijpers-Jagtman, A. M. (2012). Pulpal reactions to orthodontic force application in humans: a systematic review. Journal of Endodontics, 38(11), pp. 1463-1469.

(W)

Weinbaum, S., Cowin, S. C., and Zeng, Y. (1994). A model for the excitation of osteocytes by mechanical loading-induced bone fluid shear stresses. Journal of biomechanics, 27(3), pp. 339-360.

(Y)

Yamaguchi, M., Kojima, T., Kanekawa, M., Aihara, N., Nogimura, A., and Kasai, K. (2004). Neuropeptides stimulate production of interleukin-1β, interleukin-6, and tumor necrosis factor-α in human dental pulp cells. Inflammation Research, 53, pp. 199-204.

Yamaguchi, M., and Kasai, K. (2007, December). The effects of orthodontic mechanics on the dental pulp. In Seminars in orthodontics (Vol. 13, No. 4, pp. 272-280). WB Saunders.

Yoshida, S. and Ohshima, H. (1996). Distribution and organization of peripheral capillaries in dental pulp and their relationship to odontoblasts. The Anatomical Record, 245(2), pp. 313-326.

Yu, C. and Abbott, P.V. (2007). An overview of the dental pulp: its functions and responses to injury. Australian Dental Journal, 52(Suppl 1), pp. S4-S16.